

Catalog of the Human BRACCIA data

Martin Vejmelka, Kristina Susmakova

September 17, 2008

Abstract

This document contains information about the measurements on humans taken during the BRACCIA project.

Contents

1 Measurement protocol

This section contains the measurement protocol.

2 Patient lists

Lists of patients in particular groups here.

3 Patient information

3.1 L010507

Comments

Sevoflurane with curare was administered. Overall reasonable quality measurement. EEG has very low amplitude waveform in awake state. Awake state also contains some artefacts.

Awake EEG Indistinct alpha, seen in spectrum. Might be some delta in awake state but probably not.

Awake ECG Some startup trouble, signal mostly clean, point failures.

Awake Respiration Varying amplitude, rather clean.

Asleep EEG Very clean EEG, distinct alpha. High power in low frequencies.

Asleep ECG Some point faults, overall OK.

Asleep Respiration Signal lost around 1000s and 1400s (at end).

Plots

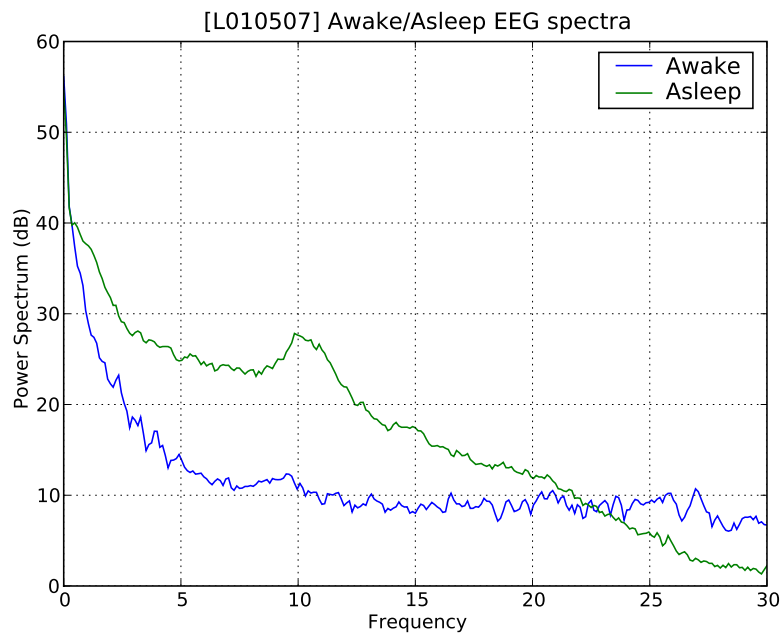


Figure 1: EEG Spectrum of patient L010507

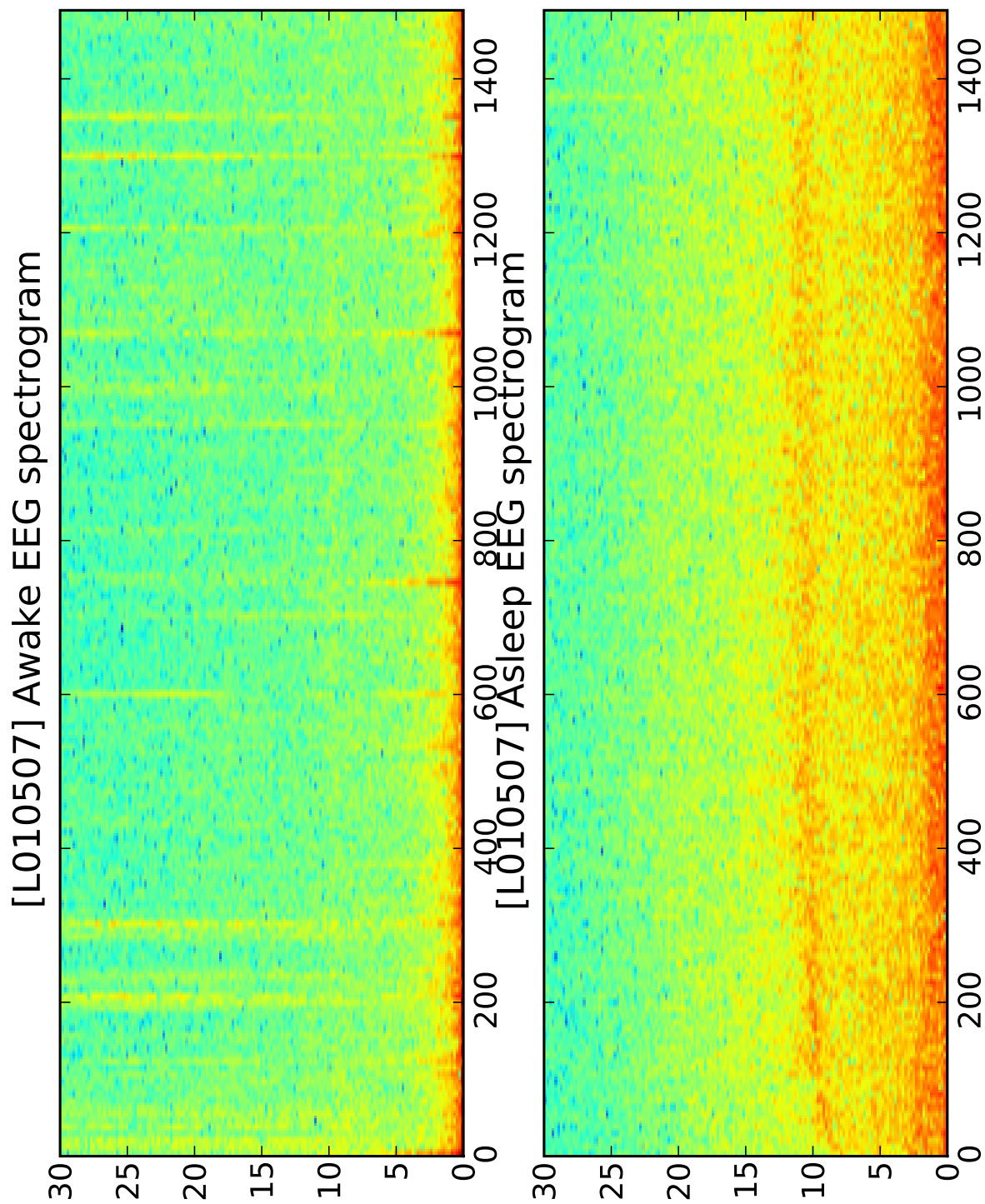


Figure 2: EEG Spectrogram of patient L010507

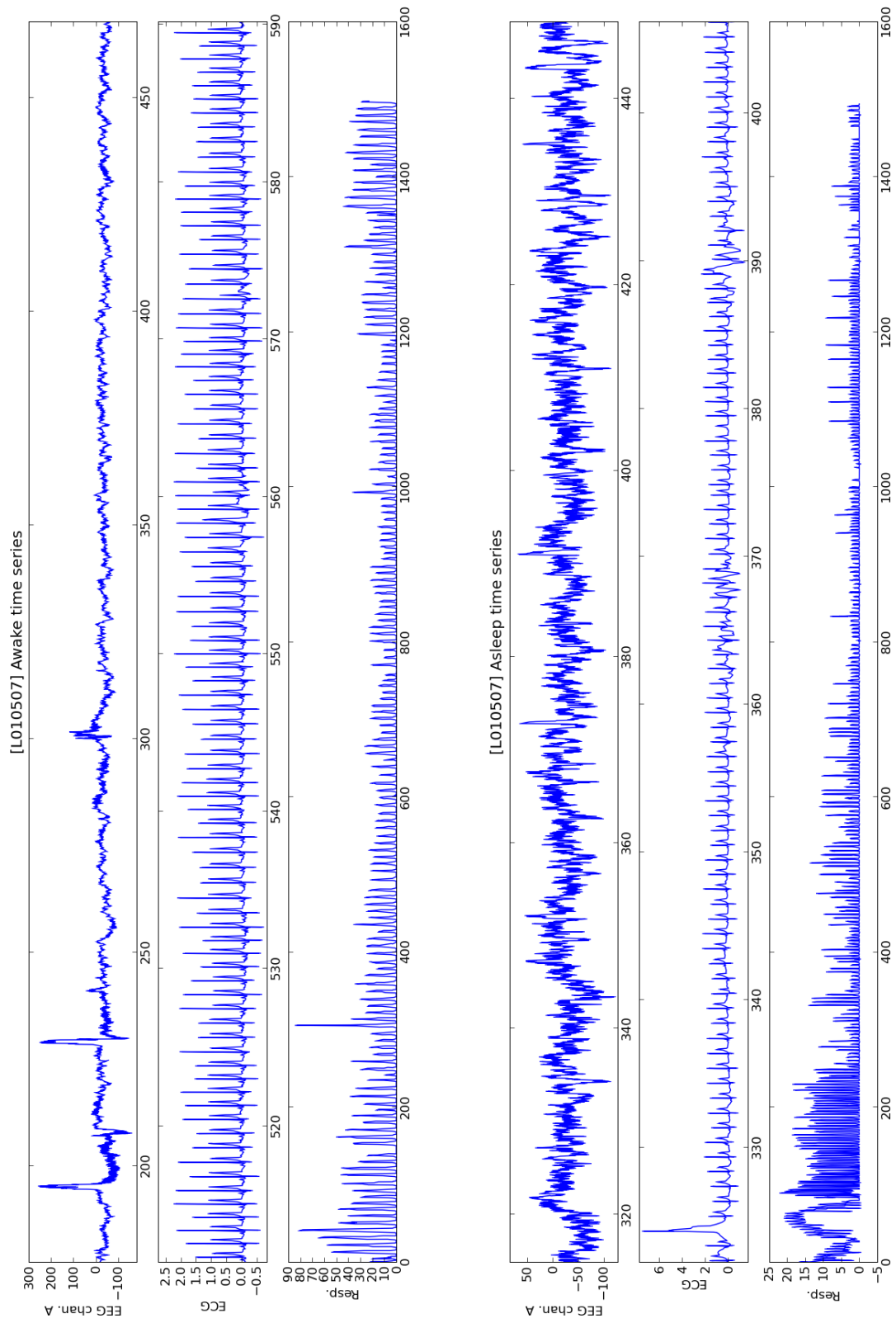


Figure 3: Time series samples of patient L010507

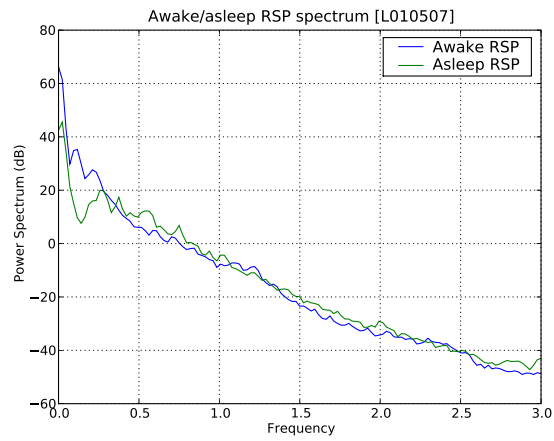
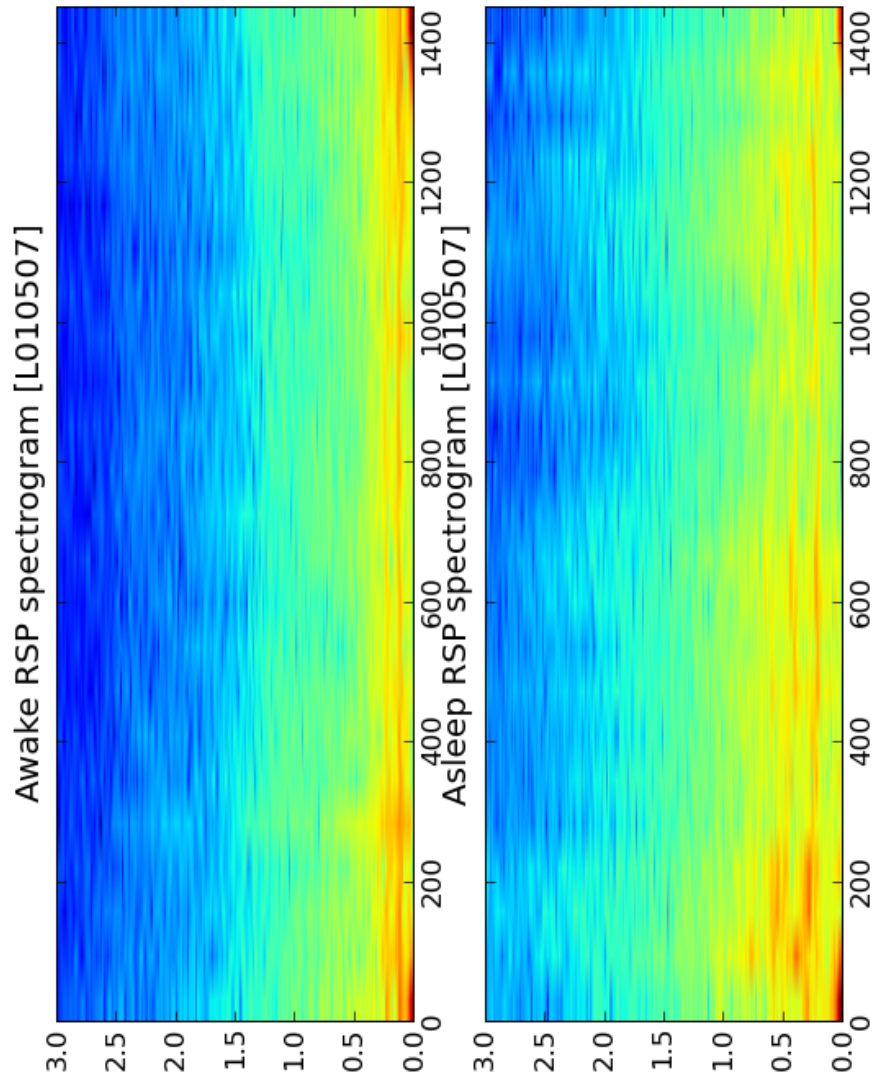


Figure 4: Time series samples of patient L010507

3.2 L030407

Comments

Propofol was administered. Good quality measurements with point faults only.

Awake EEG Low amplitude EEG with larger amplitude artefacts. Origin not determined. Spectrum has no significant peaks.

Awake ECG Minor fluctuations, good quality signal.

Awake Respiration Respiration is of good quality. Some amplitude and frequency fluctuations.

Asleep EEG Very strong alpha (11Hz) wide peak.

Asleep ECG Good quality.

Asleep Respiration Good quality, some point faults with large amplitude.

Plots

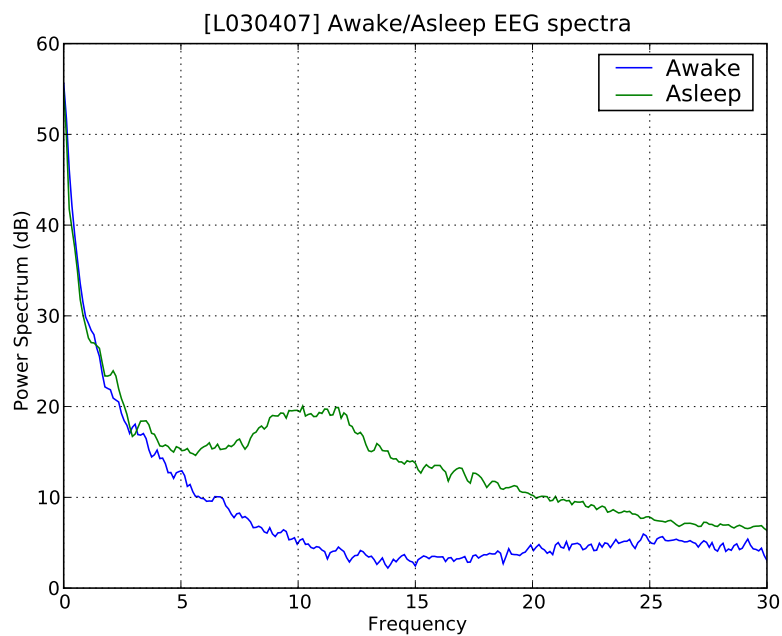


Figure 5: EEG Spectrum of patient L030407

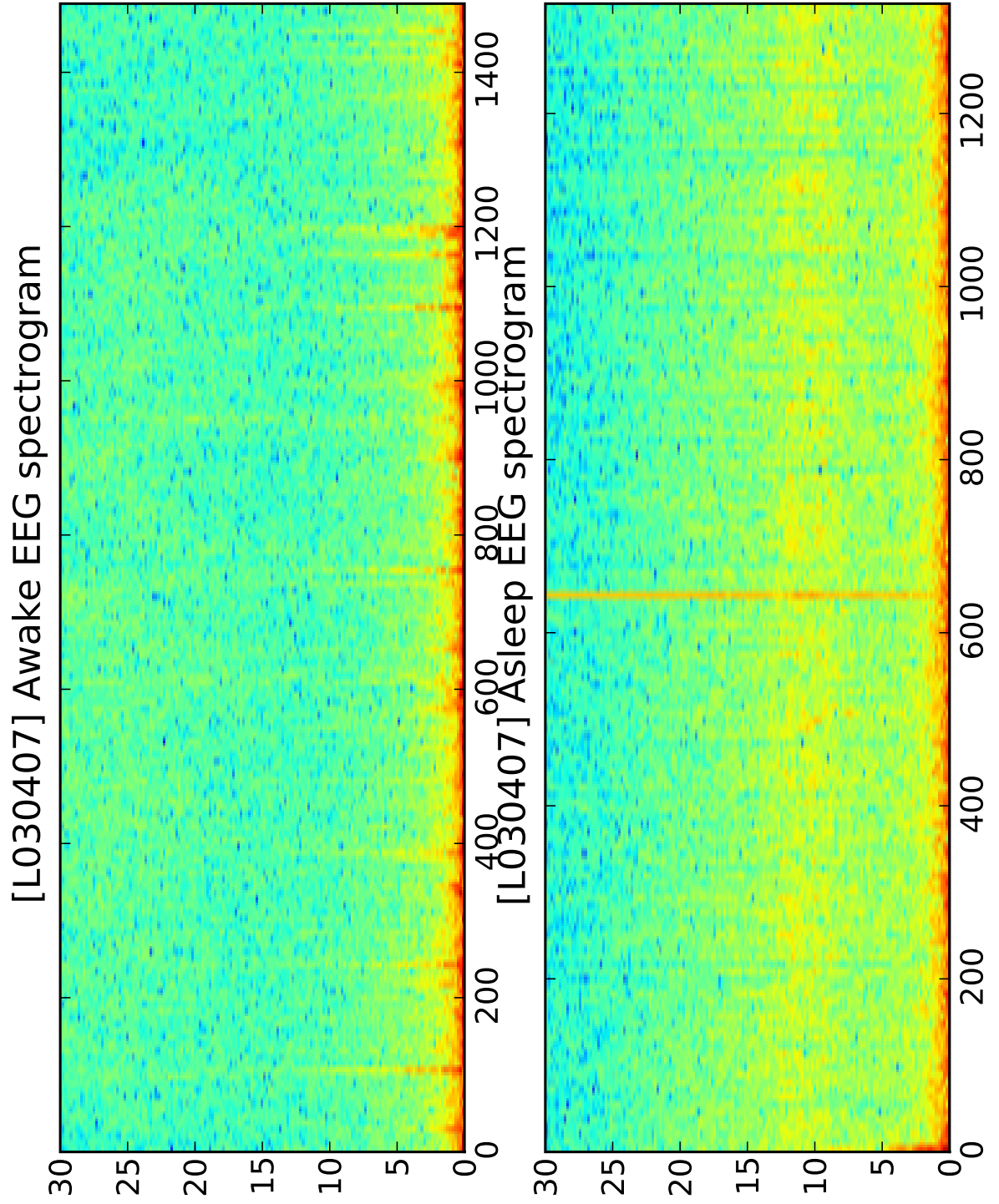


Figure 6: EEG Spectrogram of patient L030407

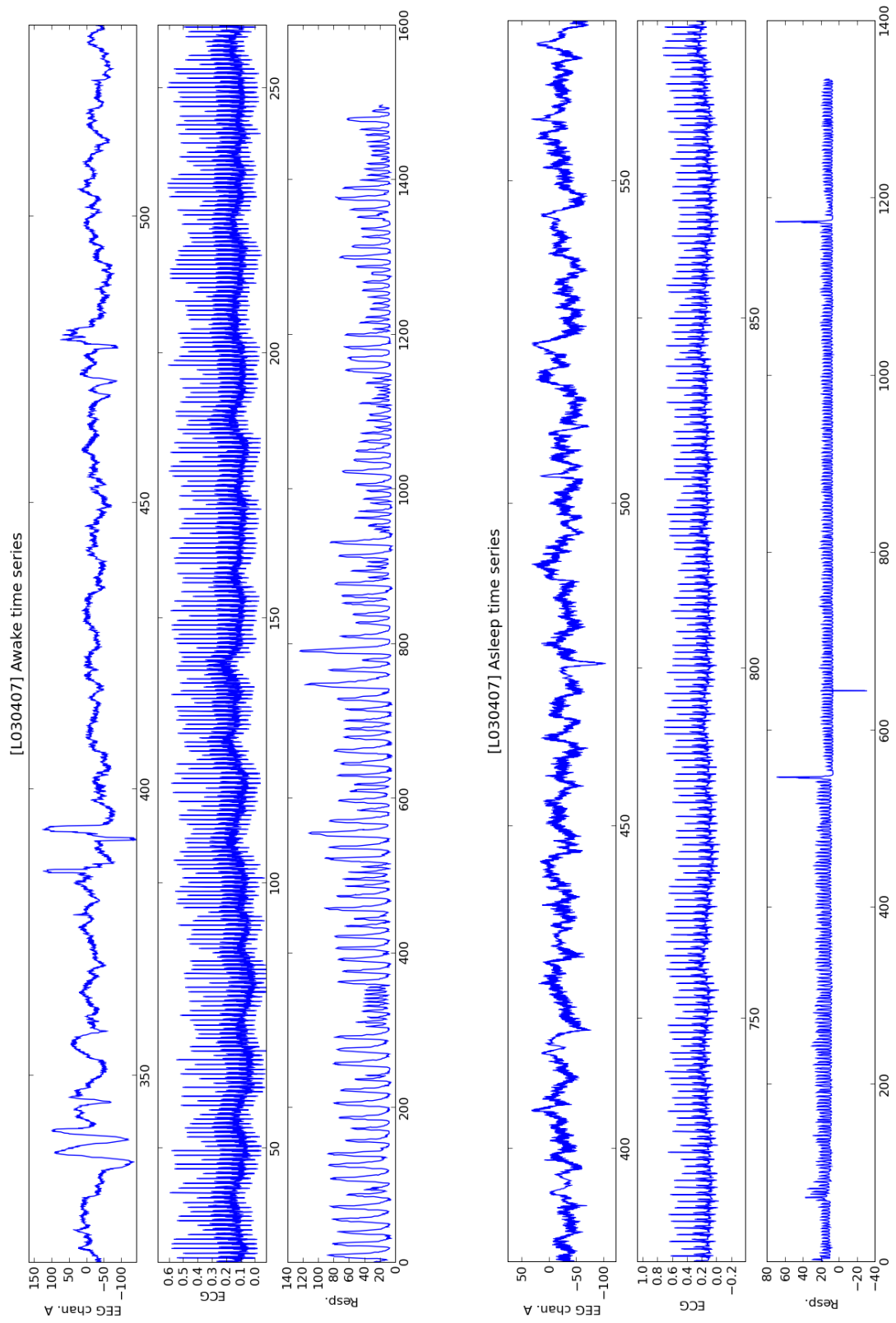


Figure 7: Time series samples of patient L030407

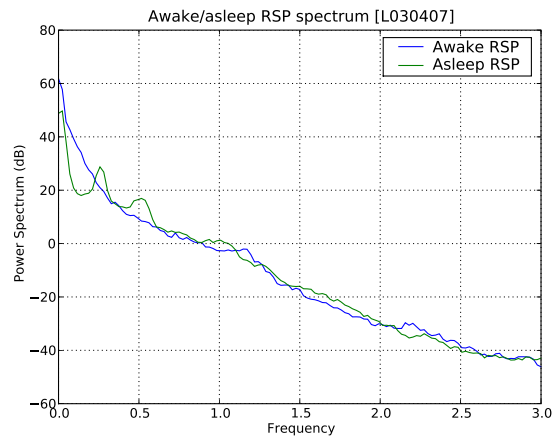
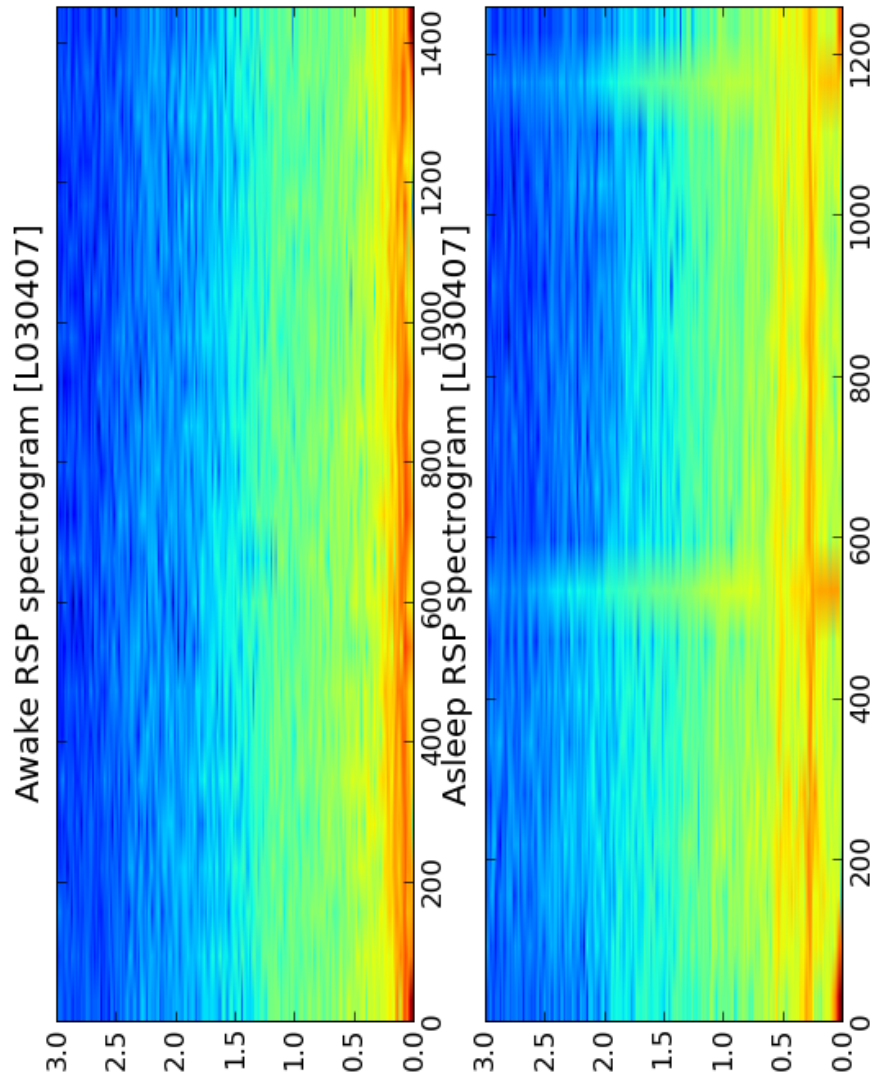


Figure 8: Time series samples of patient L030407

3.3 L040708

Comments

Sevoflurane was administered. Good measurement except for awake RSP which is degraded.

Awake EEG No large amplitudes, strong activity in 13-20Hz range, diffuse.

Awake ECG There are 3 baseline fluctuations, signal of good quality

Awake Respiration Strong amplitude variation, some signal faults (420s, 1000s, 1200s). Signal of passable quality.

Asleep EEG EEG with well-defined sharp alpha peak (9Hz). Some delta activity at 4Hz.

Asleep ECG Very clean ECG.

Asleep Respiration Clean RSP.

Plots

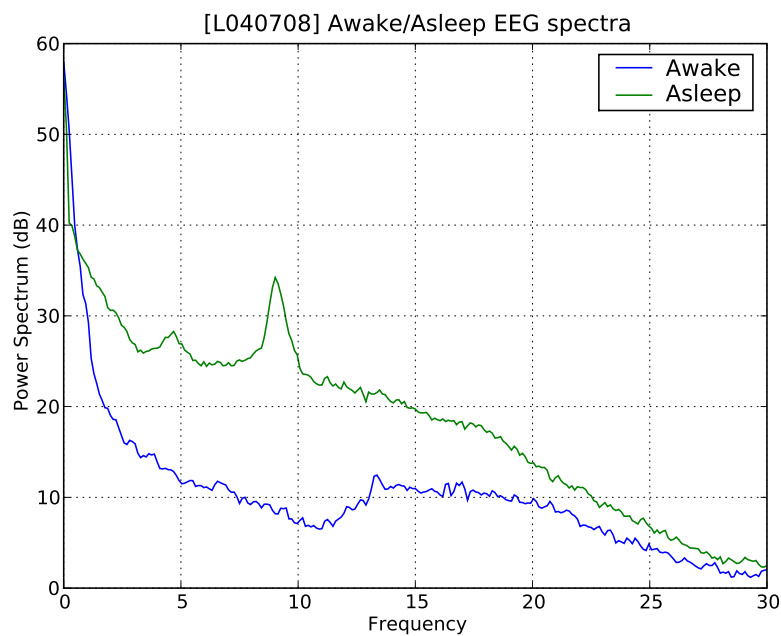


Figure 9: EEG Spectrum of patient L040708

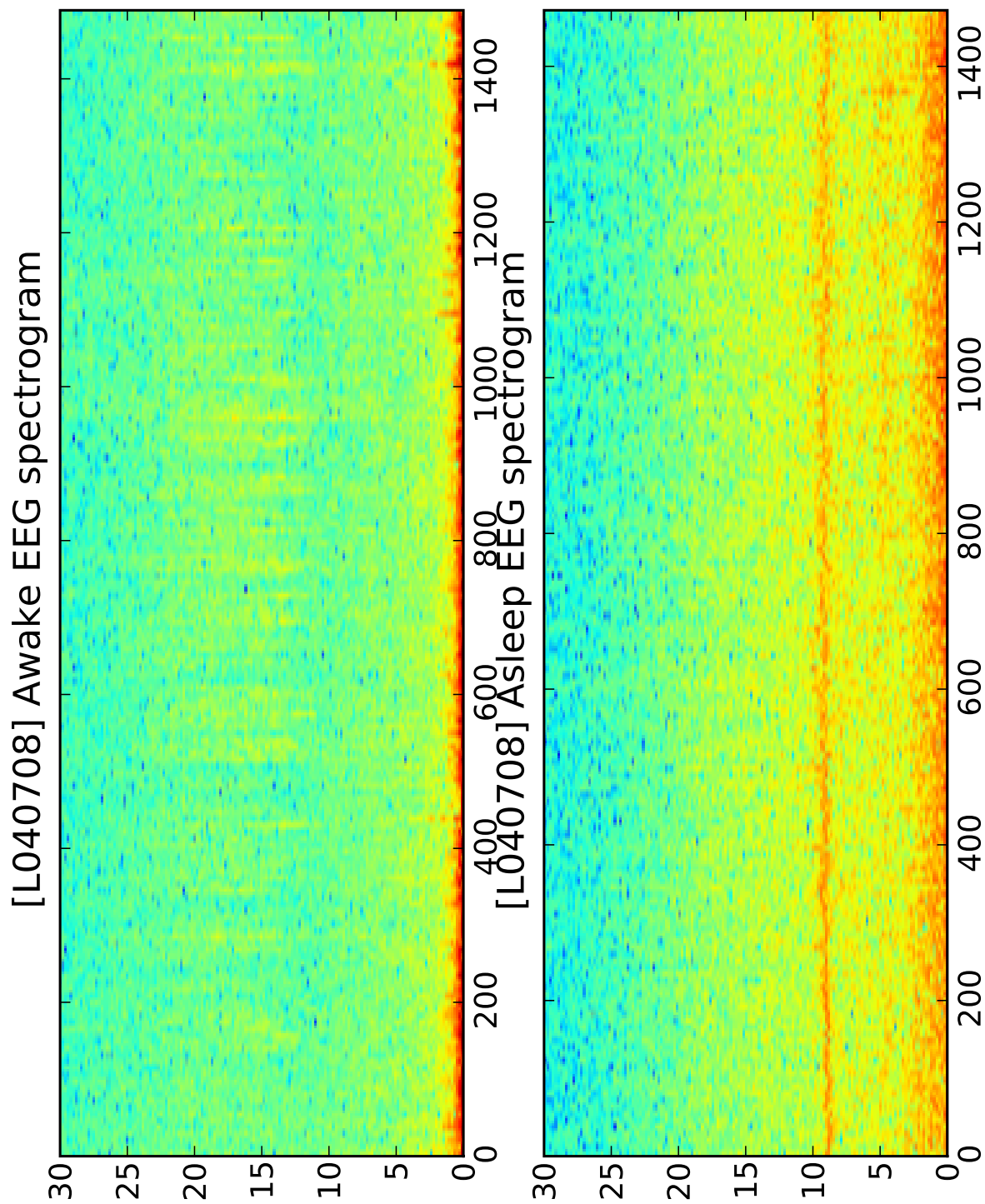


Figure 10: EEG Spectrogram of patient L040708

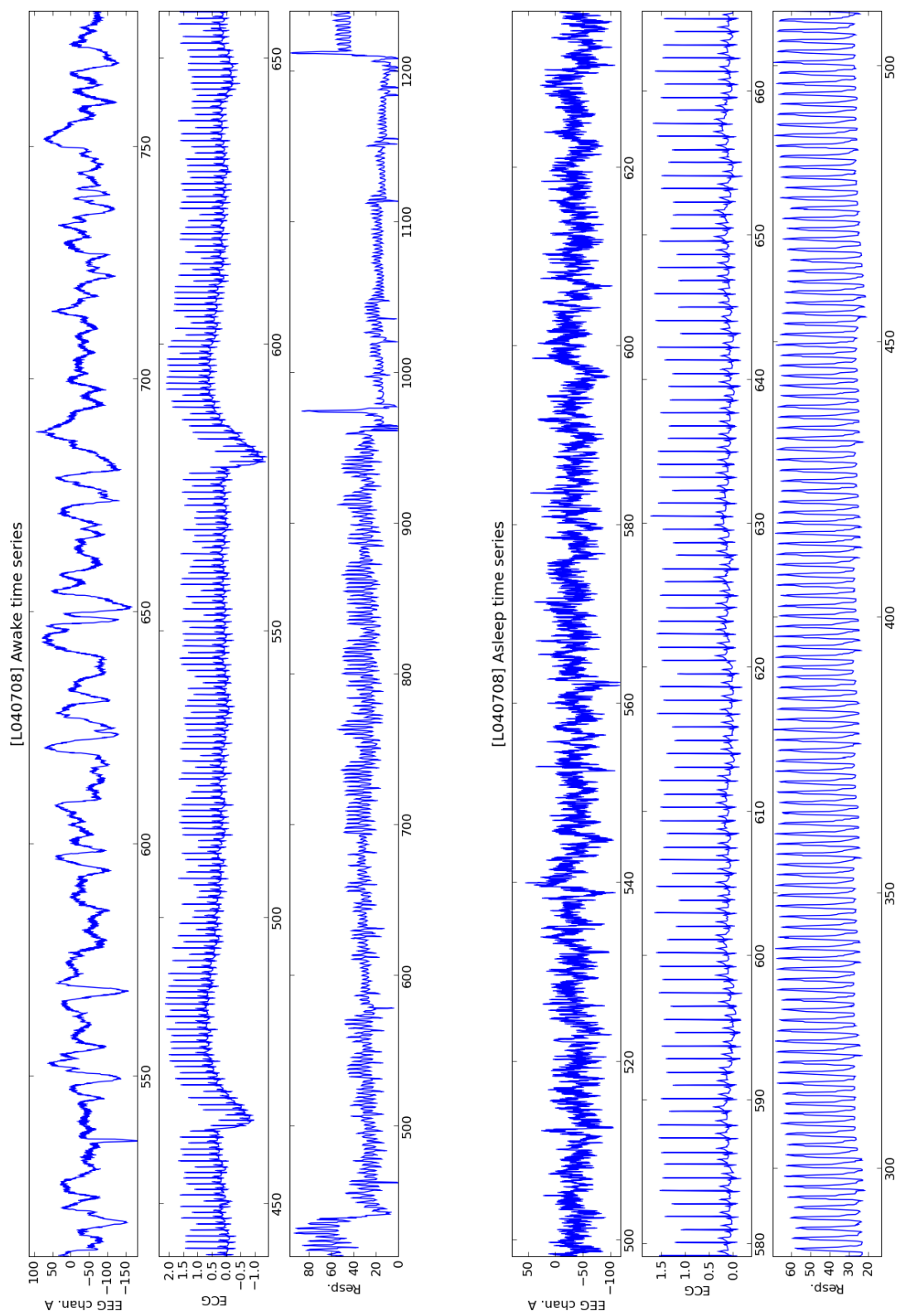


Figure 11: Time series samples of patient L040708

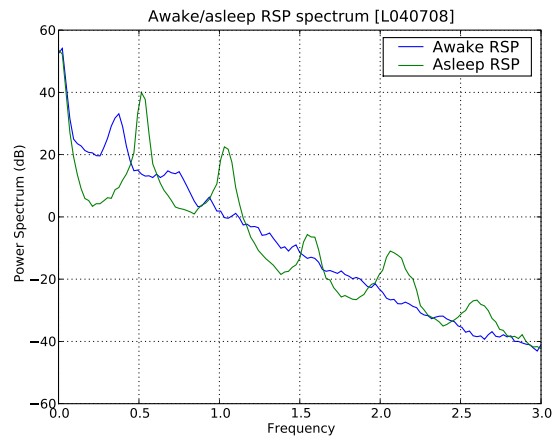
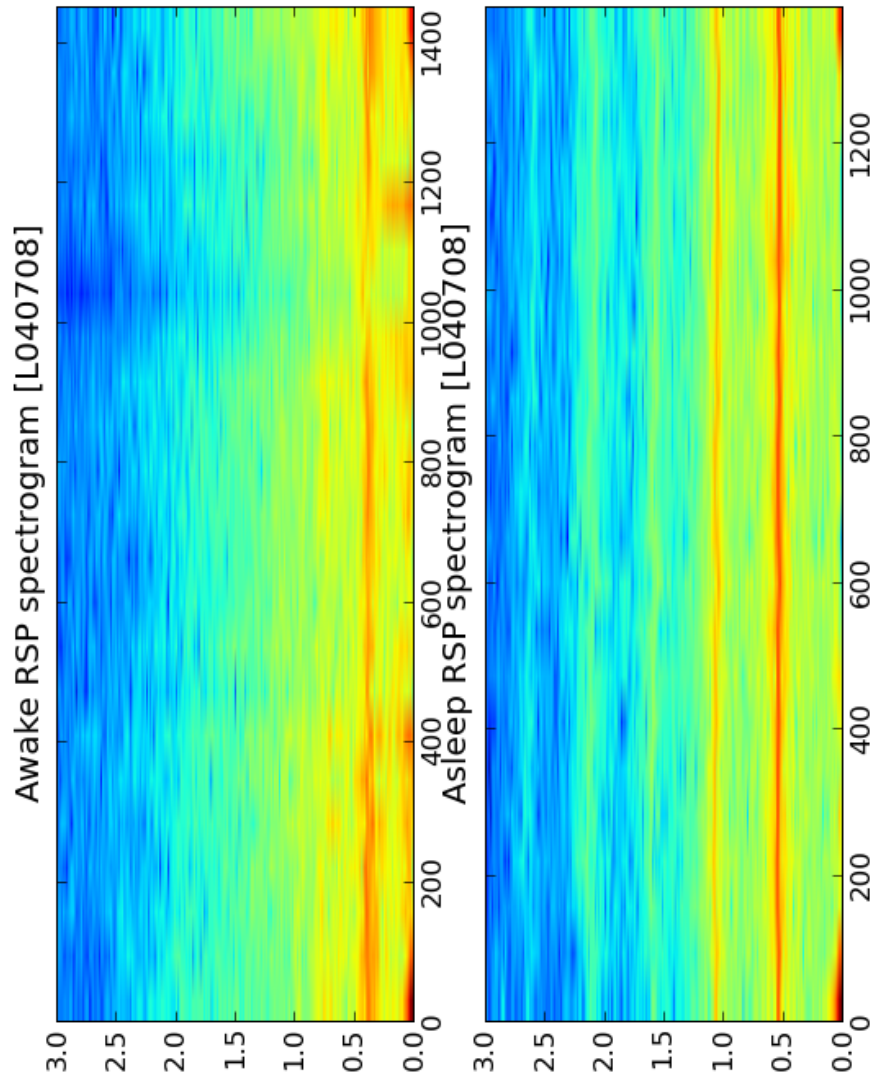


Figure 12: Time series samples of patient L040708

3.4 L050208

Comments

Propofol with curare was administered. This patient looks like having oscillations in asleep state, but there are no peaks in the spectrogram in the lower delta range. Use for oscillation testing ? Case study possibility.

Awake EEG Low amplitude waves with some large amplitude artefacts (?). No significant peaks.

Awake ECG One baseline faults (830s). Otherwise very clean signal. Bipolar R wave.

Awake Respiration Bad quality RSP signal. Mainly useable between 170s and 800s.

Asleep EEG Diffuse alpha peak of low power, 10Hz. Time series seems to show low frequency oscillations but no significant peak is visible in the spectrum or spectrogram.

Asleep ECG Excellent. Bipolar R wave.

Asleep Respiration Excellent.

Plots

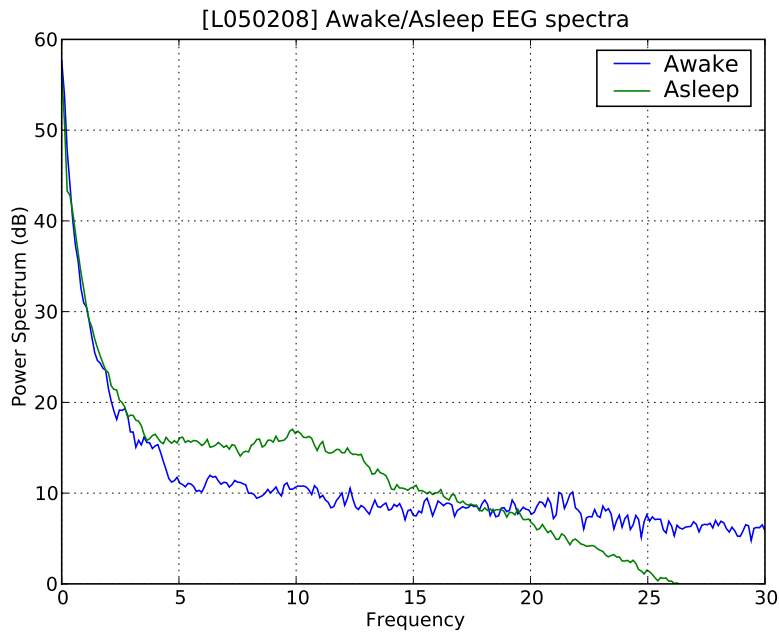


Figure 13: EEG Spectrum of patient L050208

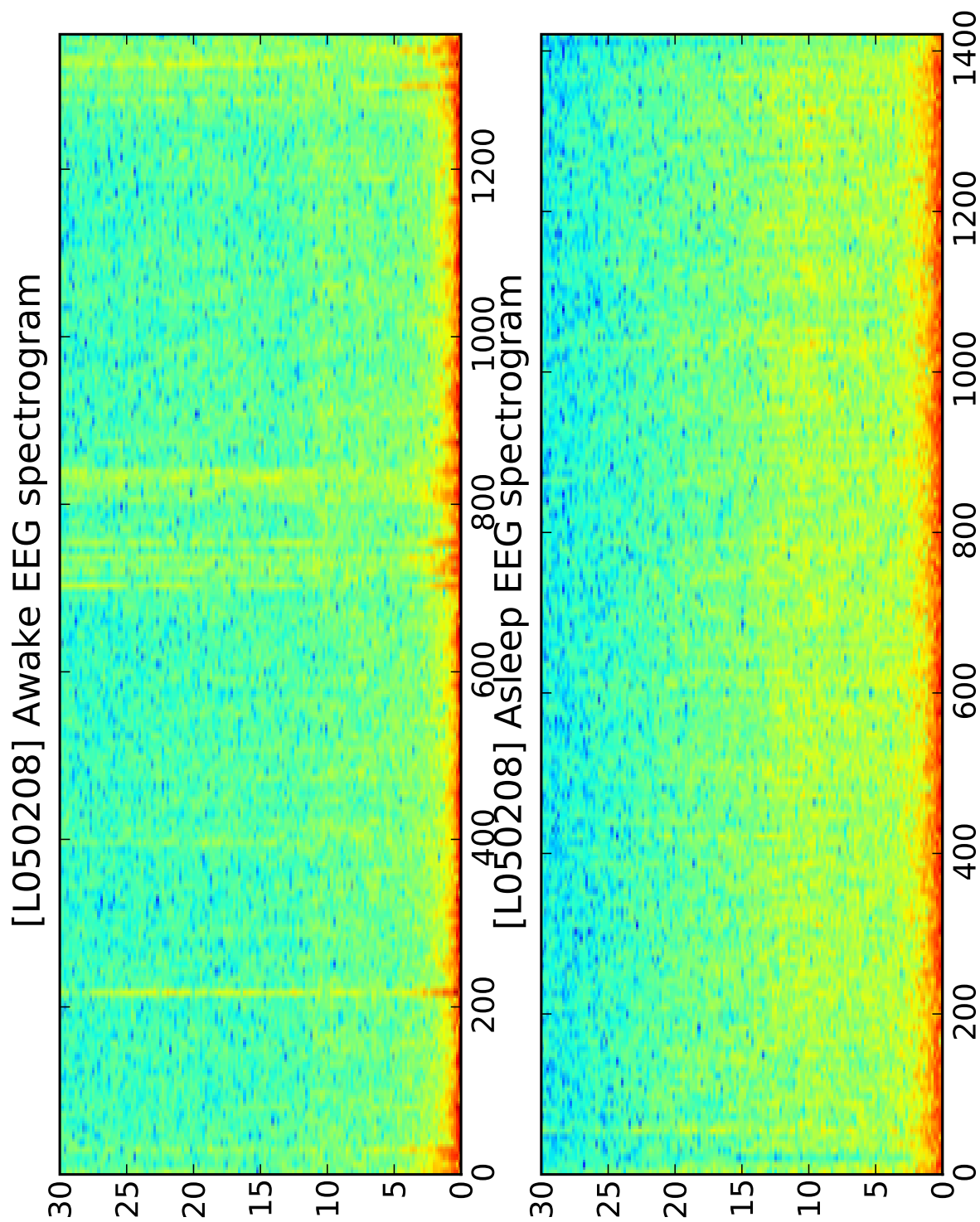


Figure 14: EEG Spectrogram of patient L050208

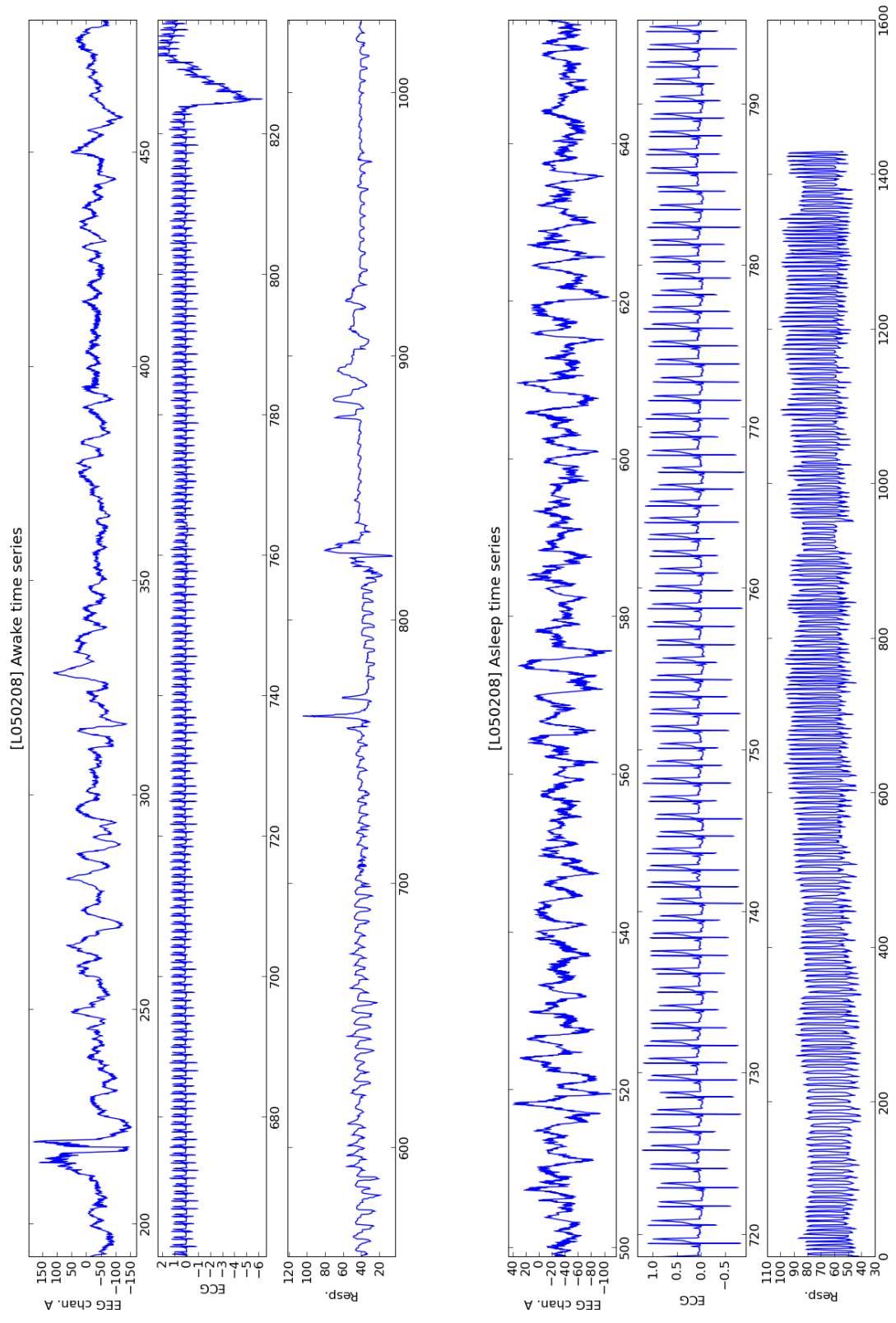


Figure 15: Time series samples of patient L050208

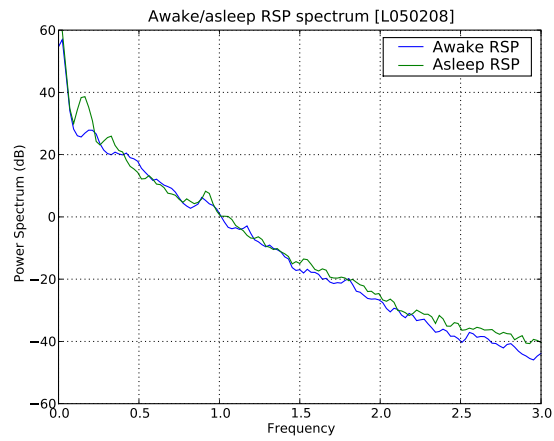
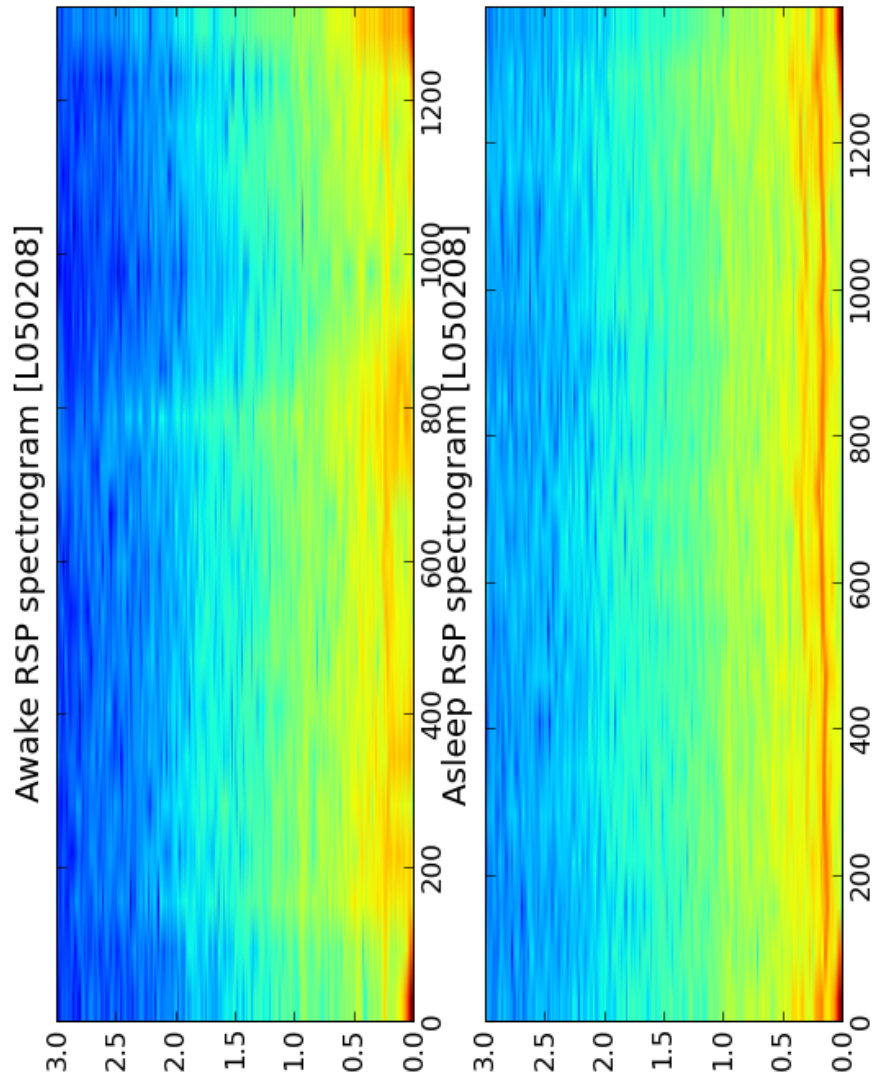


Figure 16: Time series samples of patient L050208

3.5 L061107

Comments

Sevoflurane with curare was administered.

Awake EEG Low power 9Hz alpha activity, diffuse. Not seen in spectrum but is seen in spectrogram.

Awake ECG Good quality ECG wave with some point faults.

Awake Respiration Respiration has good quality and even amplitude.

Asleep EEG Strong alpha peak 10Hz. More defined at beginning and diffuse at end (spectrogram).

Asleep ECG Clean signal, slight amplitude variation.

Asleep Respiration Some amplitude variation, waveform is deformed and suspect possible ECG interference.

Plots

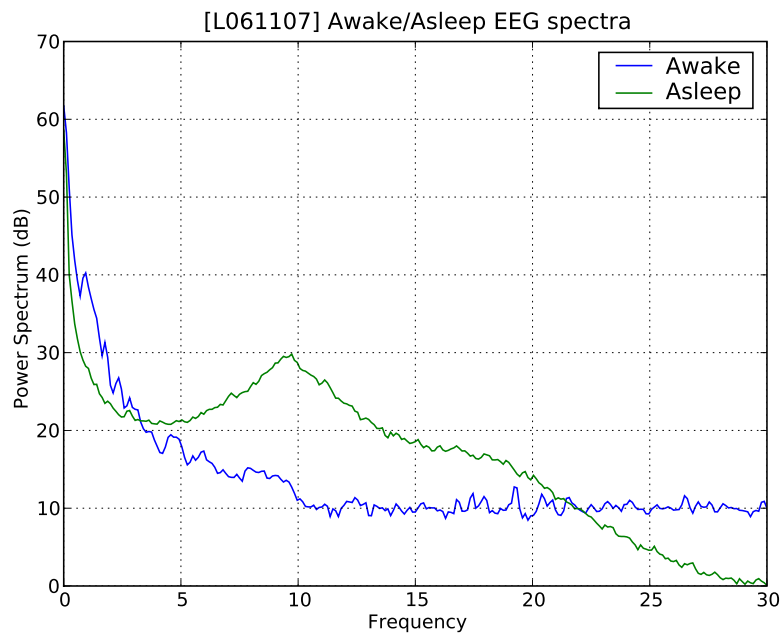


Figure 17: EEG Spectrum of patient L061107

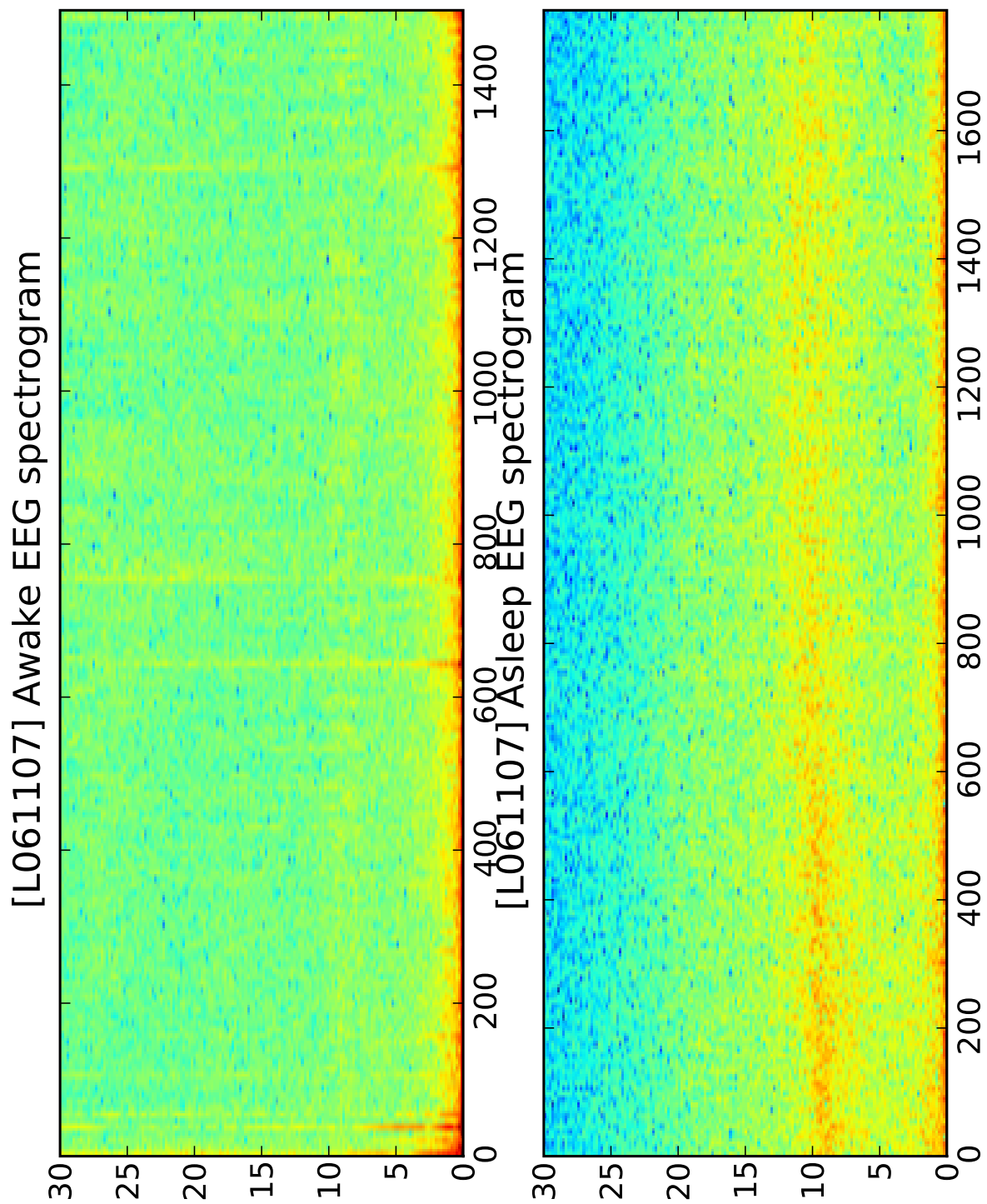


Figure 18: EEG Spectrogram of patient L061107

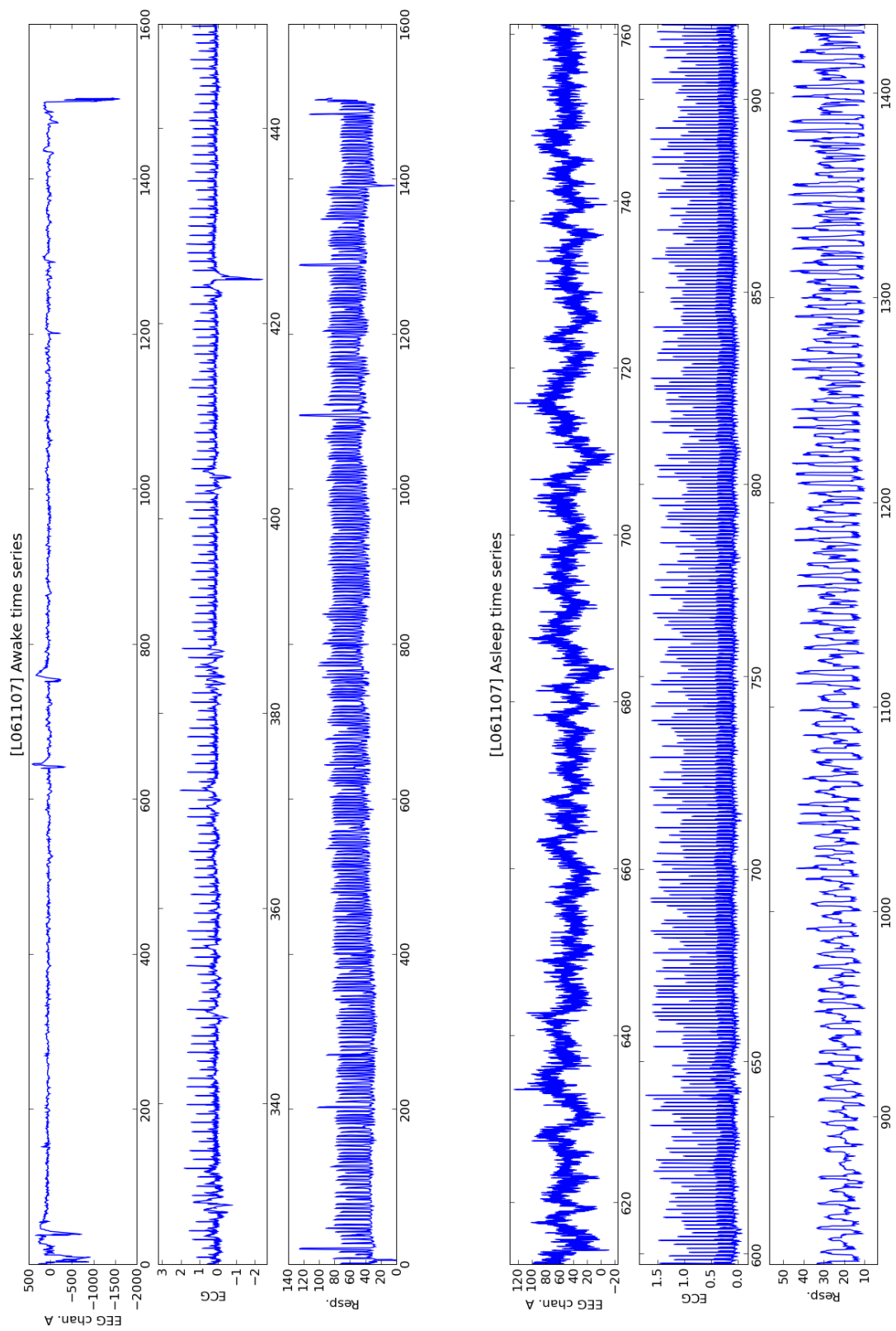


Figure 19: Time series samples of patient L061107

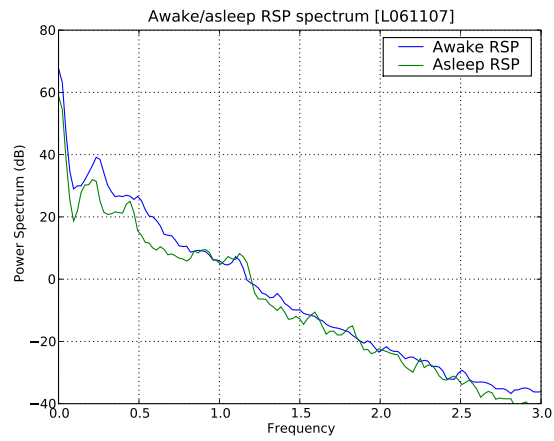
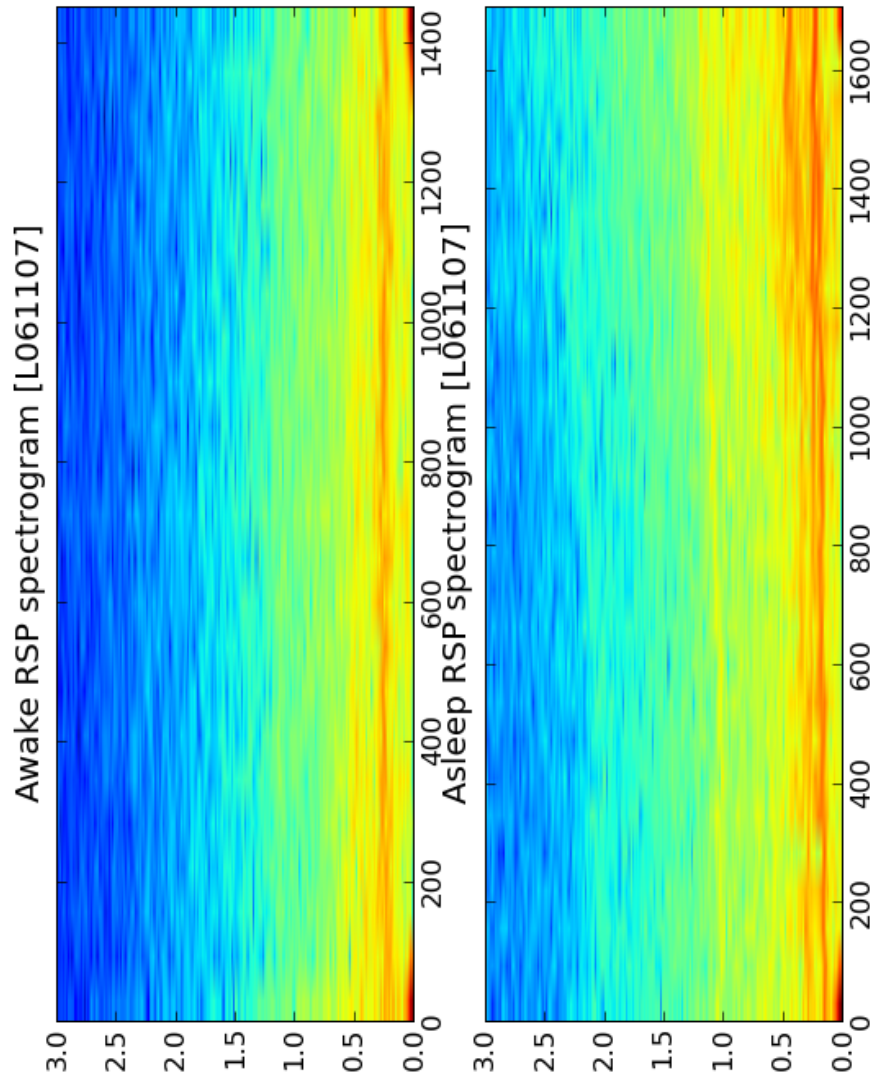


Figure 20: Time series samples of patient L061107

3.6 L080708

Comments

Sevoflurane was administered. Patient has no definable activity in the EEG in either state. Reverse polarity ECG.

Awake EEG Low amplitude activity with some large amplitude artefacts (?). No definable activity.

Awake ECG Reverse polarity, clean signal. Slight baseline variations.

Awake Respiration Large amplitude variation but smooth. Irregular breathing, mostly good waveforms.

Asleep EEG No definable activity, stronger power than awake EEG (specgram, spectrum).

Asleep ECG Clean, reverse polarity signal.

Asleep Respiration Clean waveform, smooth amplitude variations.

Plots

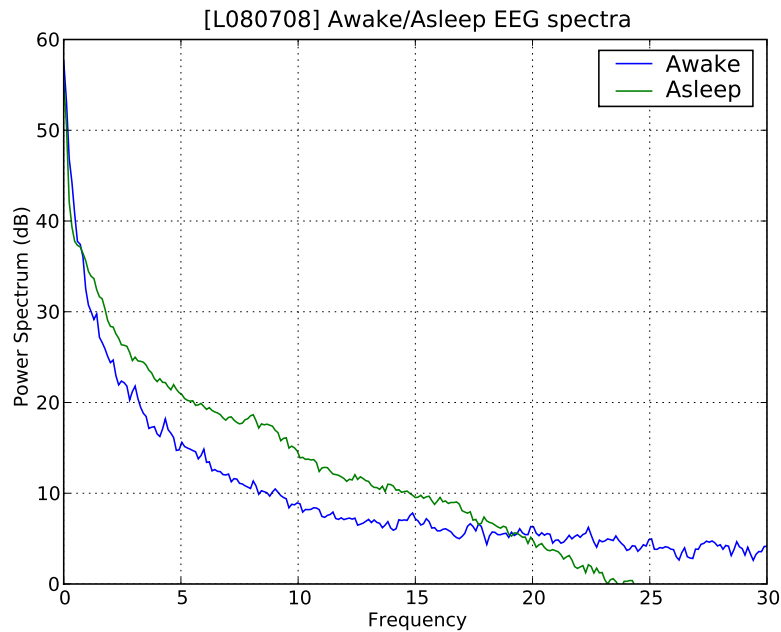


Figure 21: EEG Spectrum of patient L080708

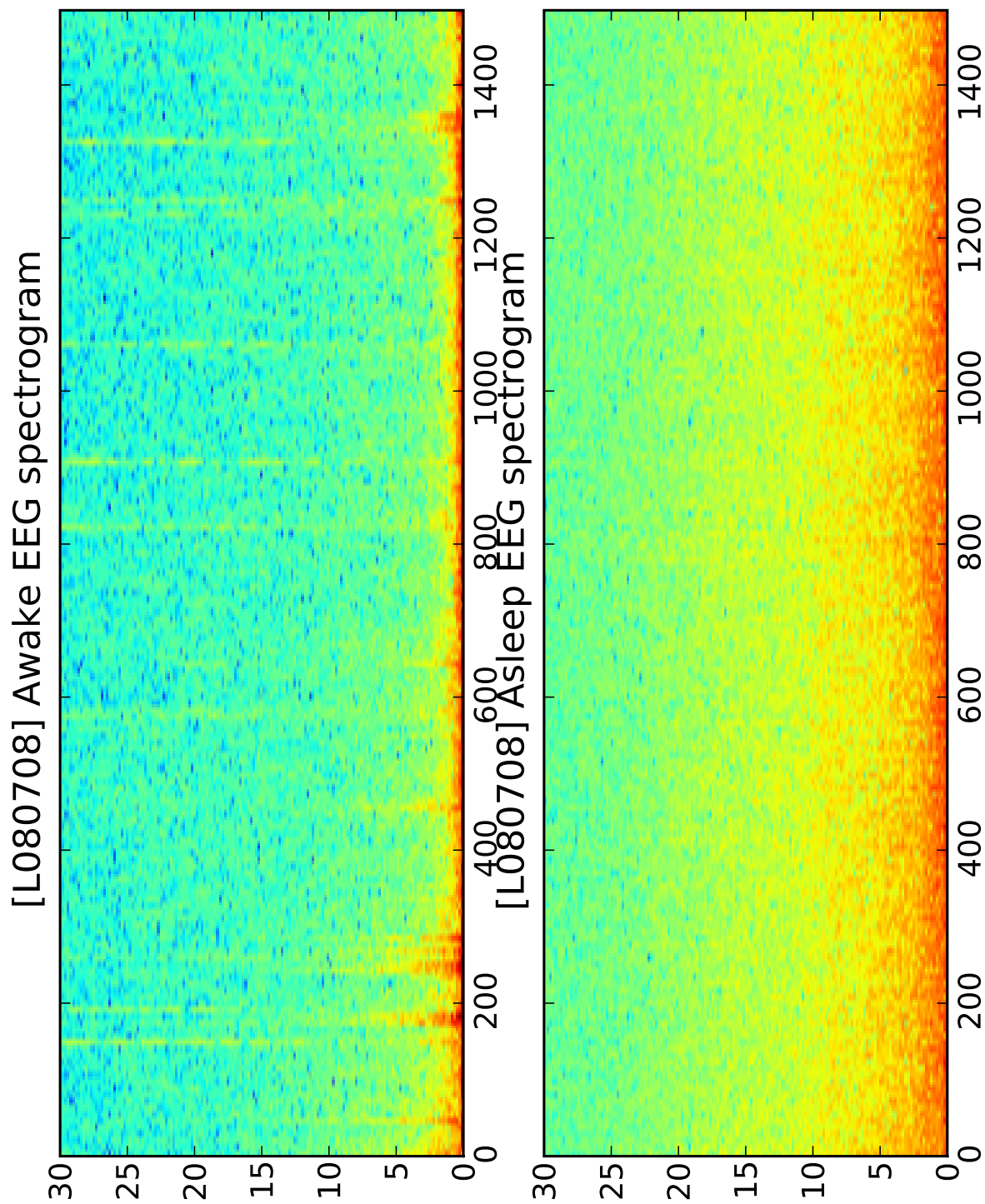


Figure 22: EEG Spectrogram of patient L080708

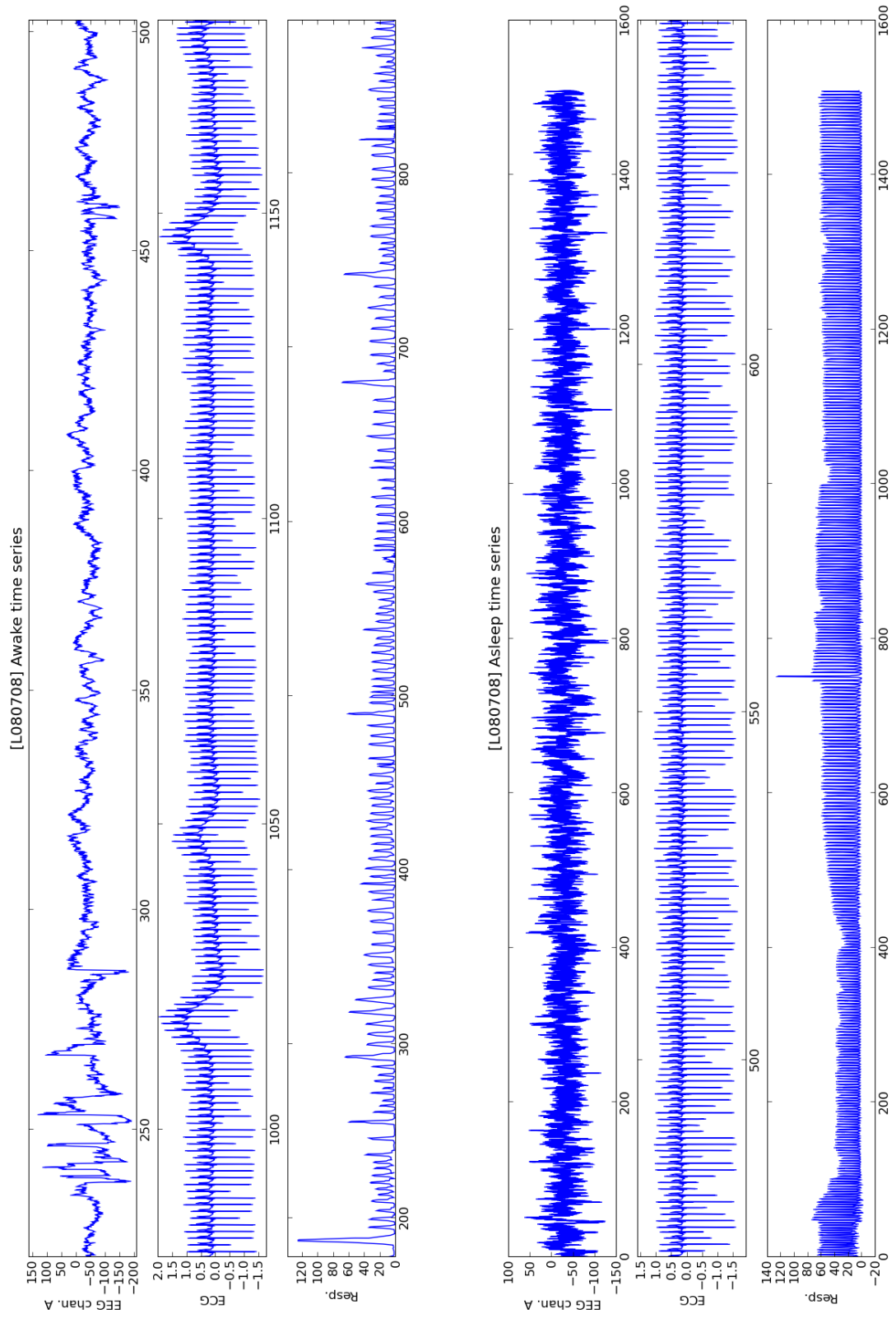


Figure 23: Time series samples of patient L080708

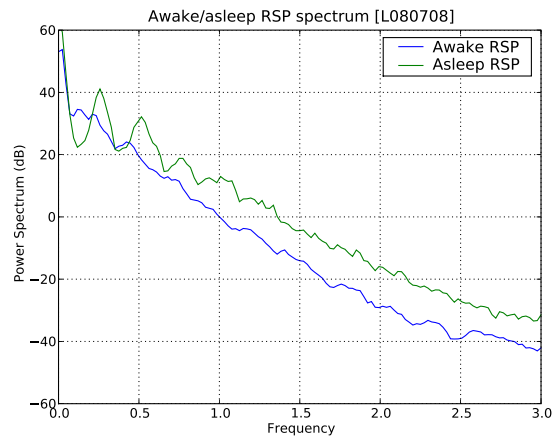
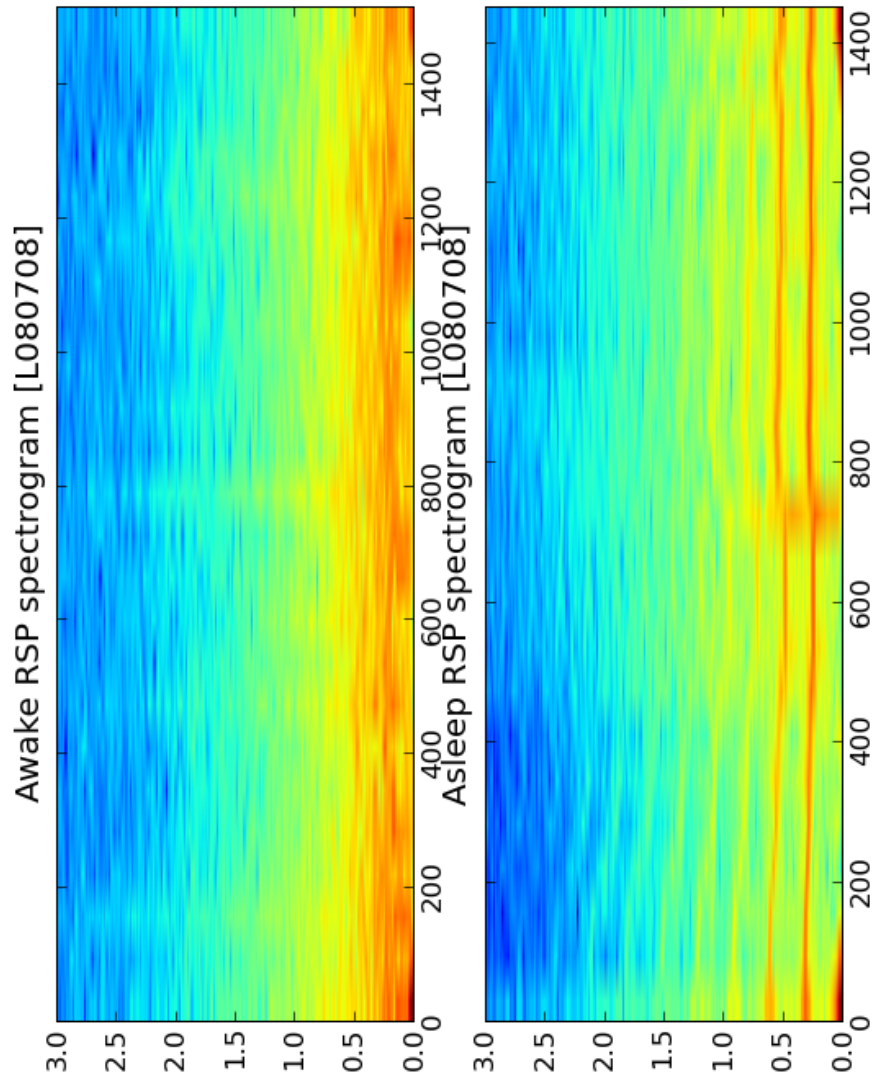


Figure 24: Time series samples of patient L080708

3.7 L100708

Comments

Sevoflurane with curare was administered.

Awake EEG Nothing visible in spectrogram or spectrum. Nice looking EEG waveform.

Awake ECG Good signal with amplitude variations.

Awake Respiration Passable signal, mostly good quality with intermittent baseline and amplitude variations.

Asleep EEG Weak alpha (12Hz) activity, visible in spectrogram. Small peak in low delta band (0.5Hz) in spectrum, not seen in spectrogram.

Asleep ECG Clean signal.

Asleep Respiration Peaked waveform, overlaid noise especially on baseline. Very irregular breathing. Peaks well defined.

Plots

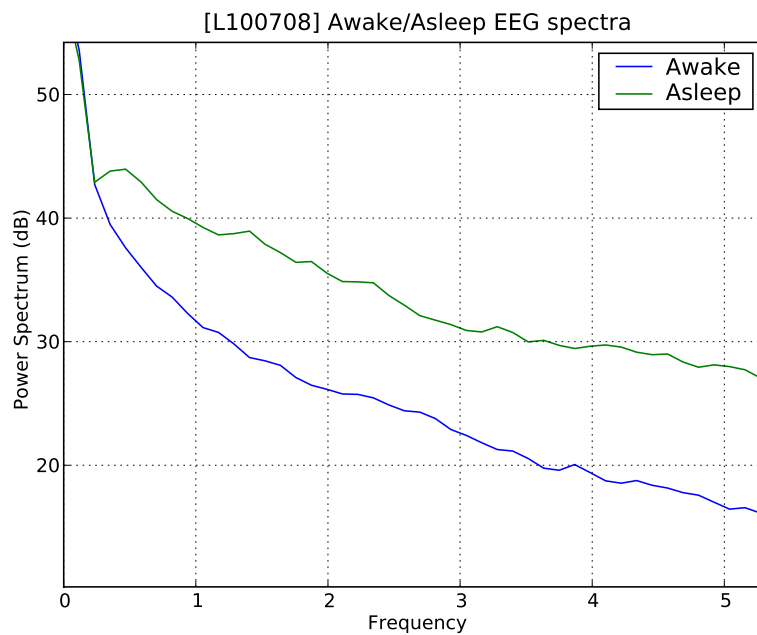


Figure 25: EEG Spectrum of patient L100708

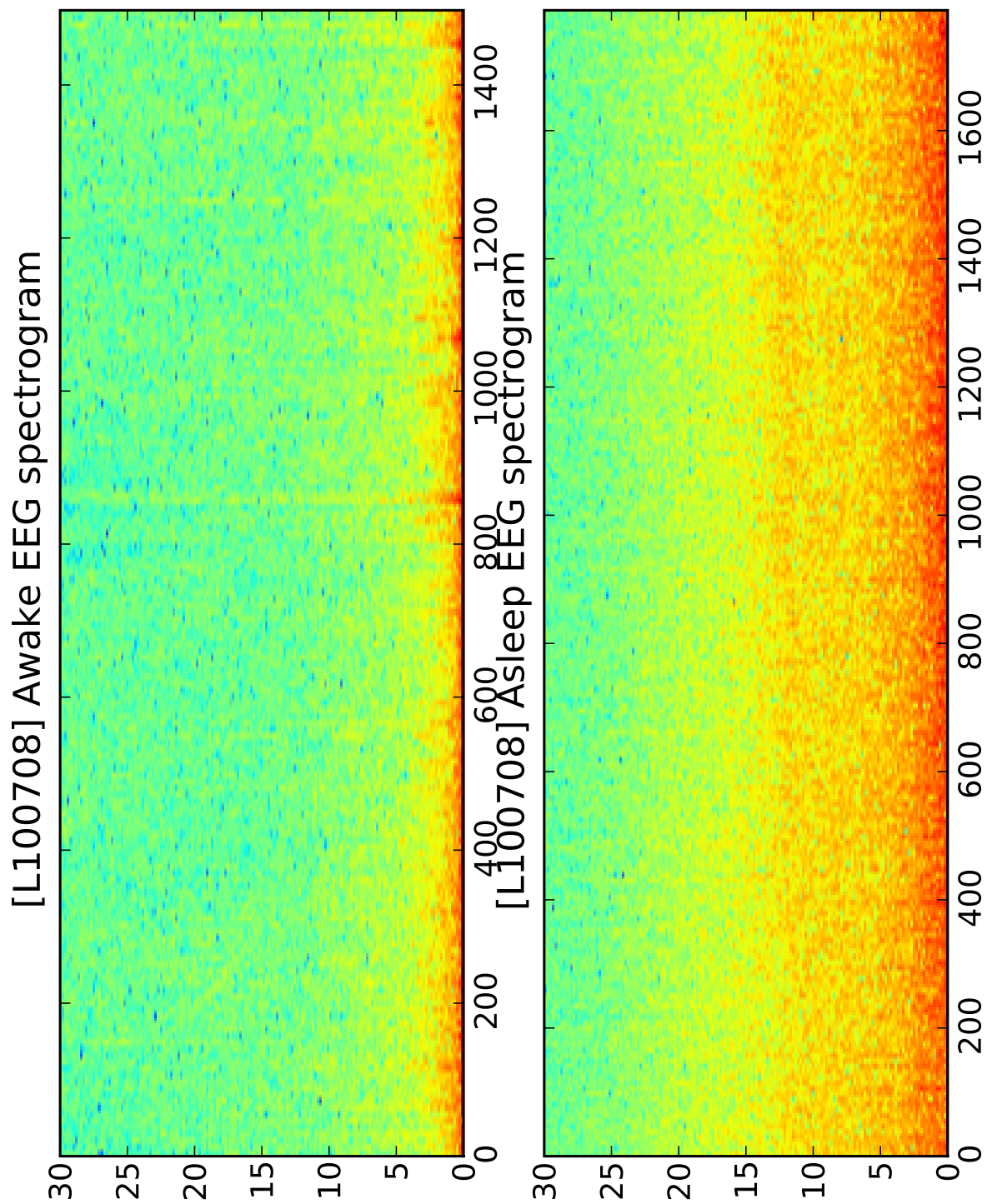


Figure 26: EEG Spectrogram of patient L100708

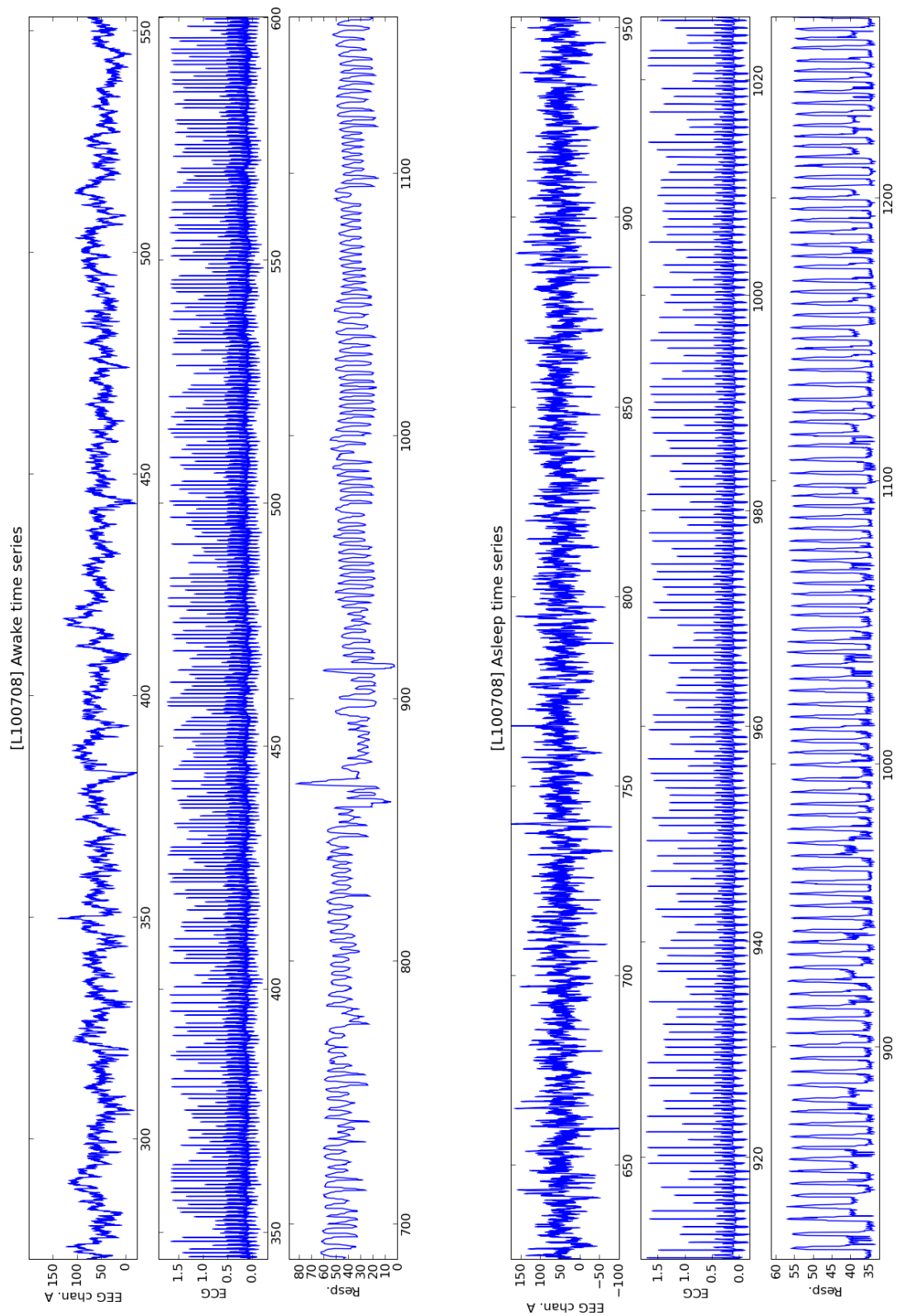


Figure 27: Time series samples of patient L100708

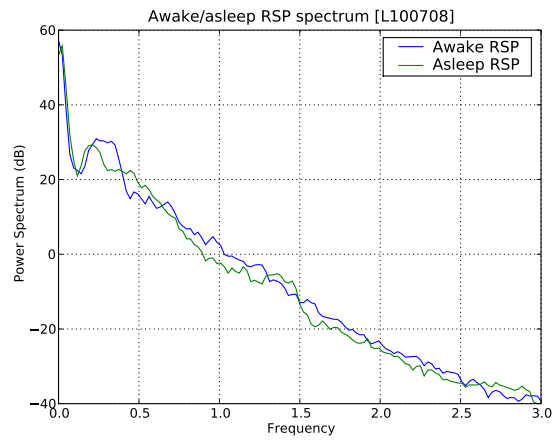
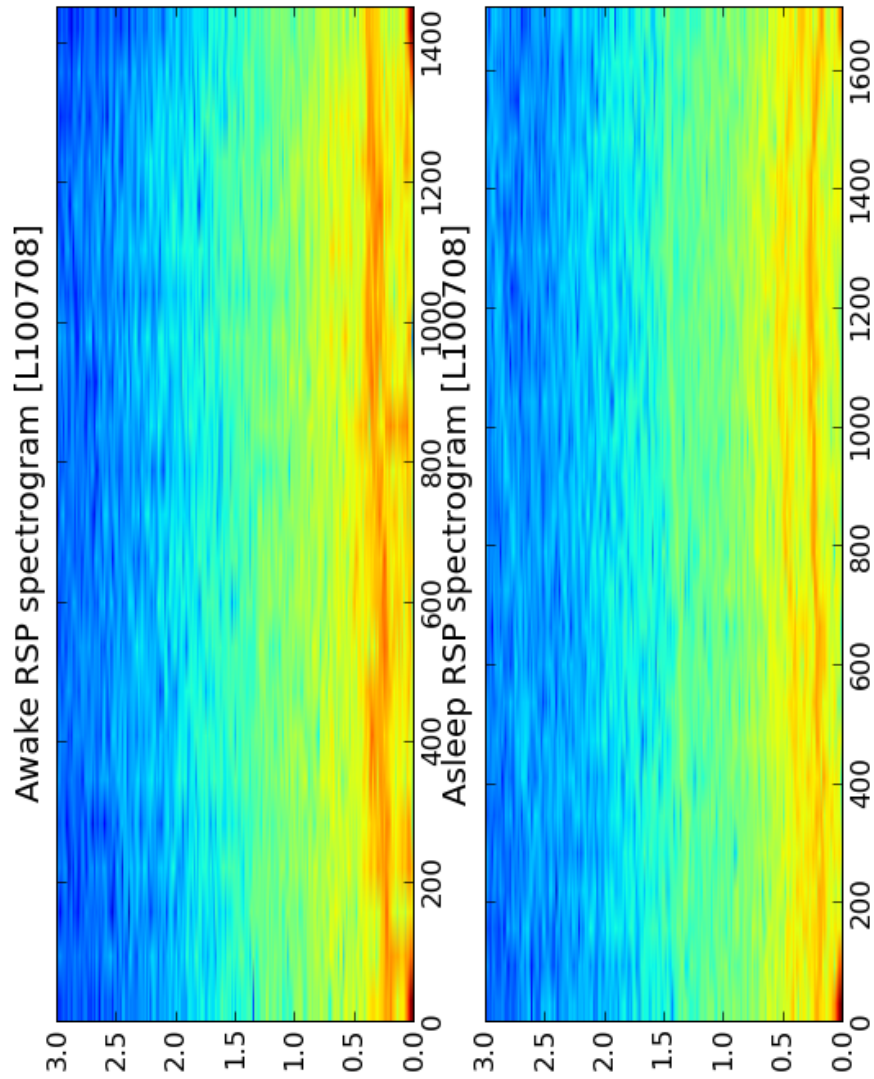


Figure 28: Time series samples of patient L100708

3.8 L110708

Comments

Propofol with curare was administered. Very irregular breathing under anesthesia.

Awake EEG No clear activity. Signal has some large amplitude artefacts.

Awake ECG Very clean signal.

Awake Respiration Good quality signal, nice waveform.

Asleep EEG Strong well-defined alpha (12Hz) activity.

Asleep ECG Very clean signal.

Asleep Respiration Either patient has very irregular breathing or signal faults. Sharp peaked waveform.

Plots

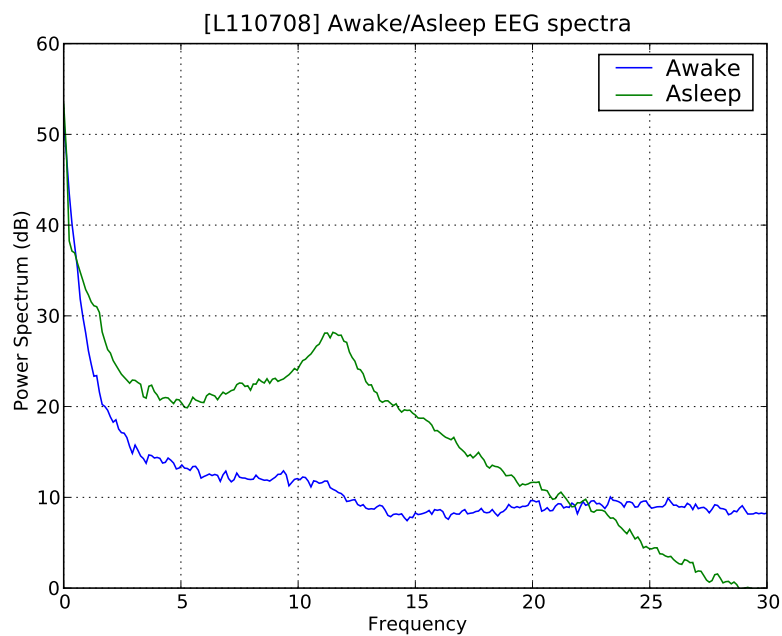


Figure 29: EEG Spectrum of patient L110708

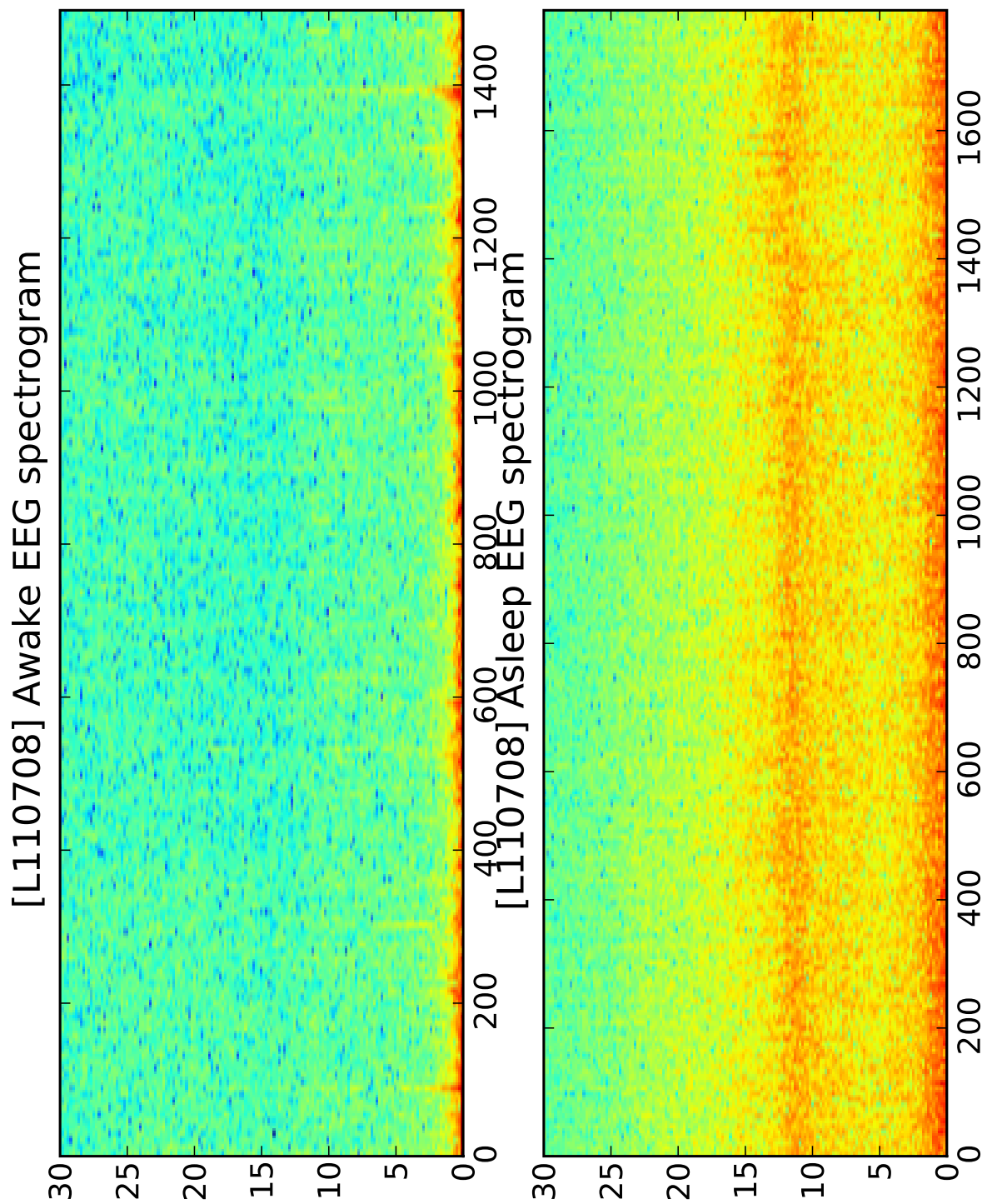


Figure 30: EEG Spectrogram of patient L110708

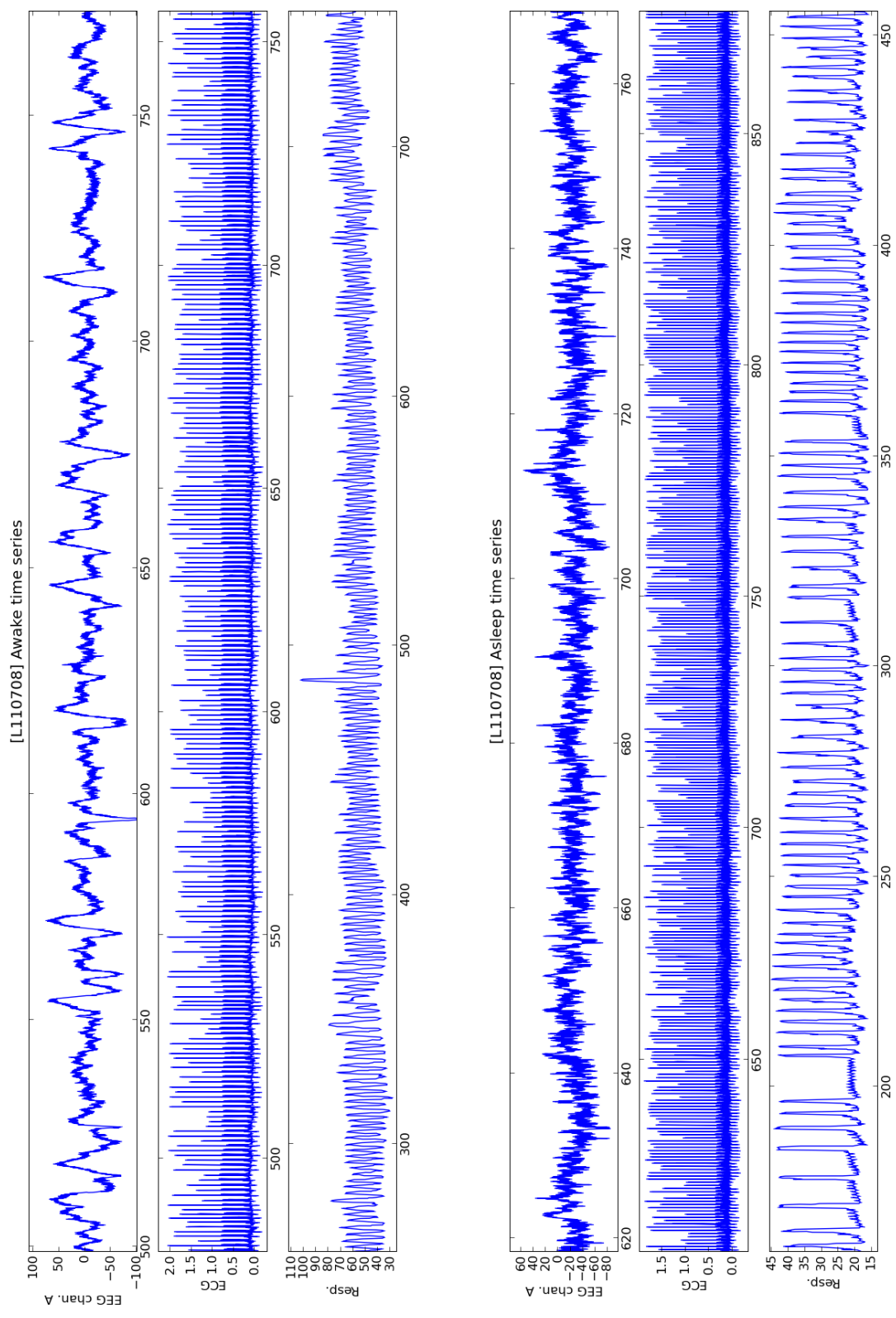


Figure 31: Time series samples of patient L110708

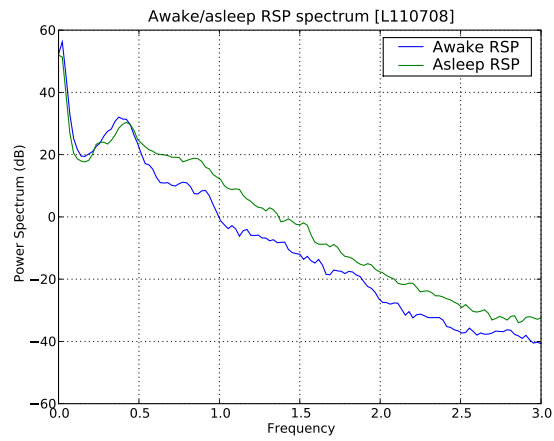
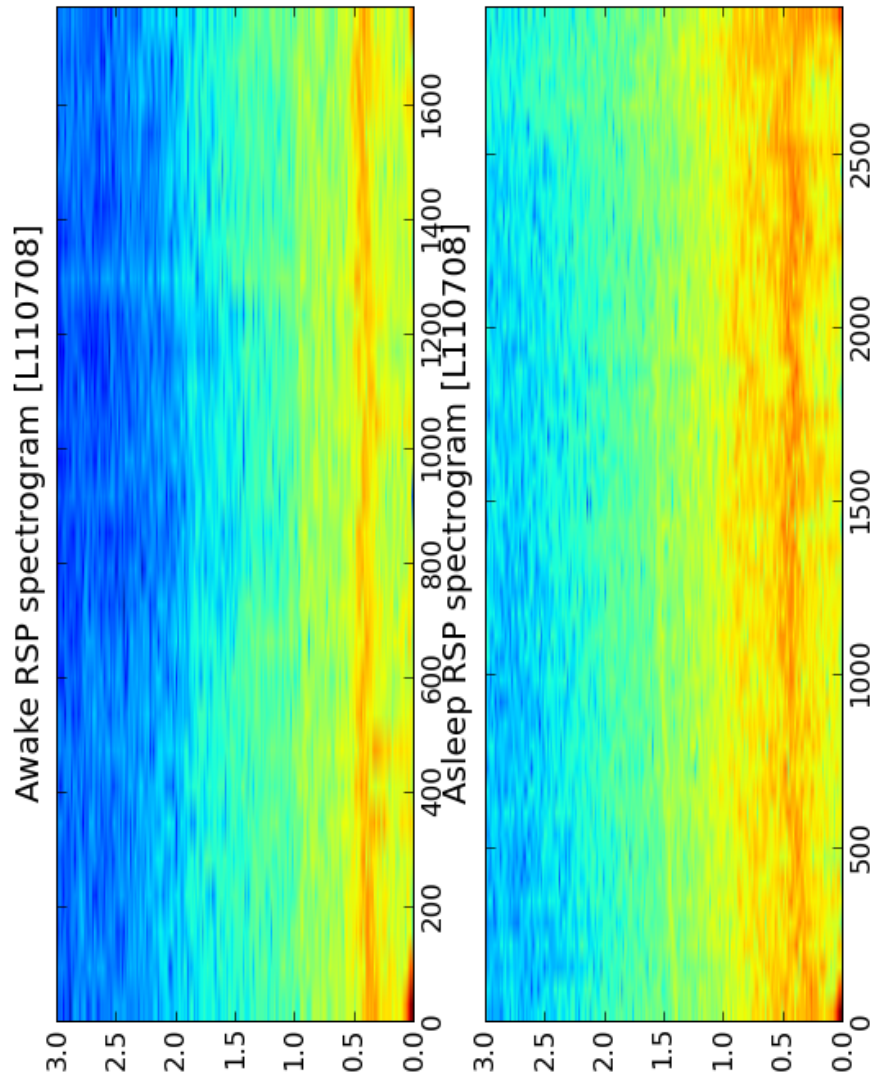


Figure 32: Time series samples of patient L110708

3.9 L120208

Comments

Sevoflurane was administered. Has bad awake respiration.

Awake EEG May have 2.5Hz delta band activity. Very low peak. Not visible in spectrogram except in beginning (slightly).

Awake ECG Amplitude variations, clean signal.

Awake Respiration Some high amplitude faults. Some missing breaths (25secs around 600s, 25secs around 800s).

Asleep EEG Strong well-defined alpha activity (10Hz).

Asleep ECG Amplitude variations, good baseline, good signal.

Asleep Respiration Trend at start, reasonable sharp-peak waveform.

Plots

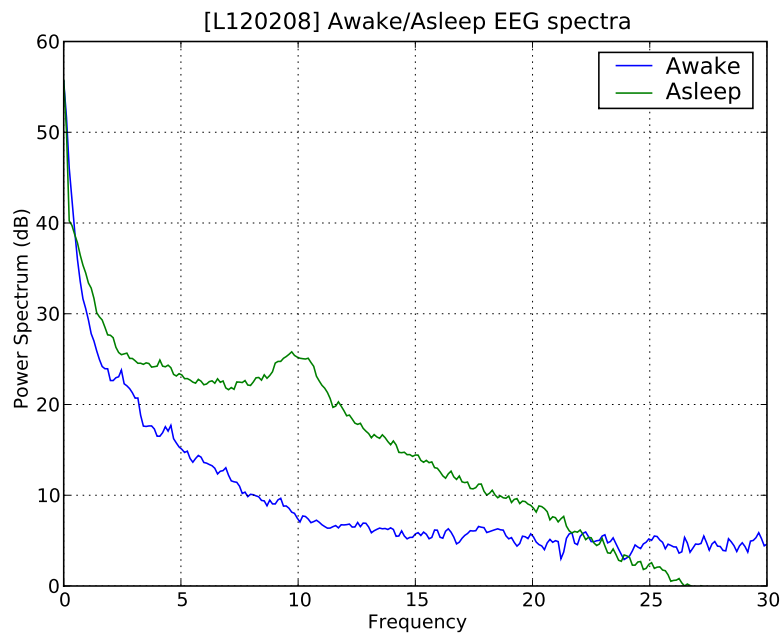


Figure 33: EEG Spectrum of patient L120208

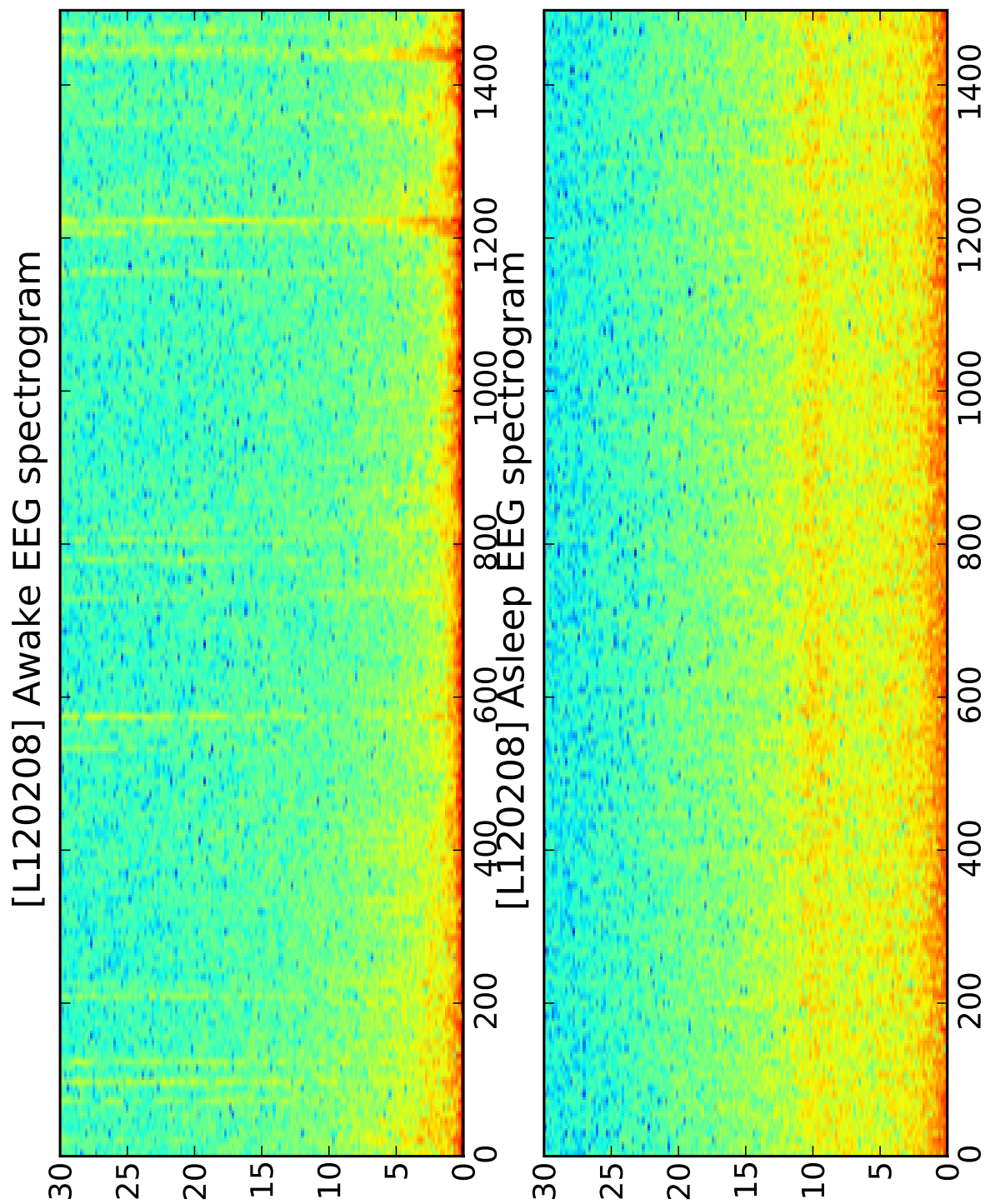


Figure 34: EEG Spectrogram of patient L120208

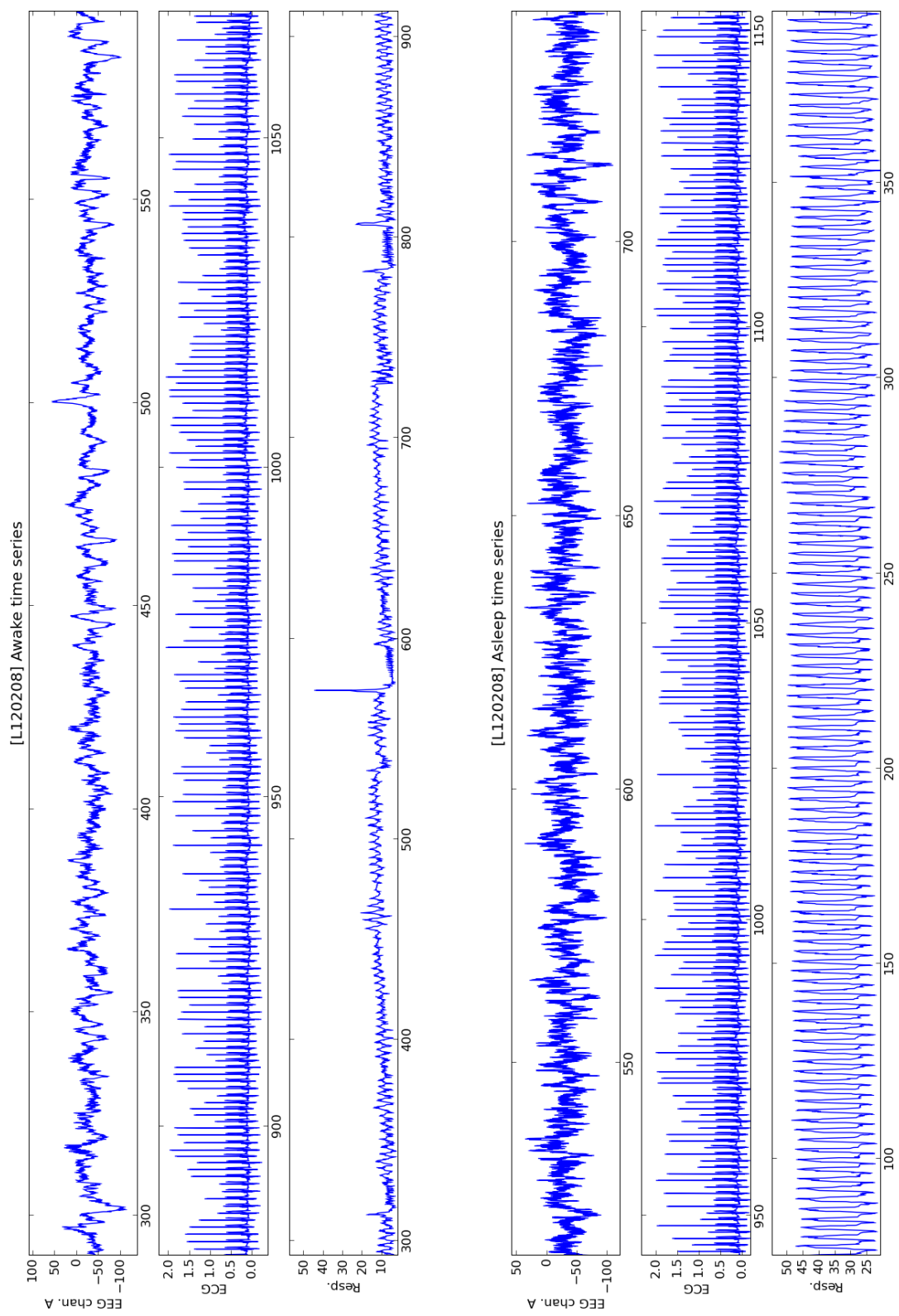


Figure 35: Time series samples of patient L120208

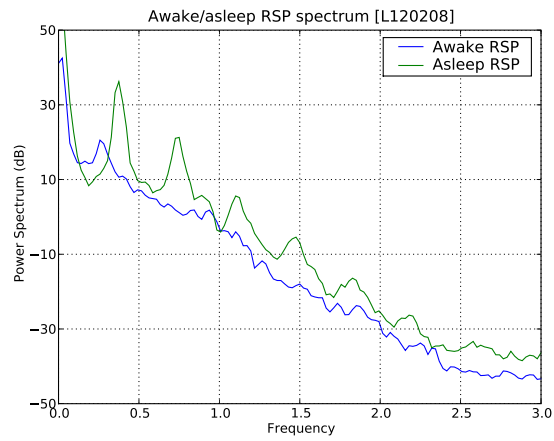
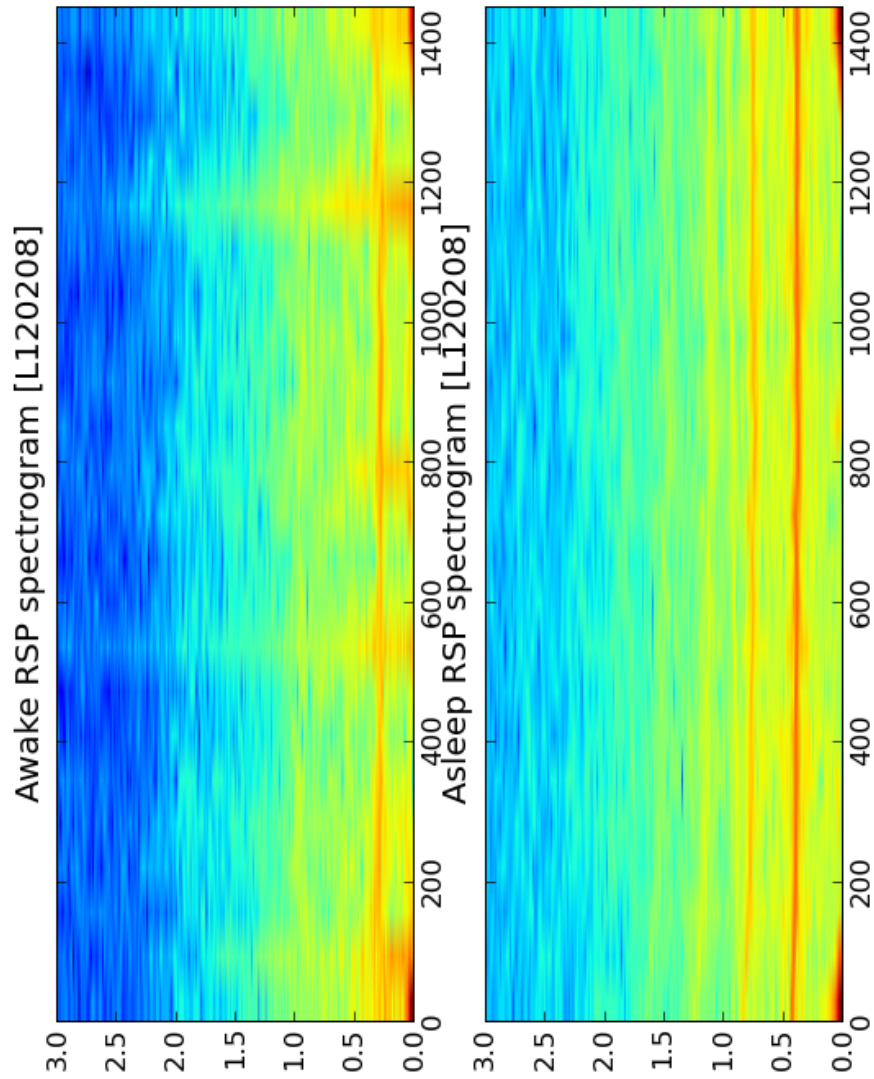


Figure 36: Time series samples of patient L120208

3.10 L120608

Comments

Propofol with curare was administered. Many spikes in awake eeg contaminate spectrogram.

Awake EEG Spectrogram shows many spike faults. No well defined activity. EEG waveform has very low frequency with superimposed very high frequency activity.

Awake ECG Good signal.

Awake Respiration Baseline ok, small amplitude variations, valleys not smooth, peaks seem mostly smooth.

Asleep EEG Some 9-10Hz alpha activity.

Asleep ECG Clean signal.

Asleep Respiration Spiky signal, non-smooth valleys, sharp peaks, good baseline.

Plots

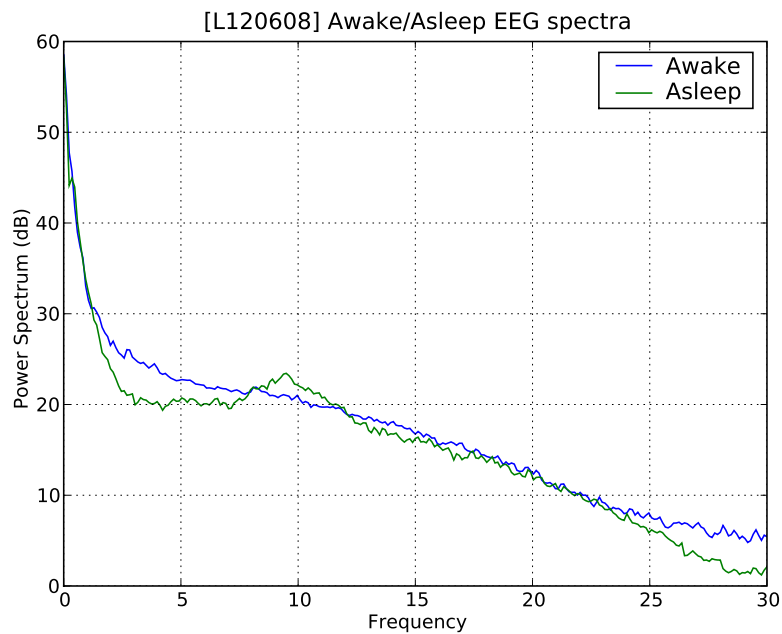


Figure 37: EEG Spectrum of patient L120608

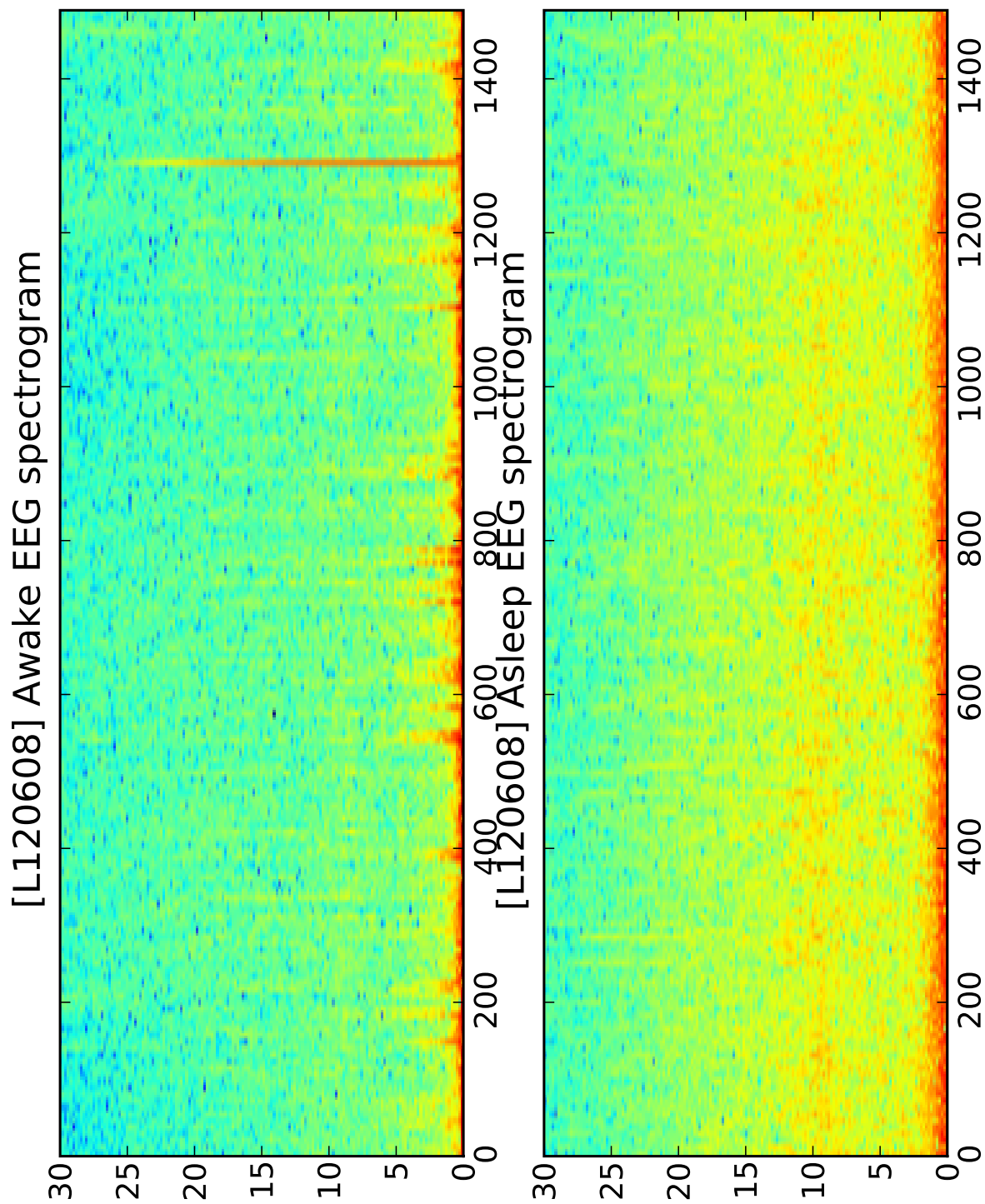


Figure 38: EEG Spectrogram of patient L120608

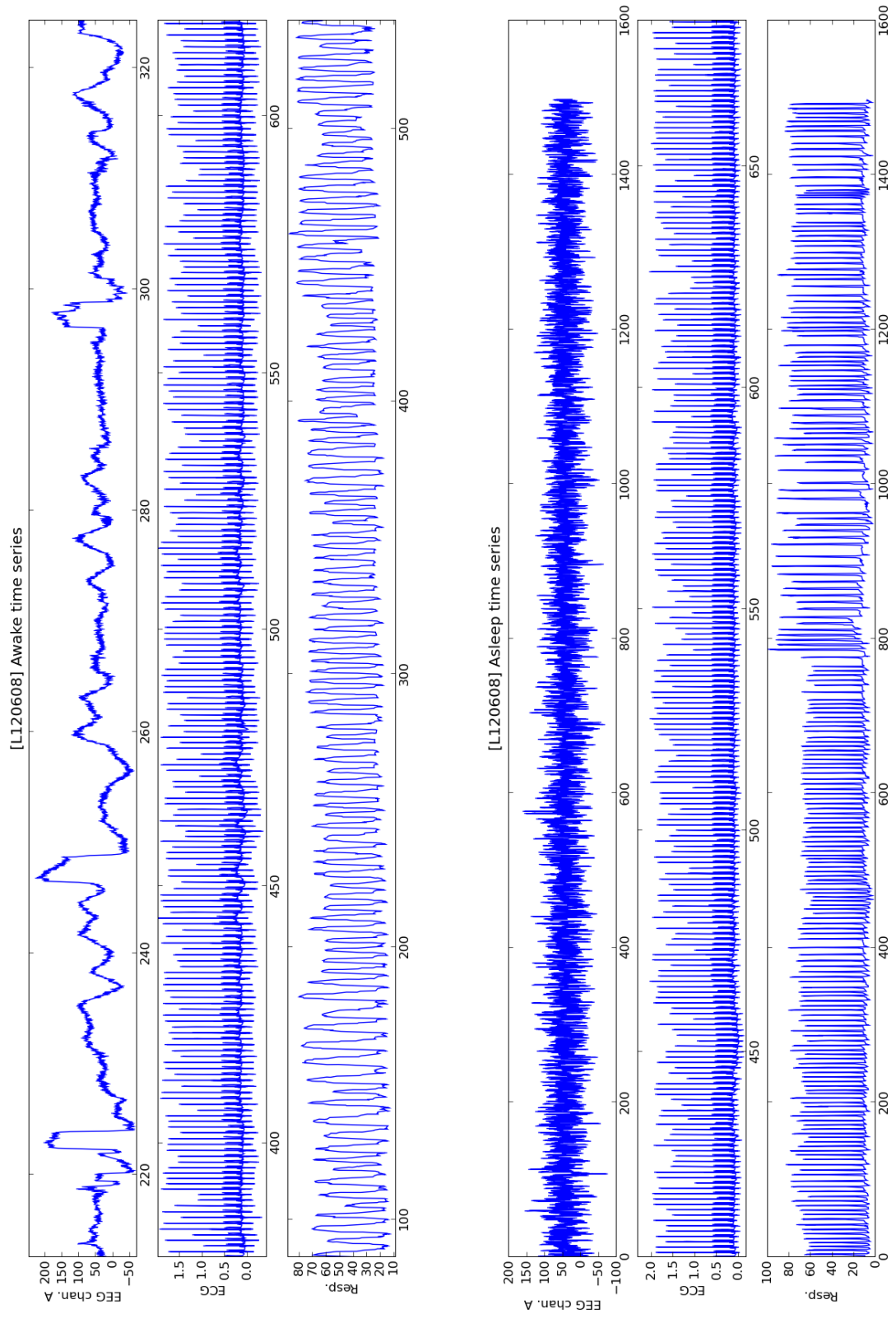


Figure 39: Time series samples of patient L120608

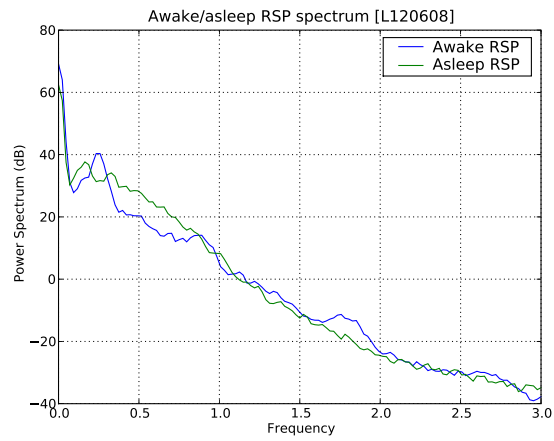
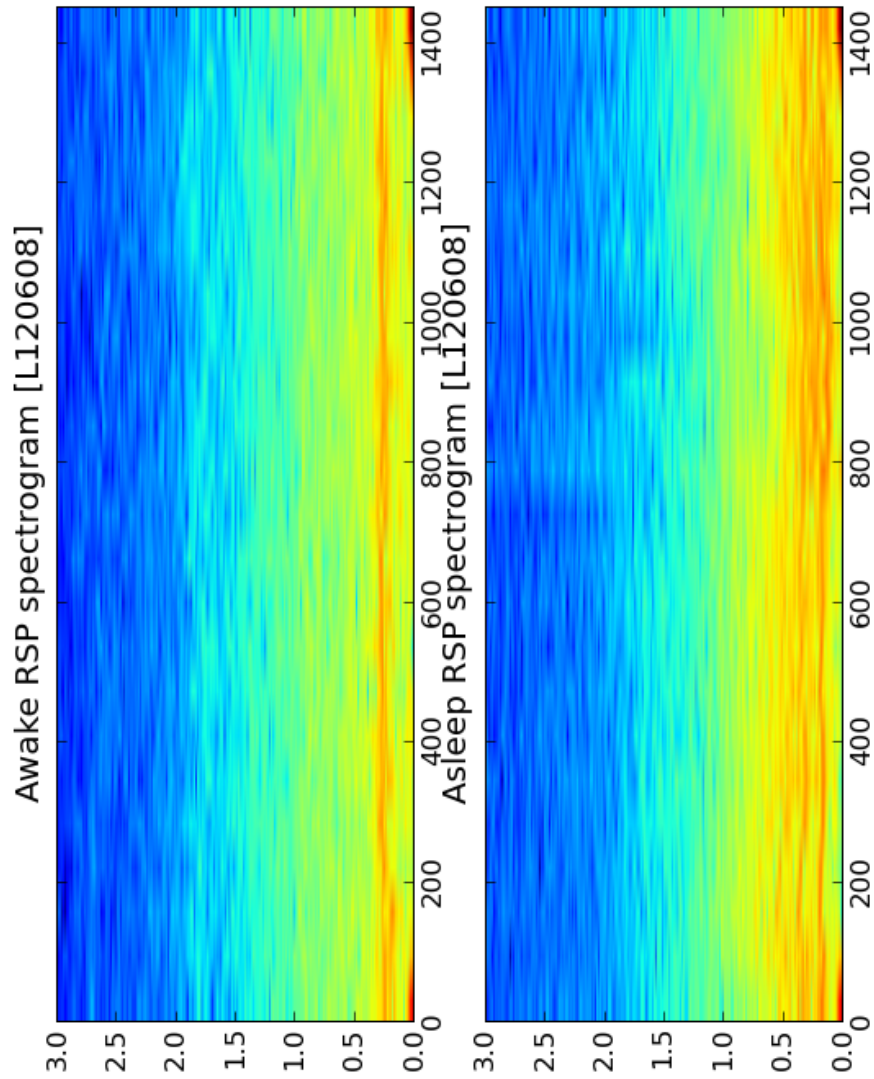


Figure 40: Time series samples of patient L120608

3.11 L130608

Comments

Sevoflurane with curare was administered. Lower frequency activity than other patients 7-8Hz in both states.

Awake EEG Some low power theta band activity on 7Hz, slightly diffuse.

Awake ECG Clean signal, stable baseline, some amplitude variations.

Awake Respiration Non-smooth valleys, well-defined peaks, good quality.

Asleep EEG Some 8Hz theta/alpha activity, low power peak. Some electrode disconnects (e.g. 780s for a few seconds).

Asleep ECG Good baseline, good quality signal.

Asleep Respiration Slightly irregular, non-smooth valleys.

Plots

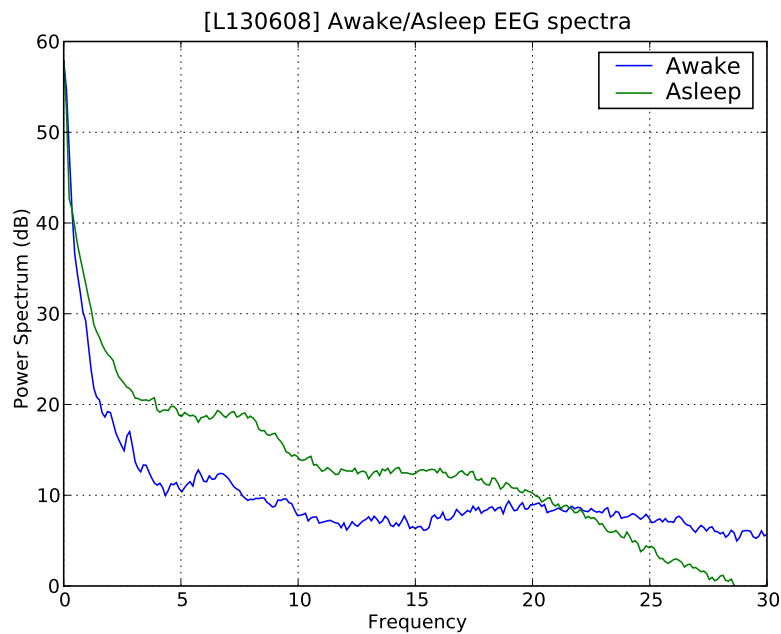


Figure 41: EEG Spectrum of patient L130608

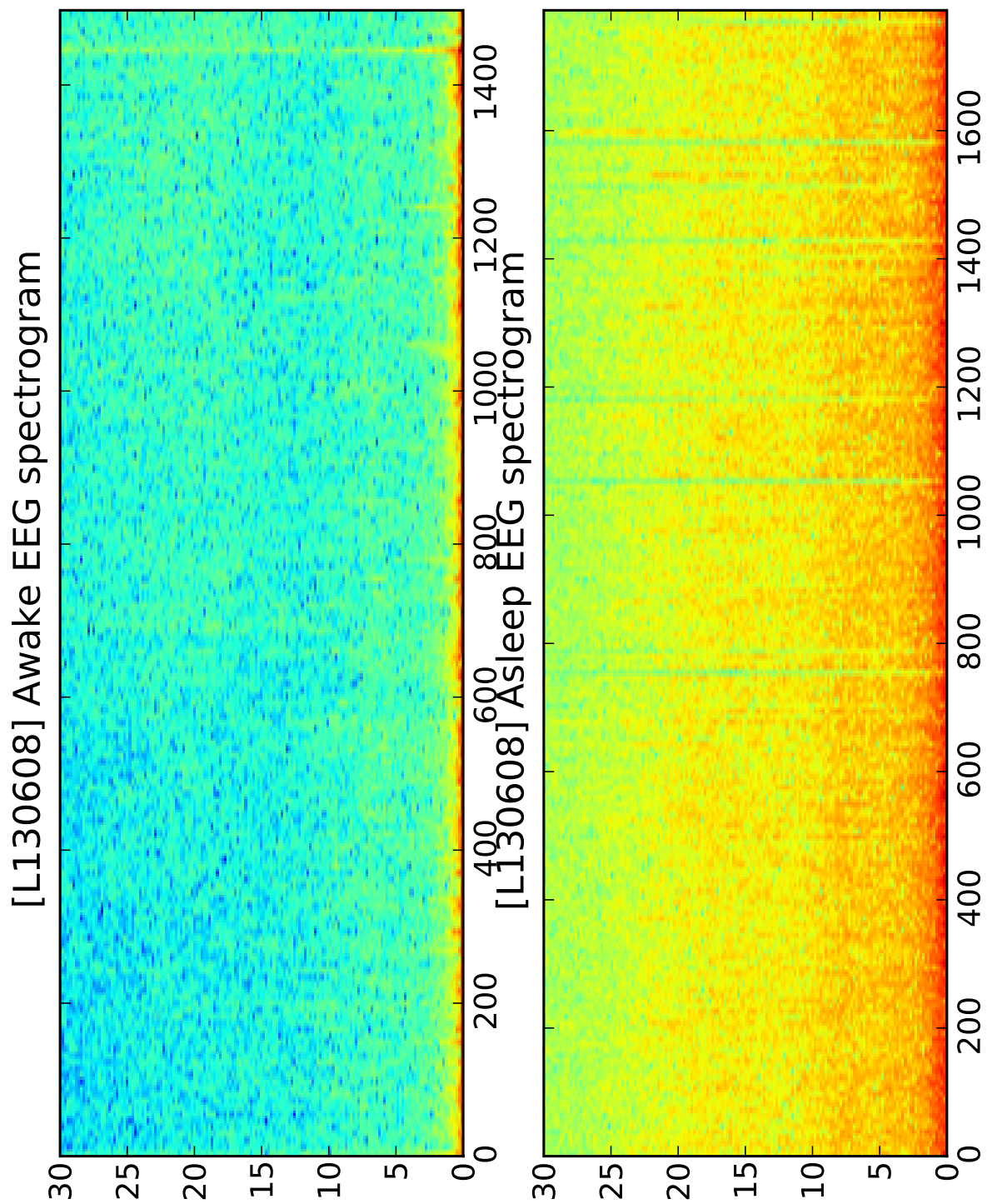


Figure 42: EEG Spectrogram of patient L130608

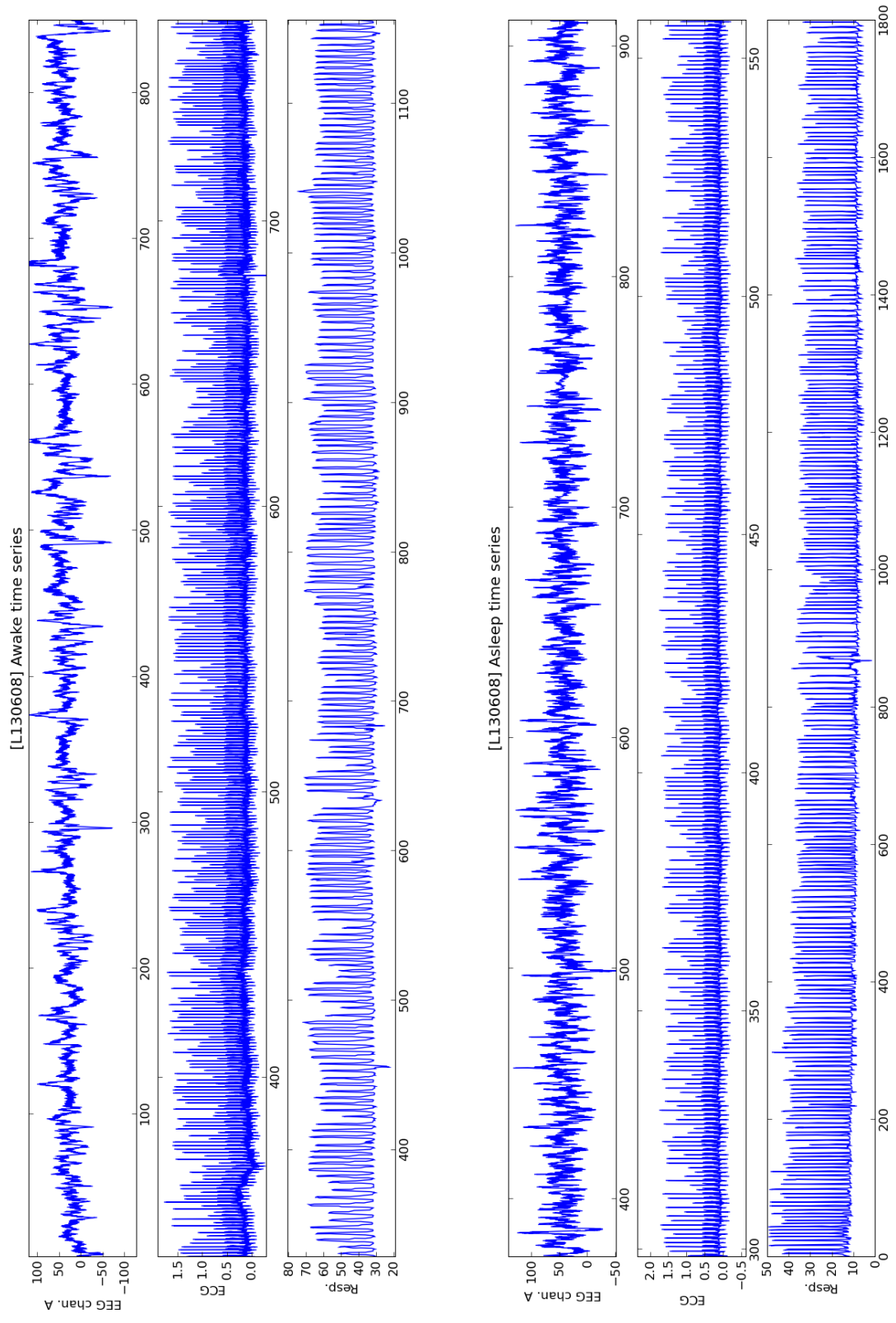


Figure 43: Time series samples of patient L130608

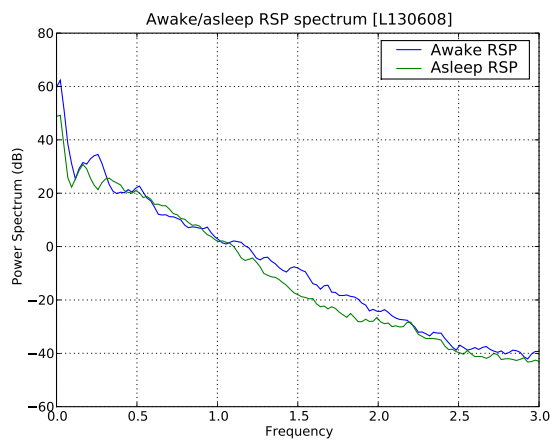
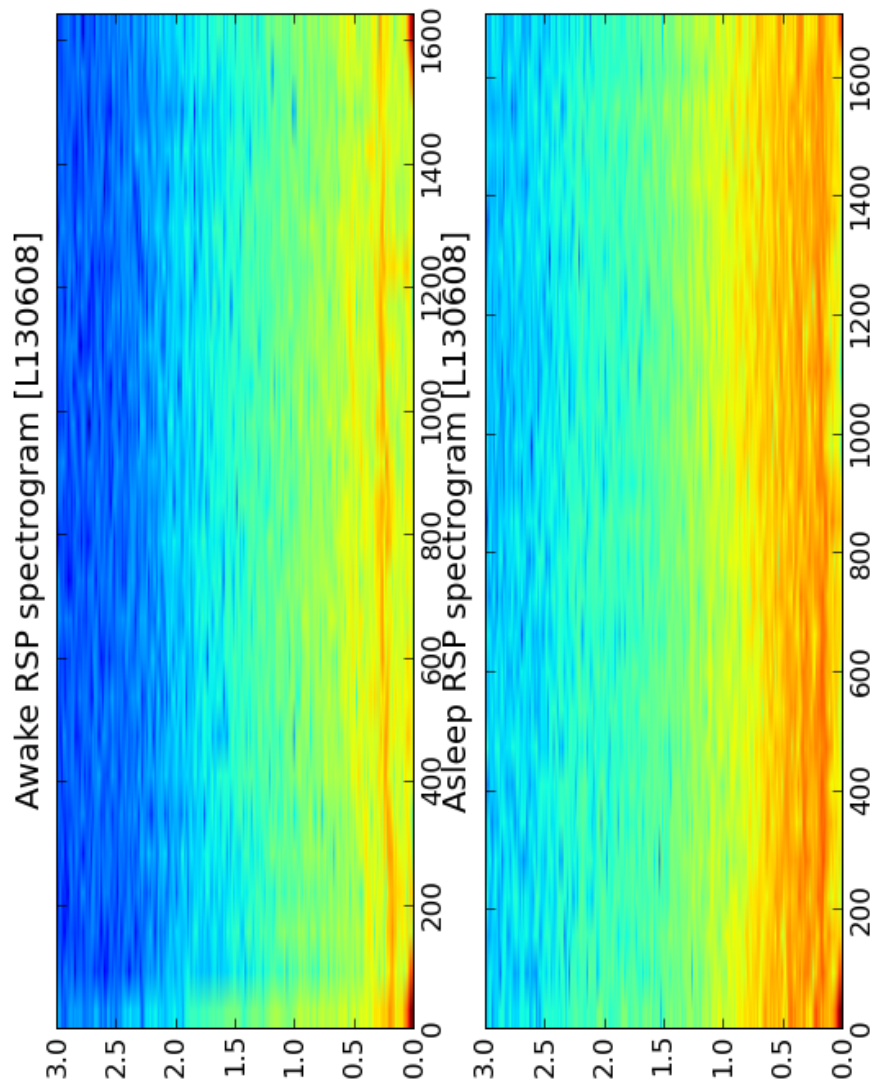


Figure 44: Time series samples of patient L130608

3.12 L140308

Comments

Propofol was administered. Patient is UNUSABLE.

Awake EEG No defined activity. Some large-amplitude artefacts.

Awake ECG Good quality signal.

Awake Respiration Extremely bad signal, probably unusable.

Asleep EEG Some 9Hz alpha band activity, low power.

Asleep ECG Clean signal.

Asleep Respiration Unusable signal. Not confident in extraction.

Plots

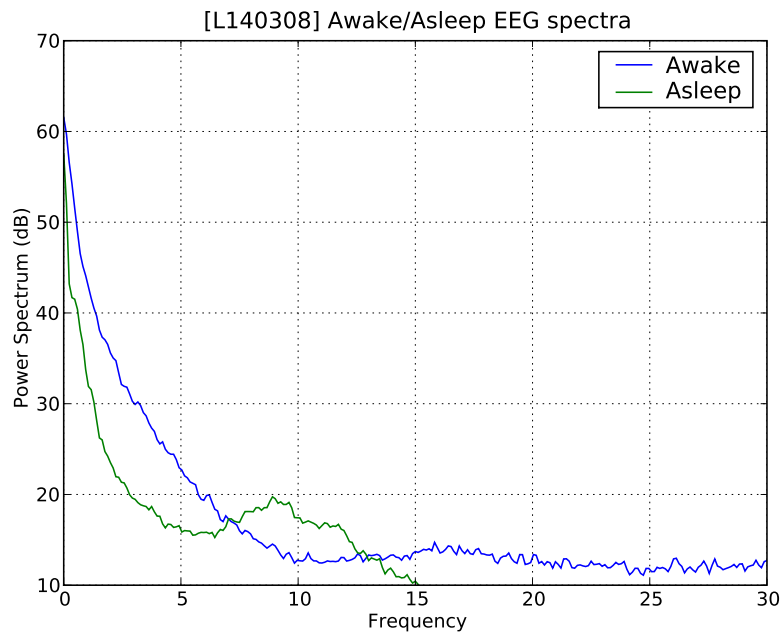


Figure 45: EEG Spectrum of patient L140308

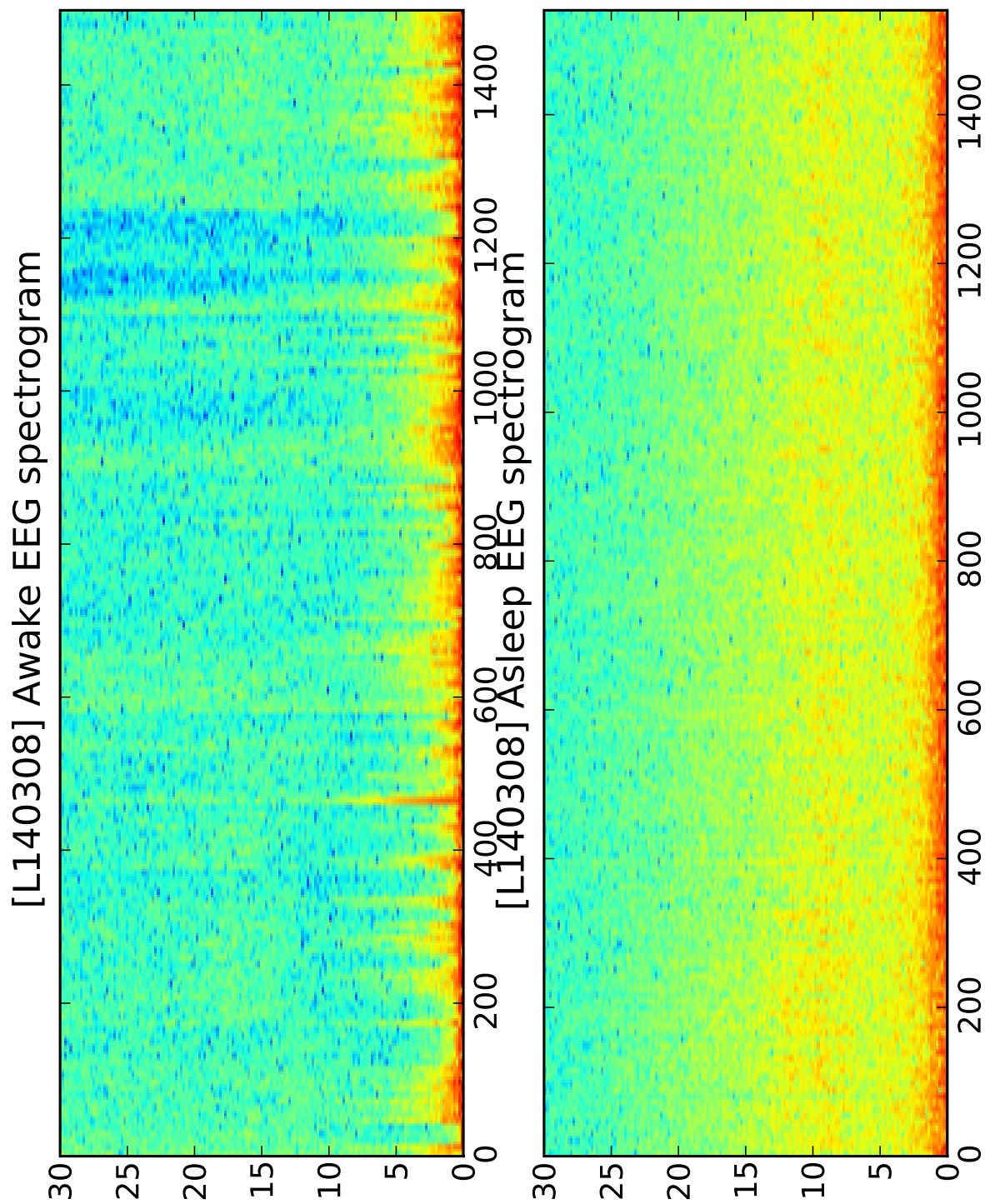


Figure 46: EEG Spectrogram of patient L140308

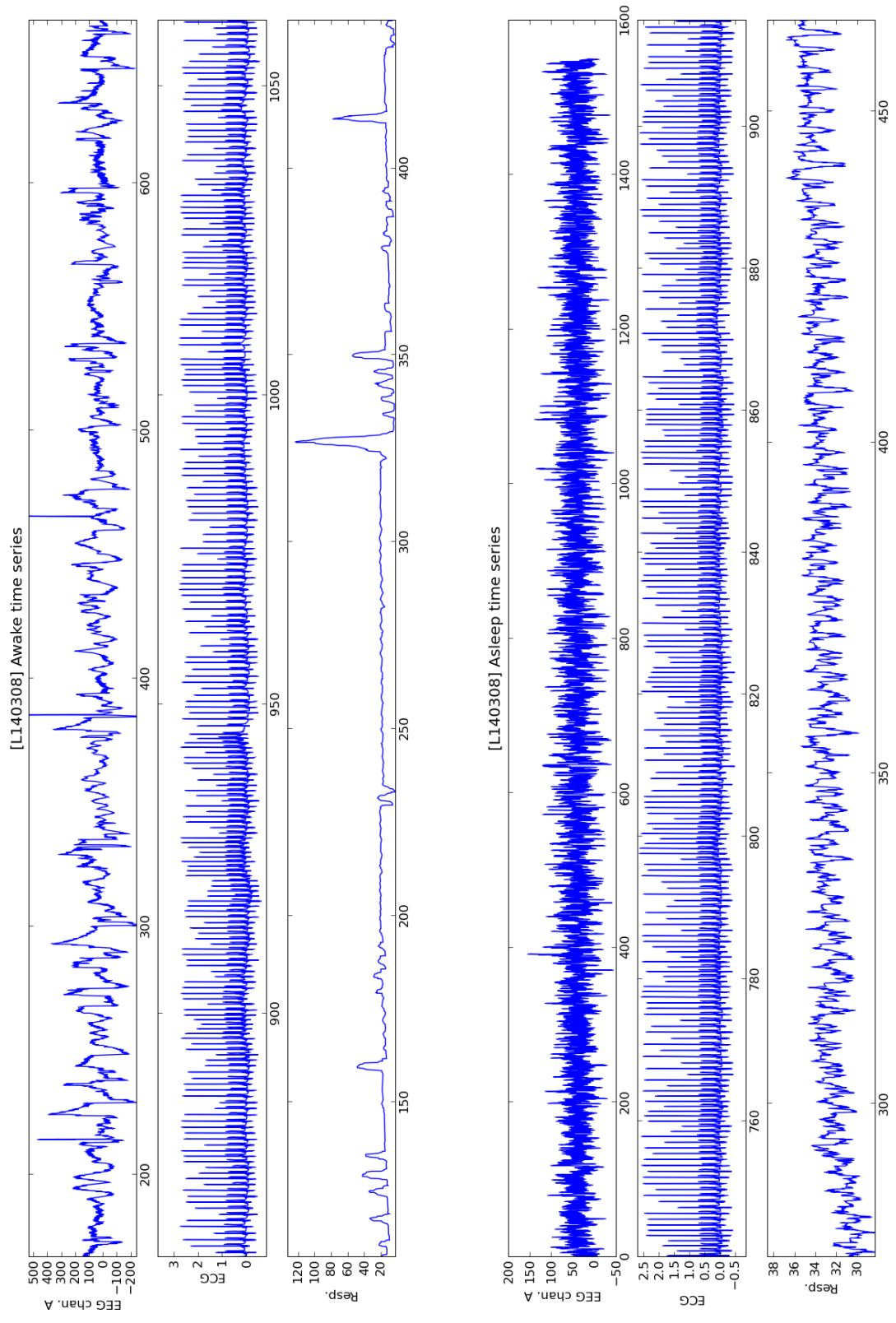


Figure 47: Time series samples of patient L140308

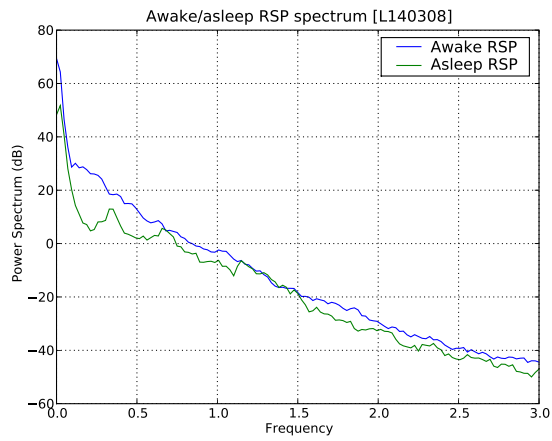
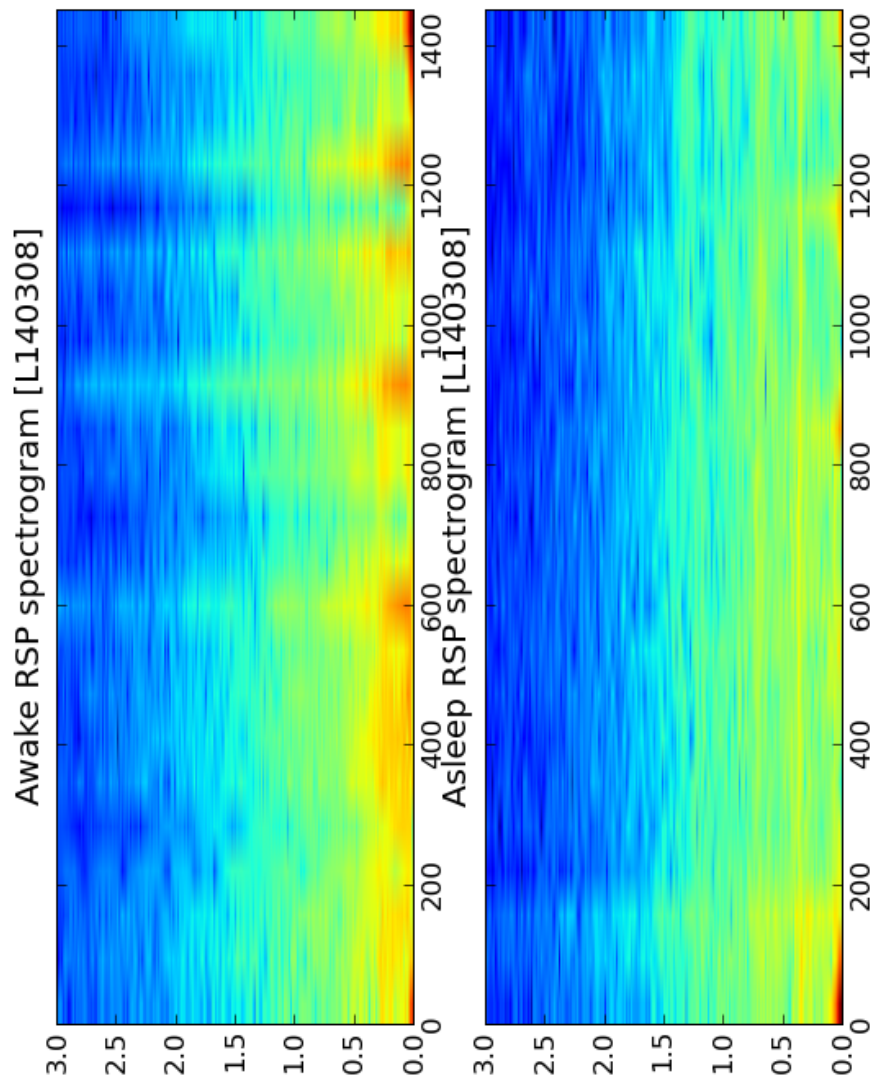


Figure 48: Time series samples of patient L140308

3.13 L150208

Comments

Propofol with curare was administered. Bad measurement quality, recommend EXCLUSION.

Awake EEG Huge amplitude artefacts. Contaminated spectrogram. Oscillatory spectrum. No defined activity anywhere.

Awake ECG Very large high frequency contamination of the waveform. Some baseline instability. Borders on unusable.

Awake Respiration Intermittent faults every 100s. Otherwise signal is smooth.

Asleep EEG Low power 11Hz activity, well-defined peak. Very low theta band 6Hz activity (?), not clear.

Asleep ECG Very clean bipolar R peak signal.

Asleep Respiration Bad waveform, contamination with low amplitude spikes. Sharp multiple peaks. High amplitude variation between neighboring peaks.

Plots

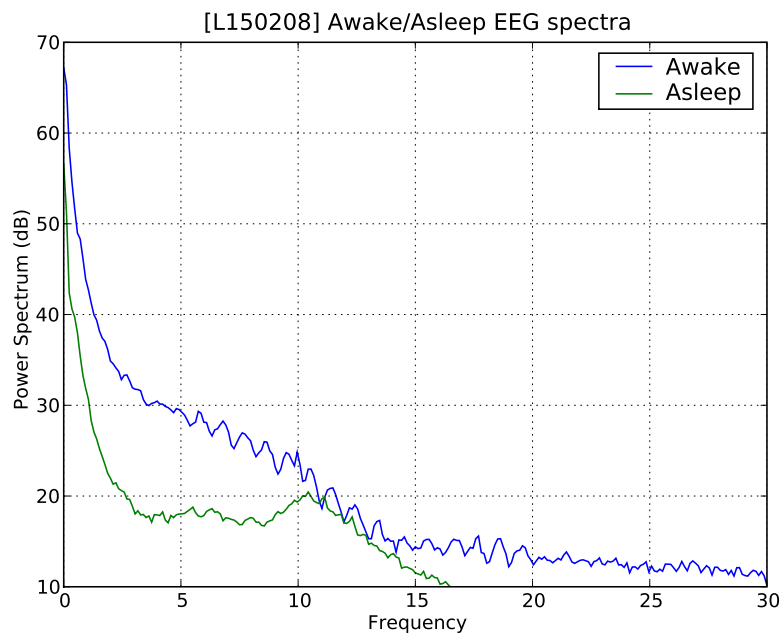


Figure 49: EEG Spectrum of patient L150208

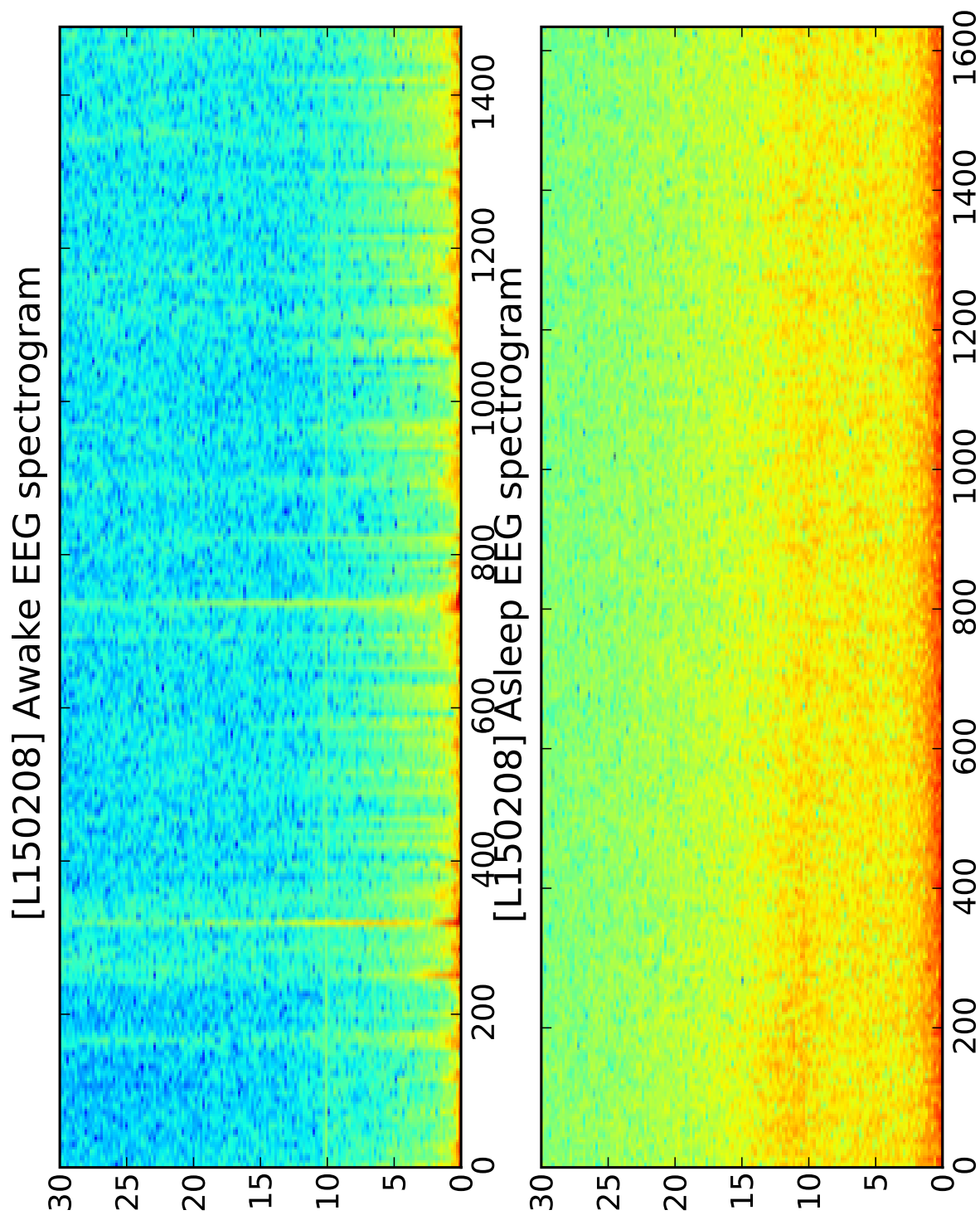


Figure 50: EEG Spectrogram of patient L150208

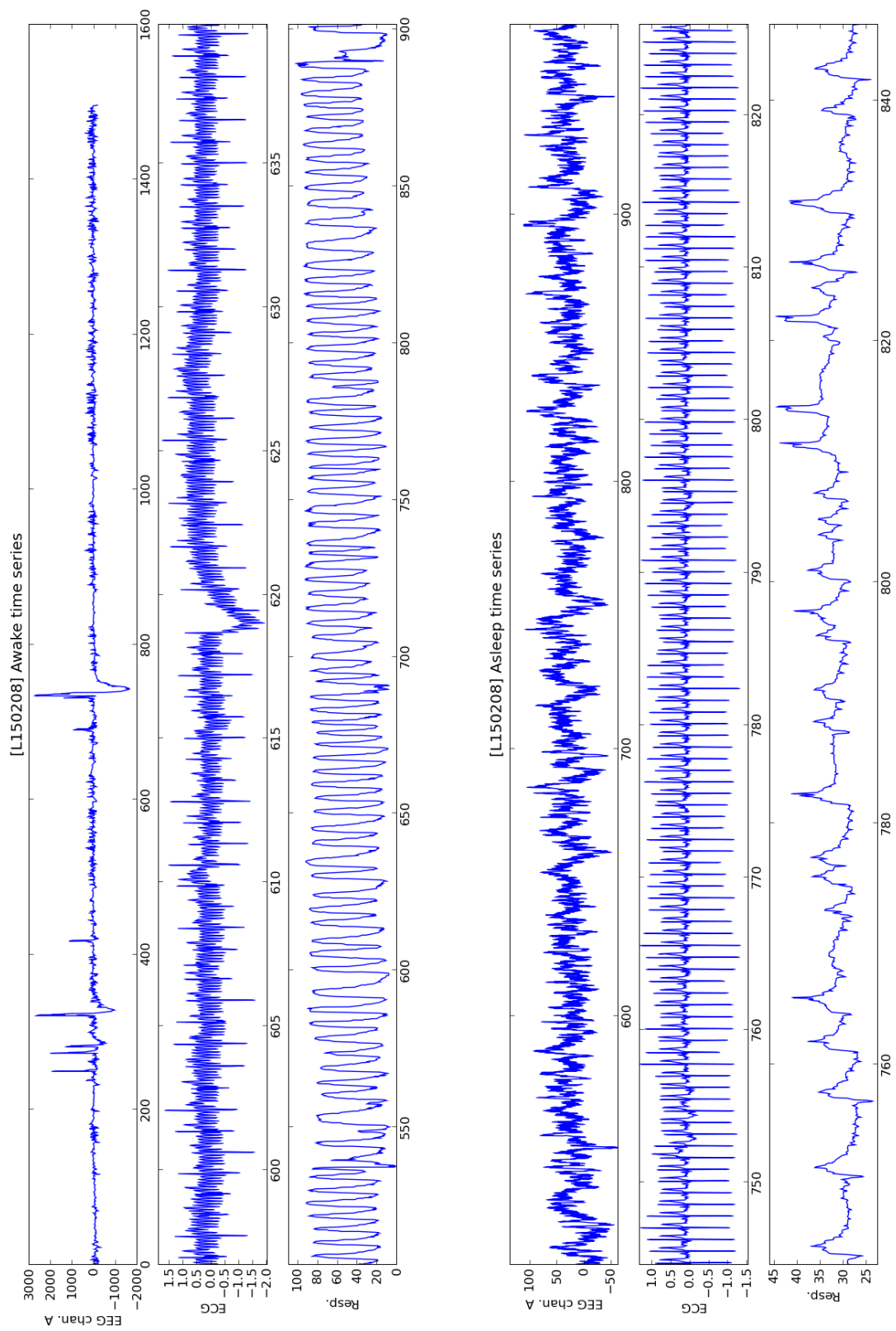


Figure 51: Time series samples of patient L150208

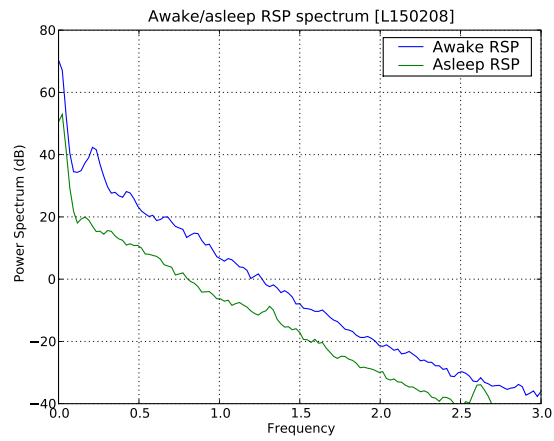
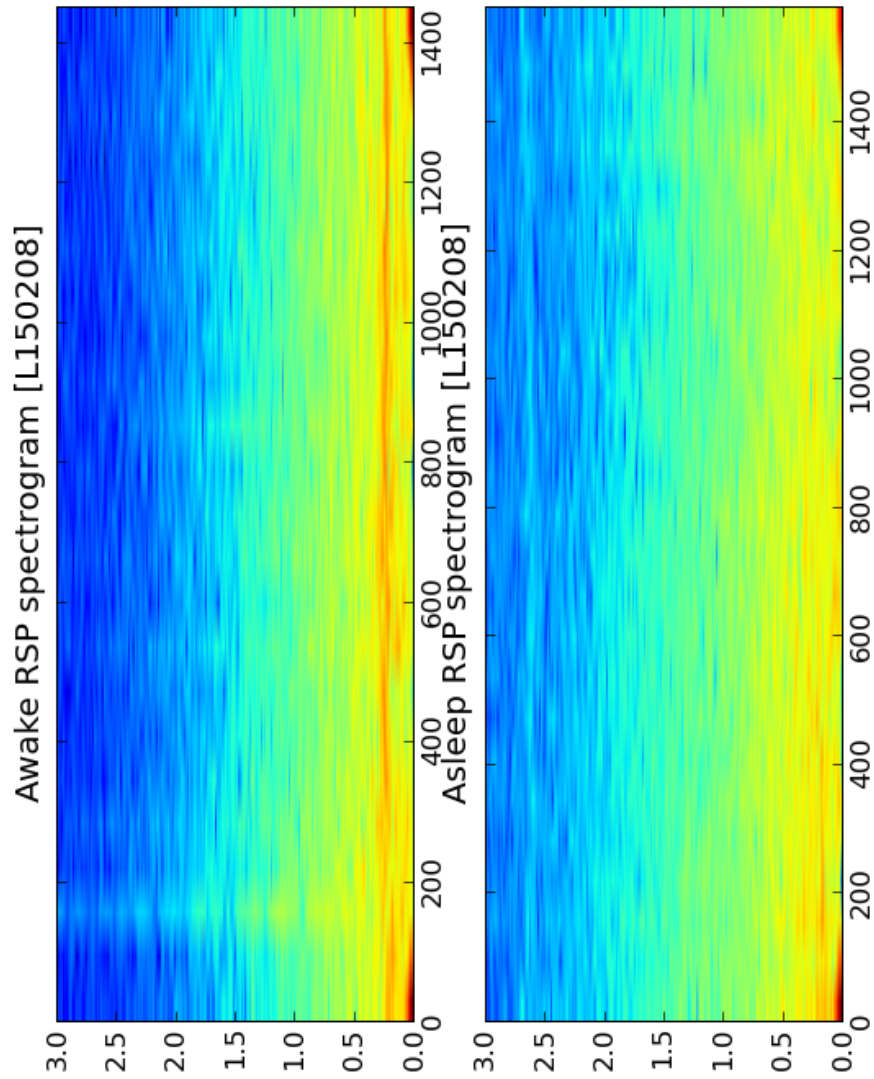


Figure 52: Time series samples of patient L150208

3.14 L160508

Comments

Propofol with curare was administered.

Awake EEG Very high amplitude artefacts (spikes) about 200s apart. Spectrogram contaminated. No well-defined activity present.

Awake ECG Good quality signal, some baseline and amplitude variation.

Awake Respiration Strong baseline shift at 230s. Spiky waveform, reasonably stable amplitude.

Asleep EEG Strong 12Hz activity, well-defined peak. Might have be some very low power theta 6Hz activity.

Asleep ECG Good signal, some baseline variation.

Asleep Respiration Passable signal quality, non-smooth valleys, sharp peaks, some irregularities (e.g. 600s).

Plots

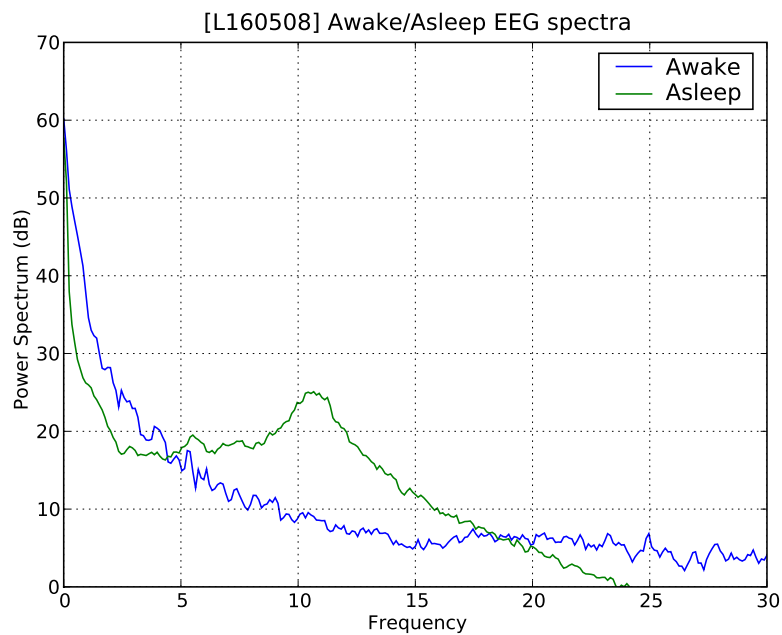


Figure 53: EEG Spectrum of patient L160508

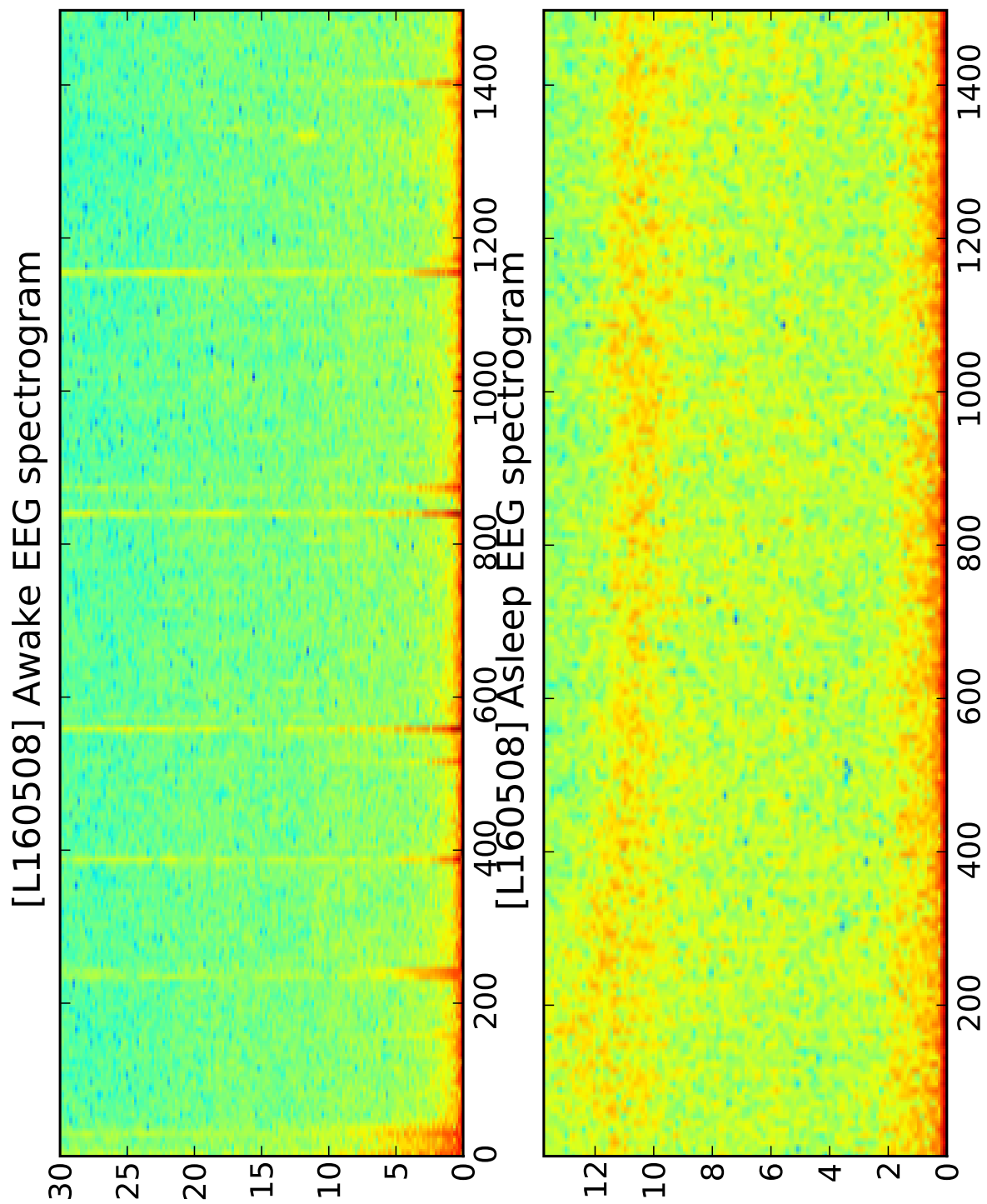


Figure 54: EEG Spectrogram of patient L160508

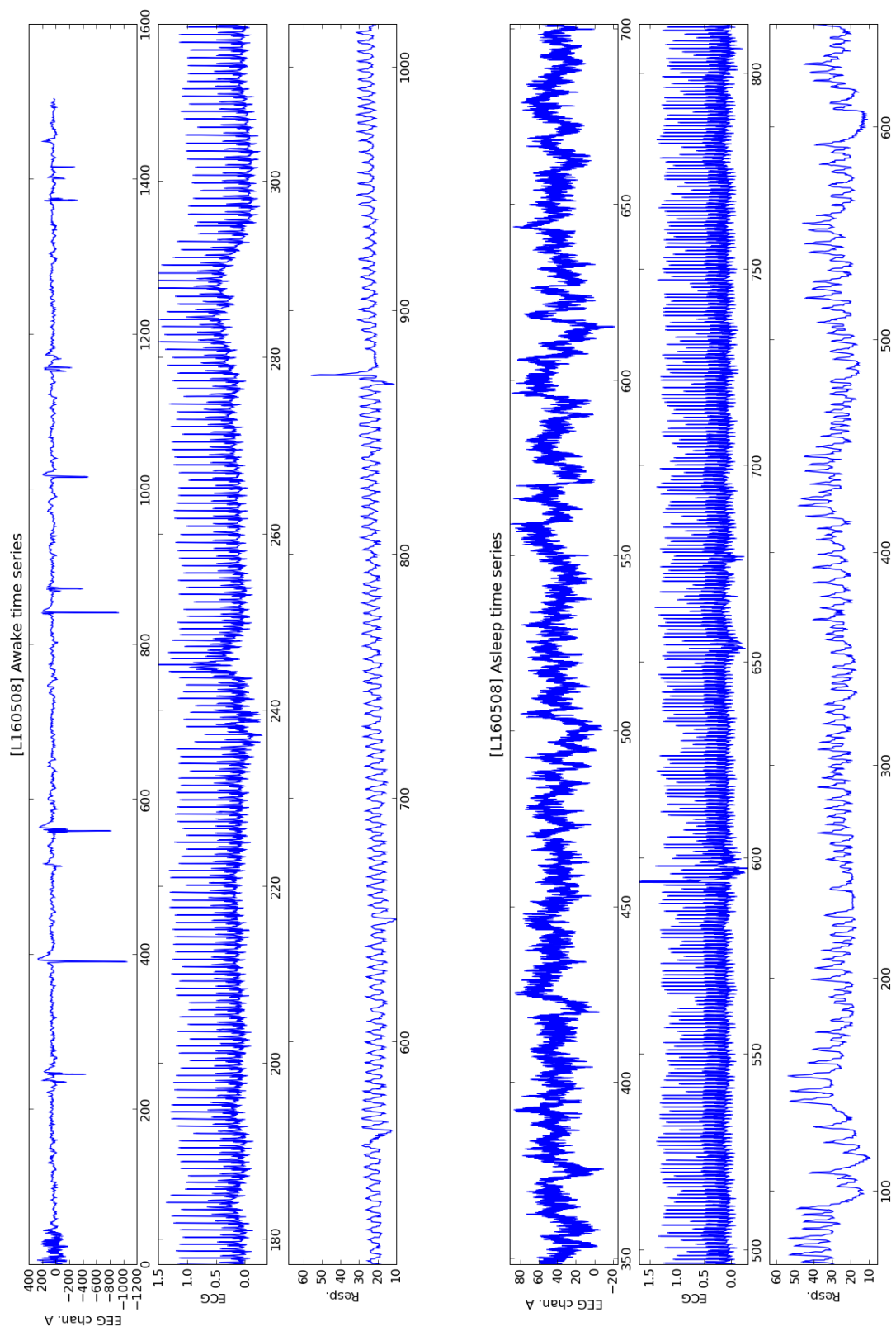


Figure 55: Time series samples of patient L160508

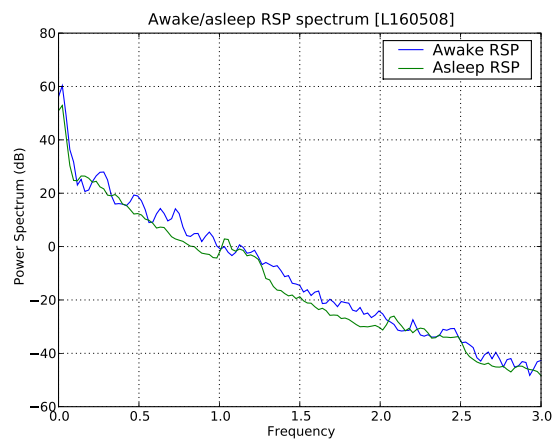
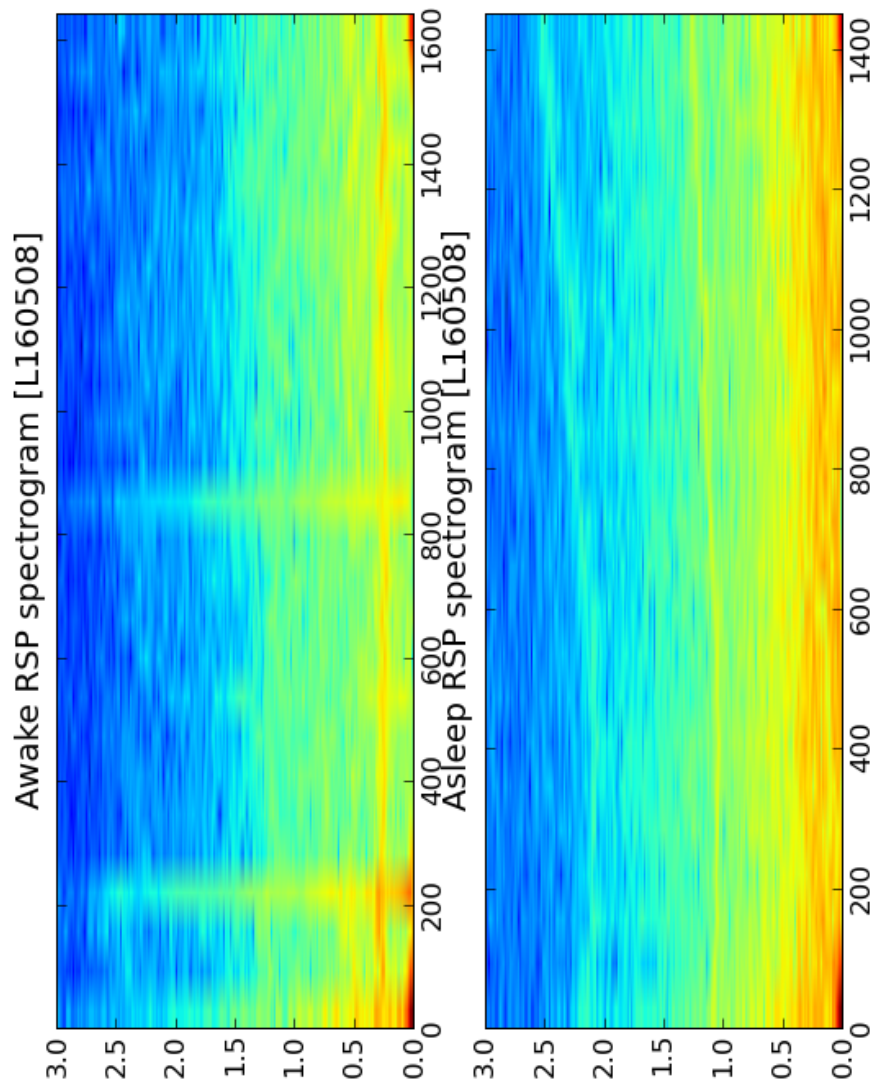


Figure 56: Time series samples of patient L160508

3.15 L181207

Comments

Sevoflurane with curare was administered. Respiration in asleep state is not good, peak positions may be unreliable.

Awake EEG Reasonable waveform. Diffuse low power 7-8Hz theta band activity, better visibility in spectrogram.

Awake ECG Stable baseline and amplitude. Good signal.

Awake Respiration Some high amplitude spikes. Some irregularities (815s) and multiple spikes (650s).

Asleep EEG Well-defined 10Hz alpha band activity. Clean signal.

Asleep ECG Stable baseline, clean signal.

Asleep Respiration Two major baseline variations (300s, 900s). HF noise contamination, especially baseline (valleys). May move peak positions. Signal is not clean.

Plots

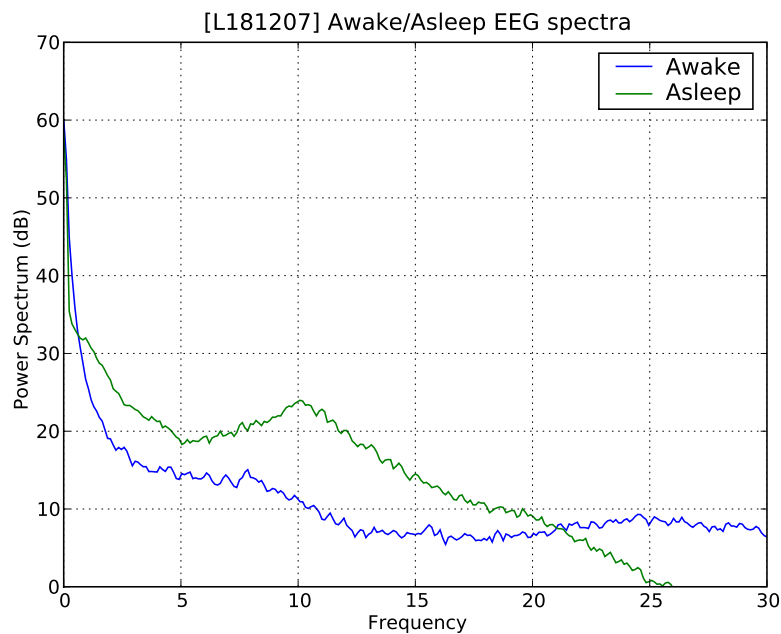


Figure 57: EEG Spectrum of patient L181207

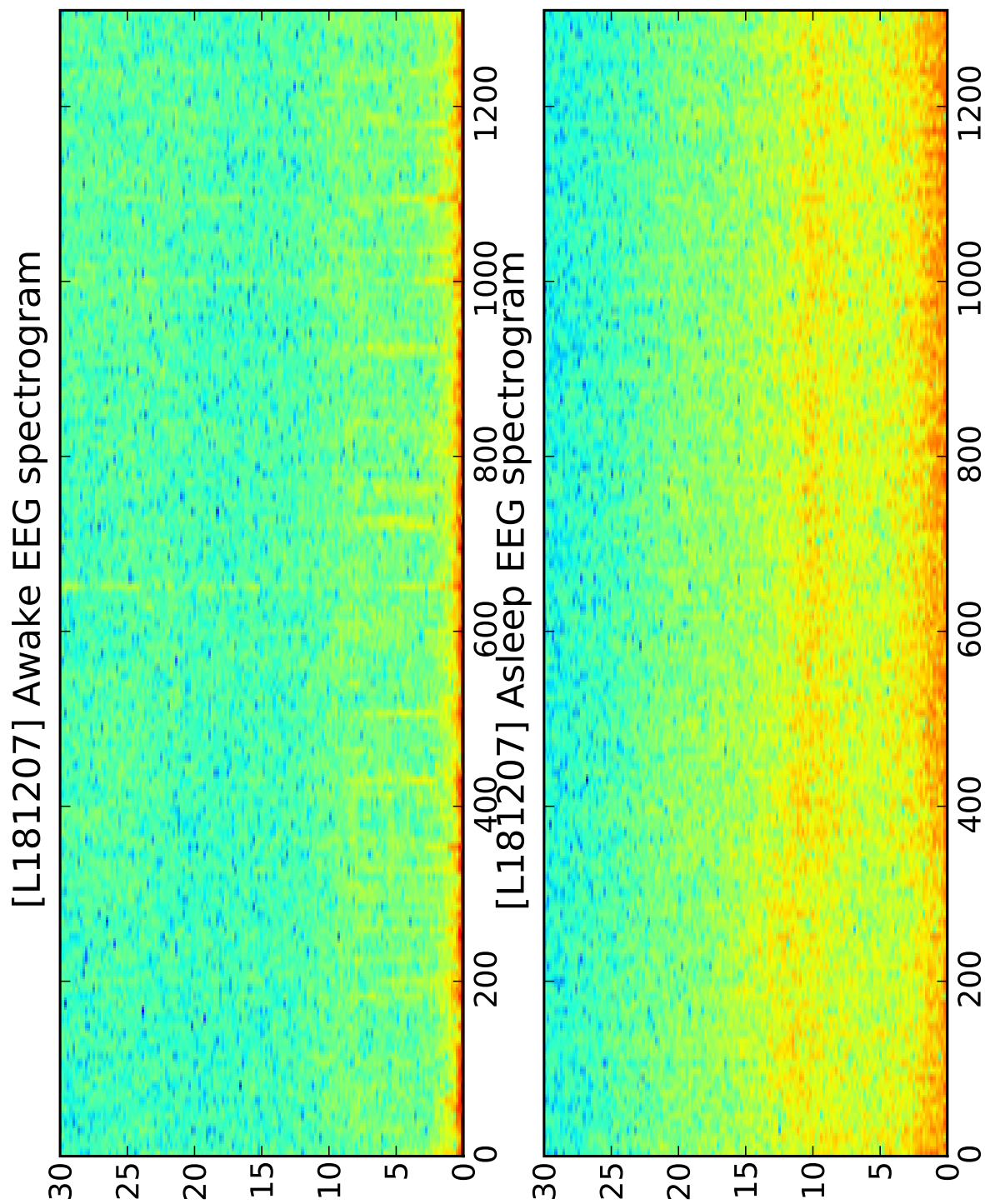


Figure 58: EEG Spectrogram of patient L181207

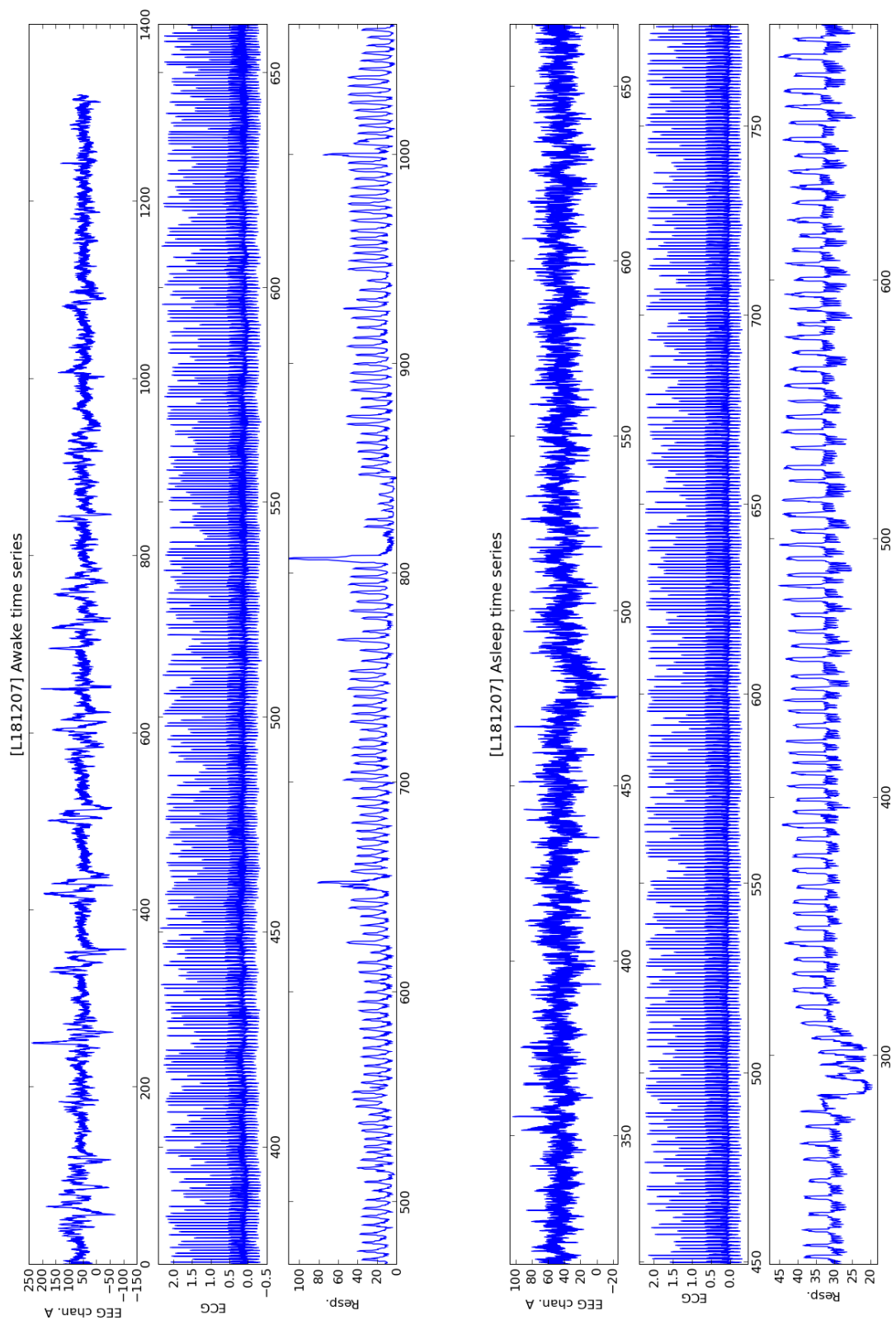


Figure 59: Time series samples of patient L181207

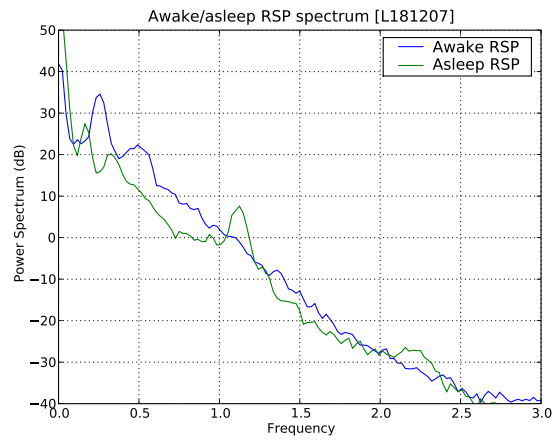
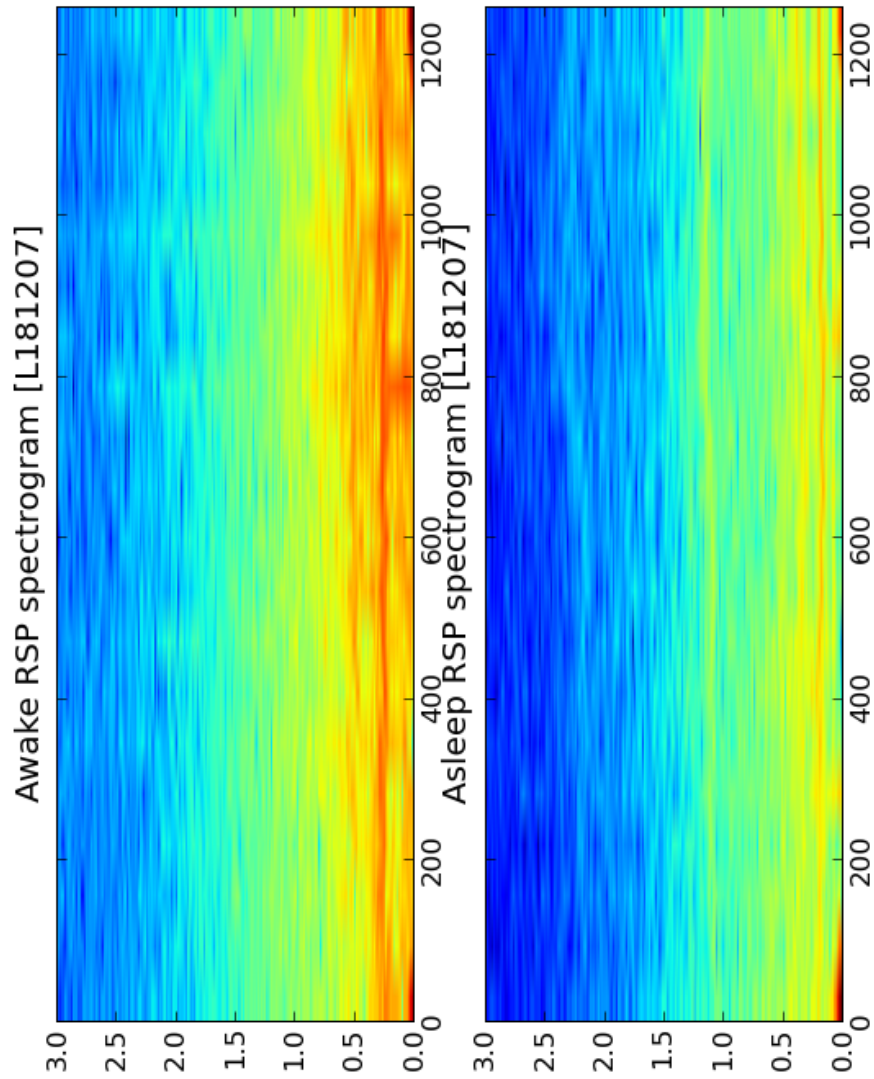


Figure 60: Time series samples of patient L181207

3.16 L200608

Comments

Propofol was administered. May have unreliable peaks in respiration in both states.

Awake EEG Clean waveform, low power activity in alpha band 11Hz.

Awake ECG Clean, stable.

Awake Respiration Unstable amplitude. Sharp peaks. Some irregularities. Passable quality. Baseline locally unstable.

Asleep EEG Start exhibits trend. Strong 12Hz alpha band activity. Otherwise clean.

Asleep ECG Stable, clean.

Asleep Respiration From 1000s stable signal, noise contamination. Sharp peaks with multiple tips, peak positions may be unreliable.

Plots

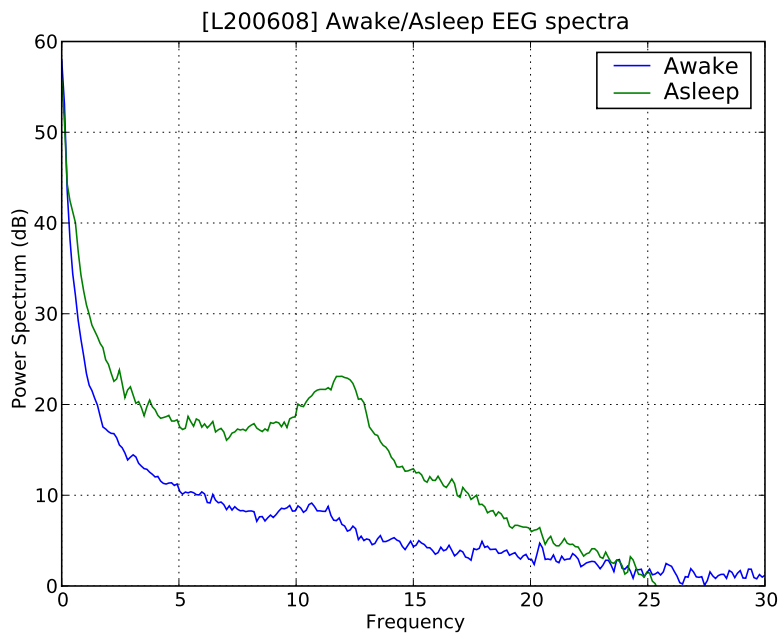


Figure 61: EEG Spectrum of patient L200608

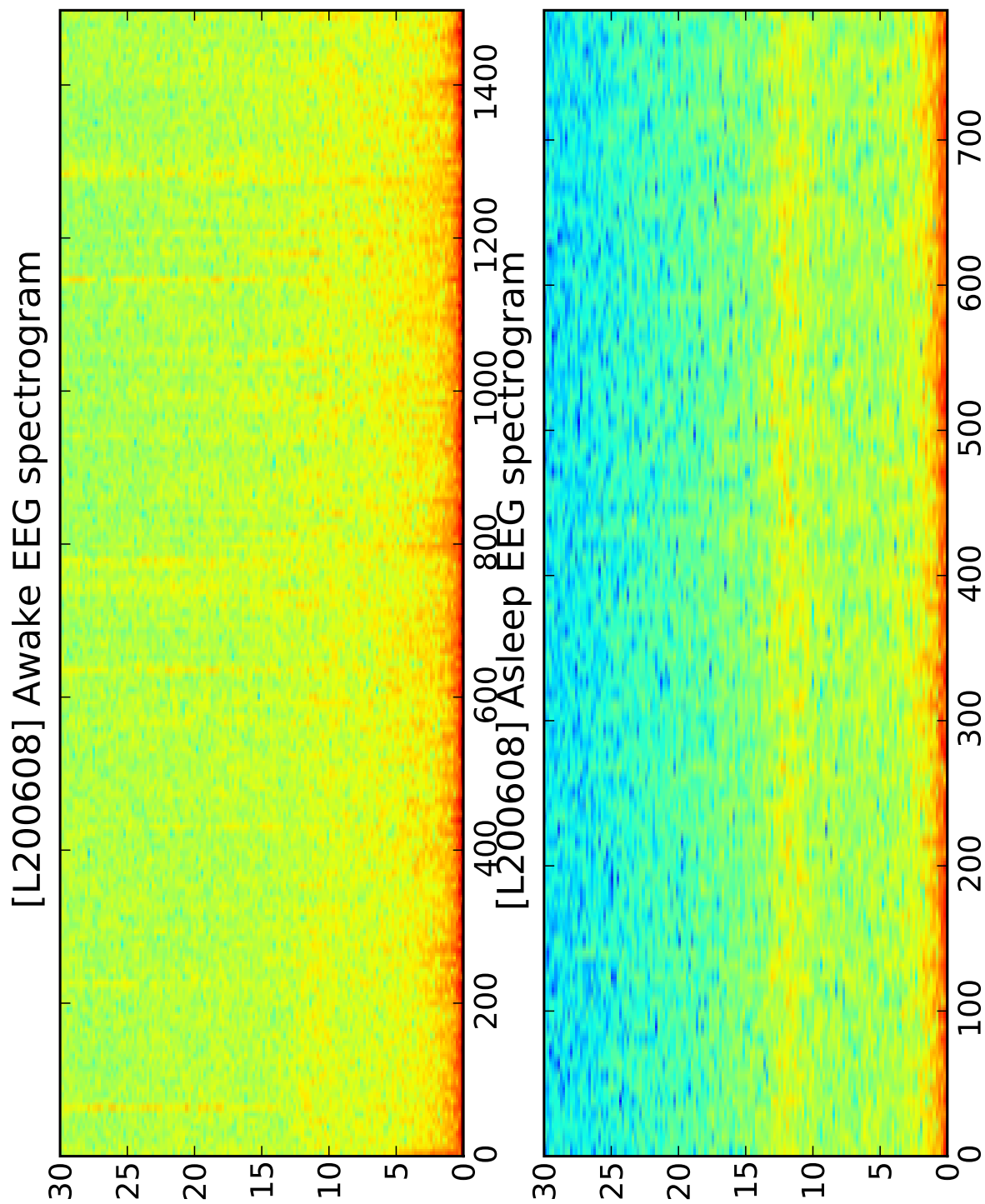


Figure 62: EEG Spectrogram of patient L200608

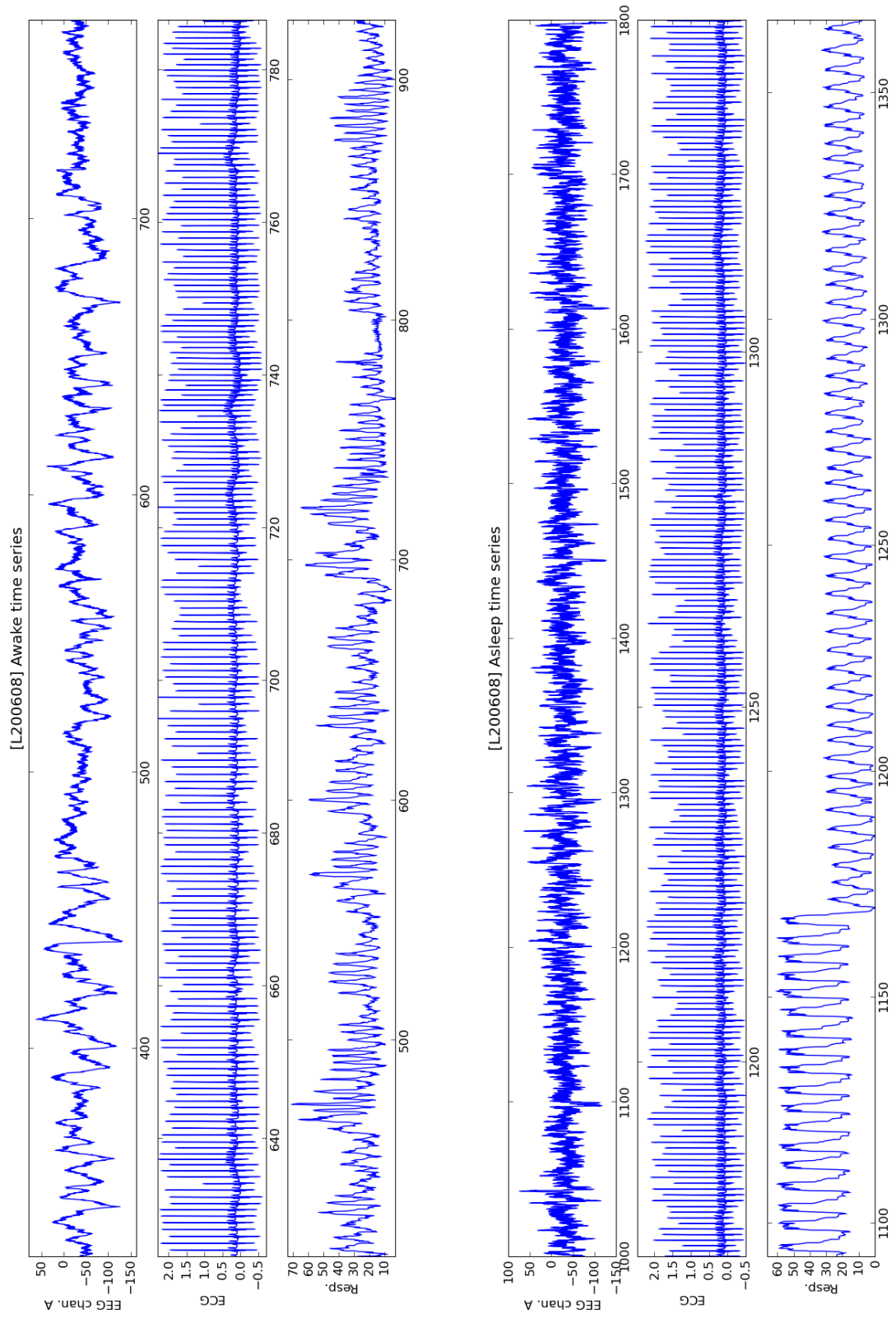


Figure 63: Time series samples of patient L200608

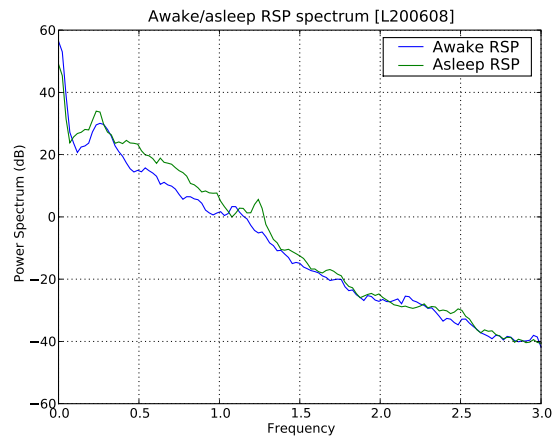
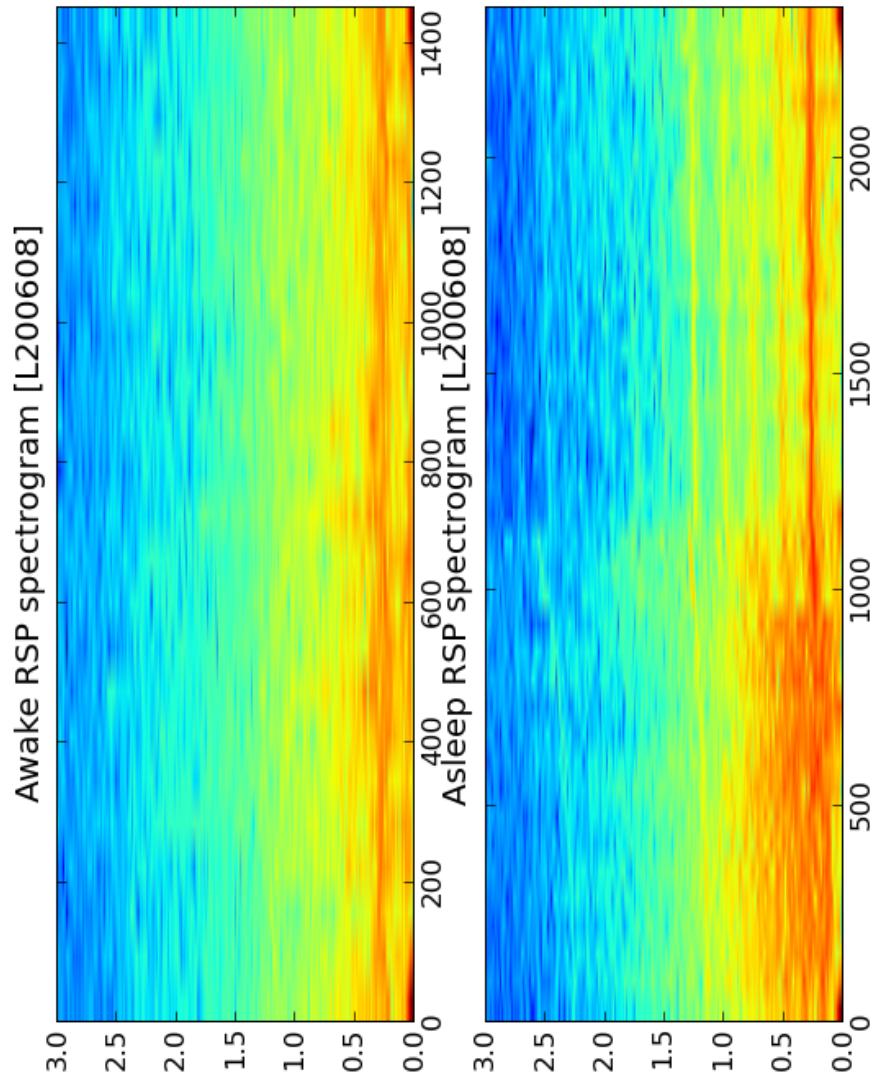


Figure 64: Time series samples of patient L200608

3.17 L220408

Comments

Sevoflurane was administered. Bad quality of ECG measurements.

Awake EEG May have theta band 5Hz very low power activity (?). Higher amplitude spike contamination of signal.

Awake ECG Clean, stable baseline, some high amplitude artefacts (1230s, 1280s).

Awake Respiration Sharp waveform. Intermittent faults, signal losses, unstable baseline. Strong amplitude variations. Some regions useless.

Asleep EEG Well-defined alpha band 10Hz activity. Weak delta band 0.5 Hz activity (?), not seen in spectrogram, spectrum only.

Asleep ECG Quite a few intermittent high amplitude faults. Oscillatory activity 10Hz contaminations. R peaks still seen.

Asleep Respiration Signal excellent.

Plots

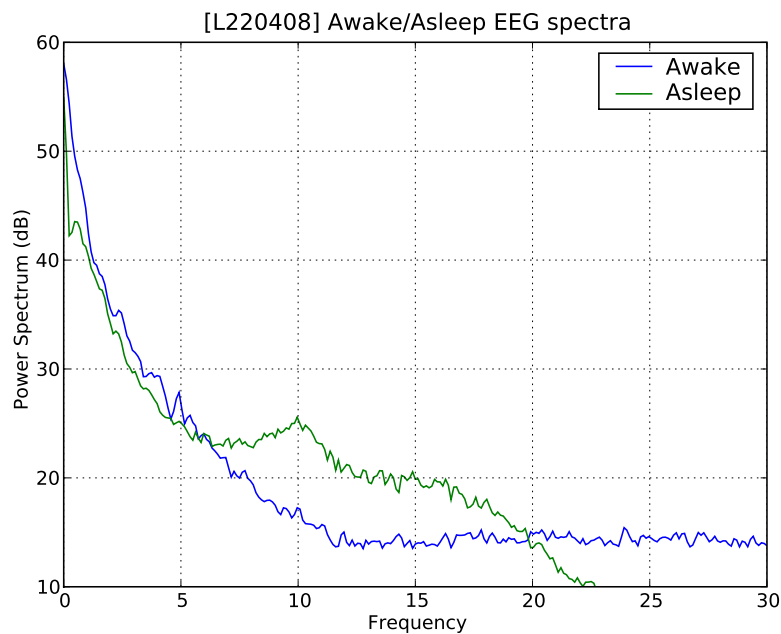


Figure 65: EEG Spectrum of patient L220408

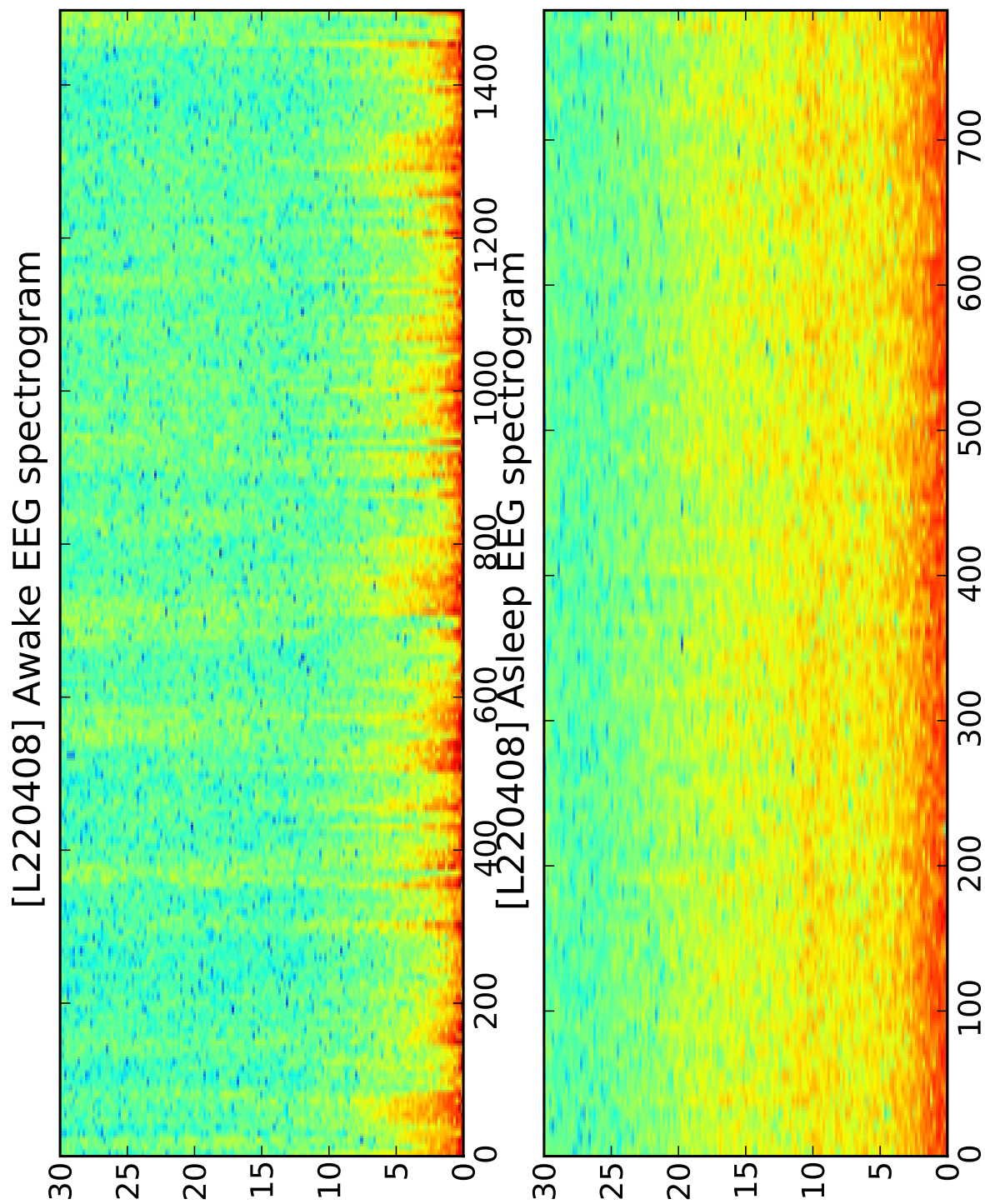


Figure 66: EEG Spectrogram of patient L220408

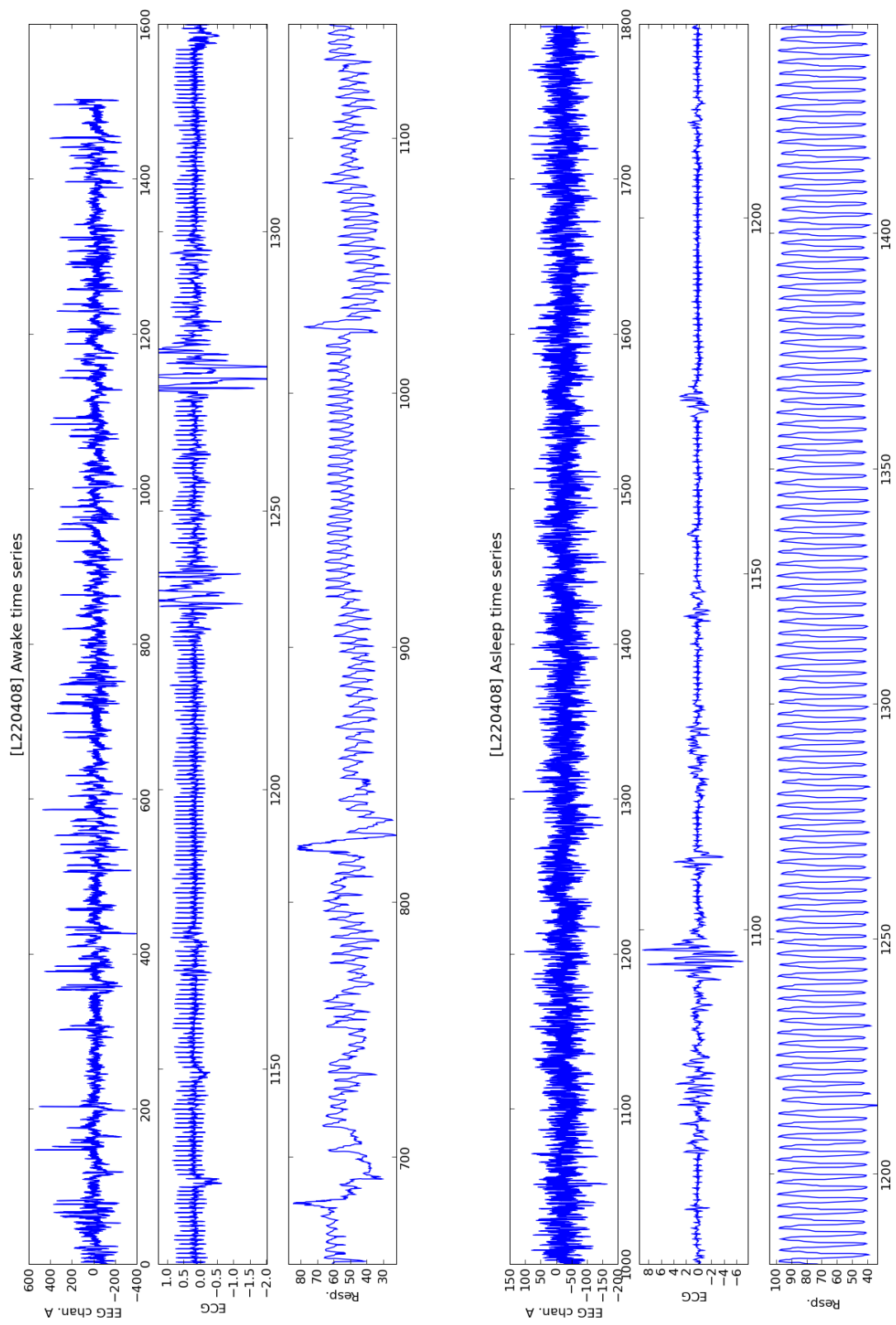


Figure 67: Time series samples of patient L220408

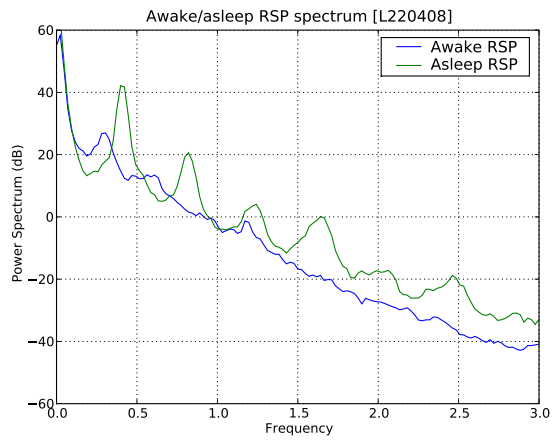
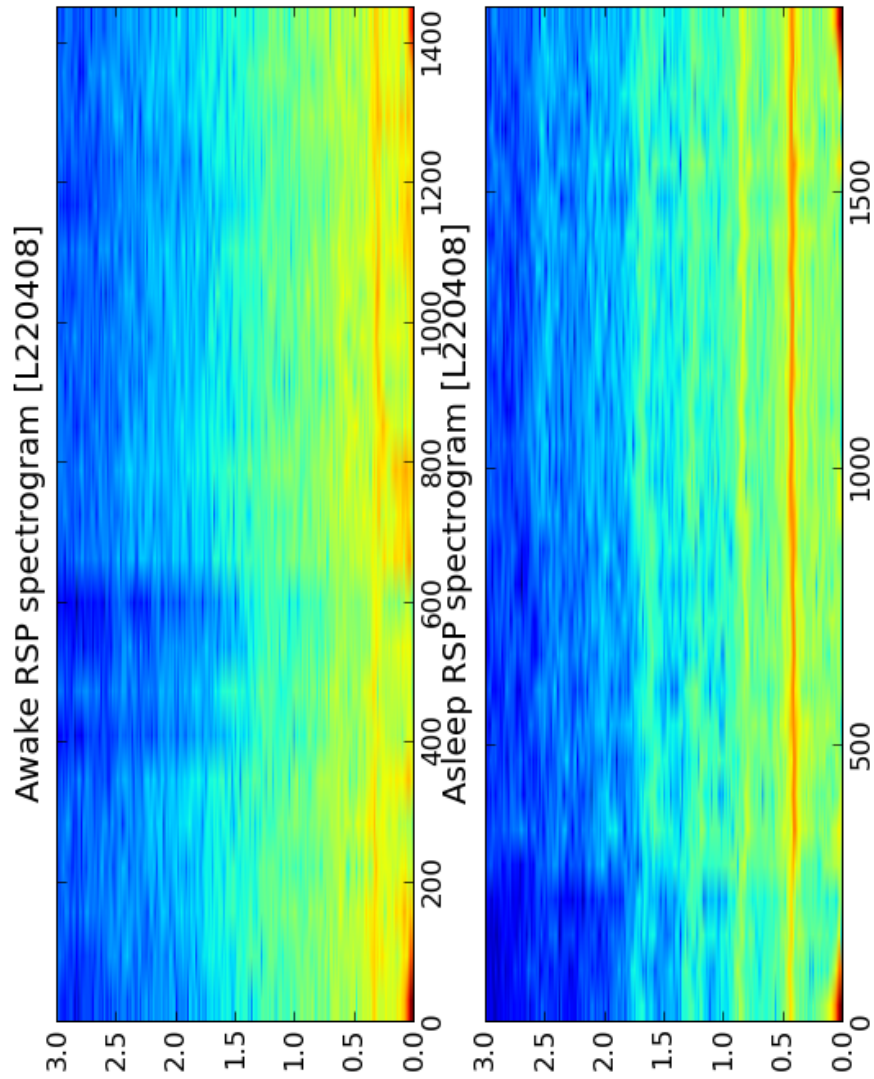


Figure 68: Time series samples of patient L220408

3.18 L240608

Comments

Propofol with curare was administered.

Awake EEG Some high amplitude spikes. Oscillatory spectrum. No defined activity.

Awake ECG Baseline variation, otherwise stable signal.

Awake Respiration Spiky irregular, asymmetric waveform, baseline variations. Some amplitude variation.

Asleep EEG Clean signal. Has 12-13Hz alpha band activity. Delta activity present at 0.9, 1.9, 2.9 Hz. Suspected non-physiological origin. Very stable frequency and low spread.

Asleep ECG Clean signal, stable.

Asleep Respiration Spiky waveform, some irregularities. Some amplitude variations and local baseline instability.

Plots

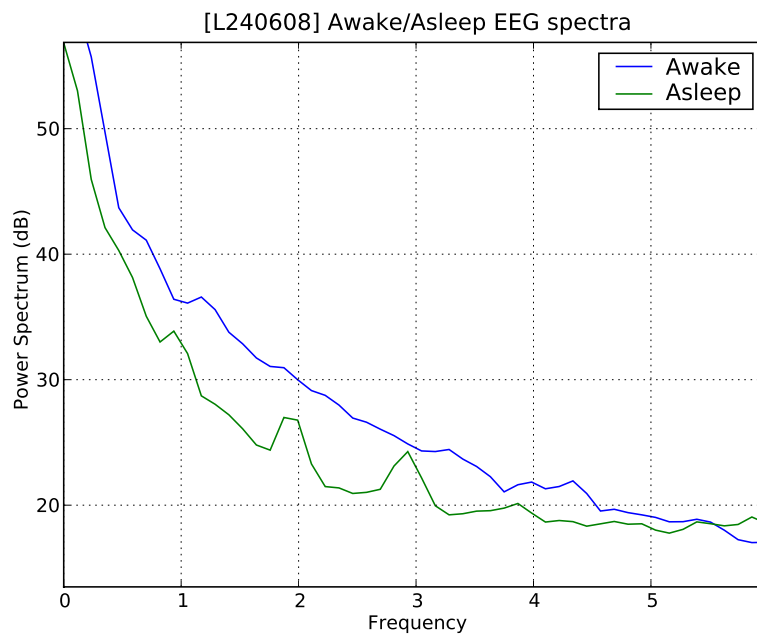


Figure 69: EEG Spectrum of patient L240608

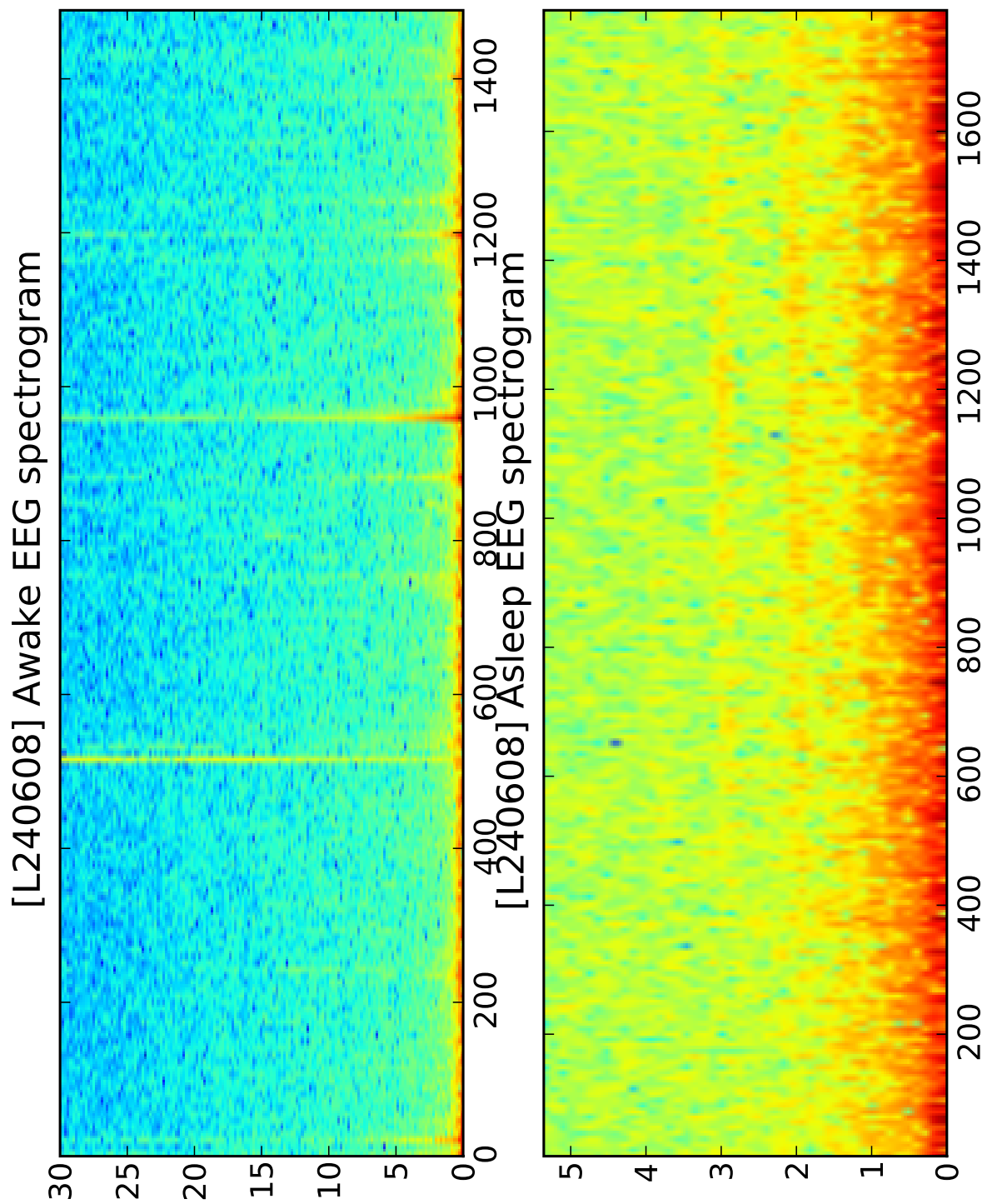


Figure 70: EEG Spectrogram of patient L240608

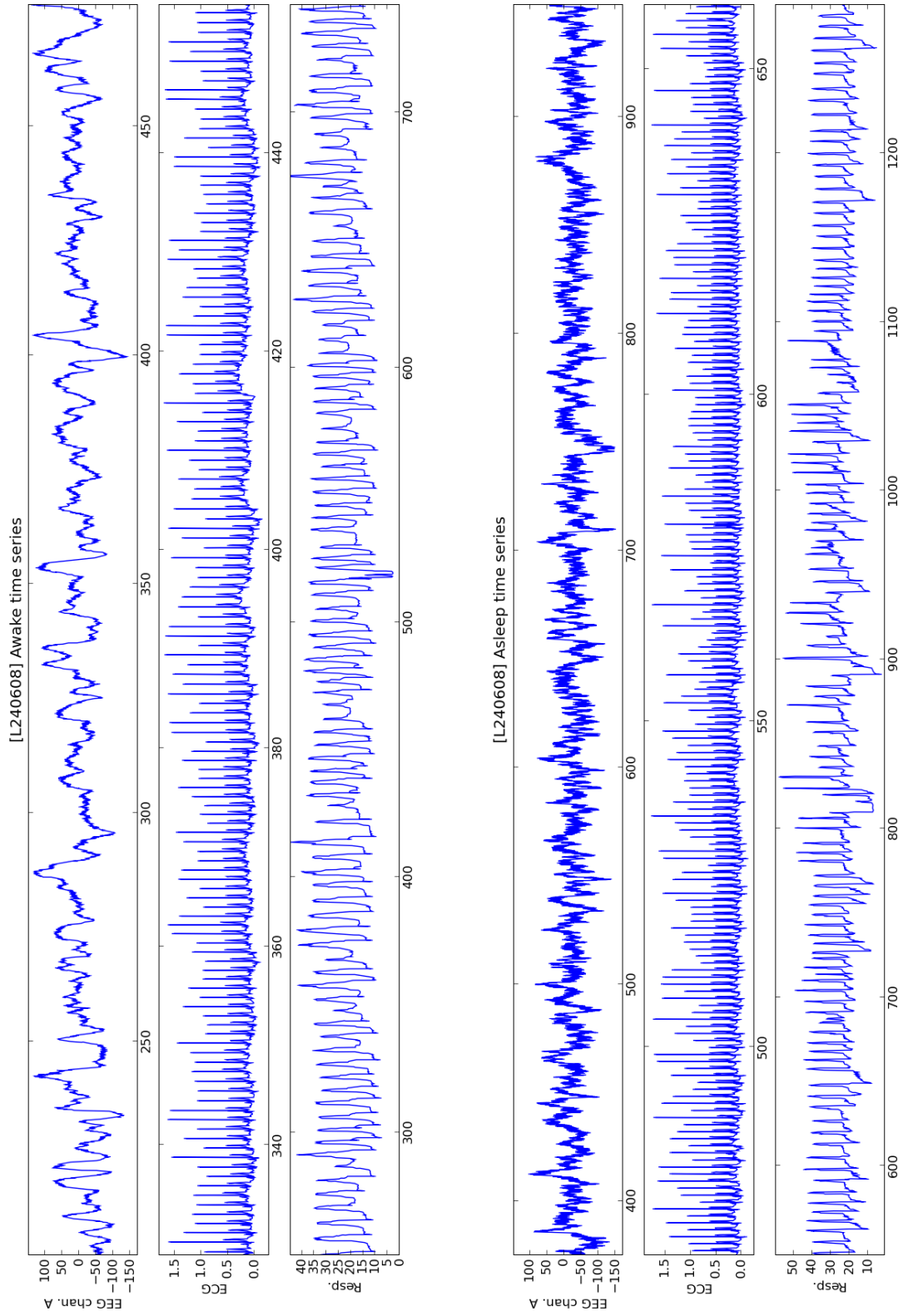


Figure 71: Time series samples of patient L240608

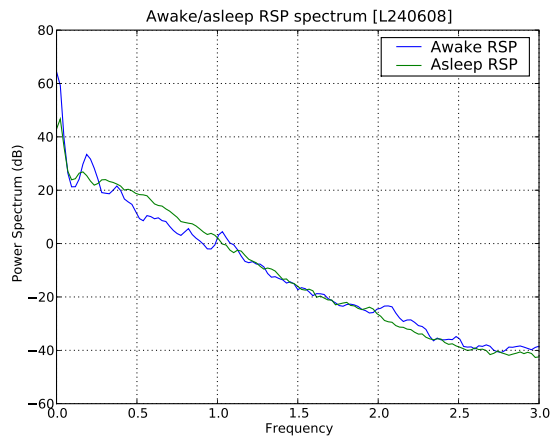
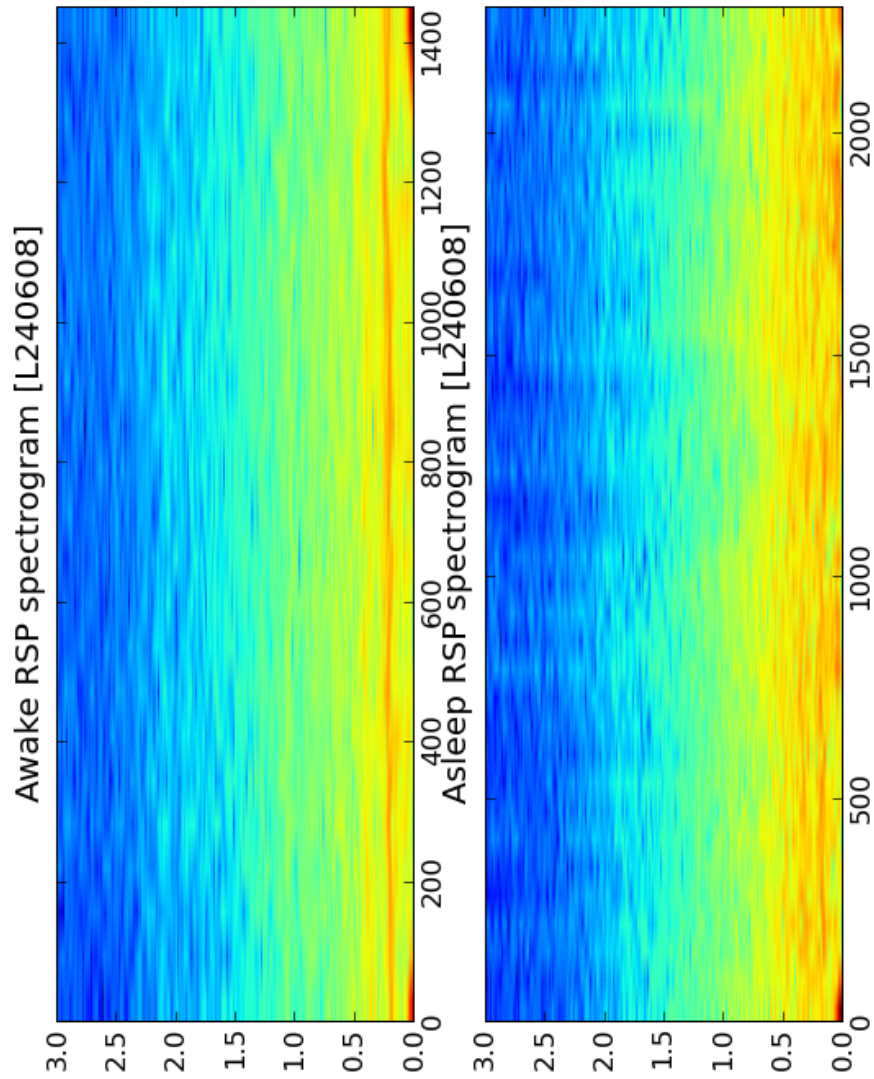


Figure 72: Time series samples of patient L240608

3.19 L290208

Comments

Propofol was administered. Awake state not well represented.

Awake EEG No defined activity. Two high amplitude spikes.

Awake ECG Some high amplitude artefacts (700s, 720s, 760s, 1400s) otherwise stable baseline and amplitude.

Awake Respiration Unstable baseline, some signal losses. Spiky asymmetric waveform, some signal losses. Bad quality.

Asleep EEG Alpha band activity 11Hz, clean signal.

Asleep ECG Stable baseline, amplitude, clean signal.

Asleep Respiration Clean signal, one baseline change at 1100s. Frequency trend at start.

Plots

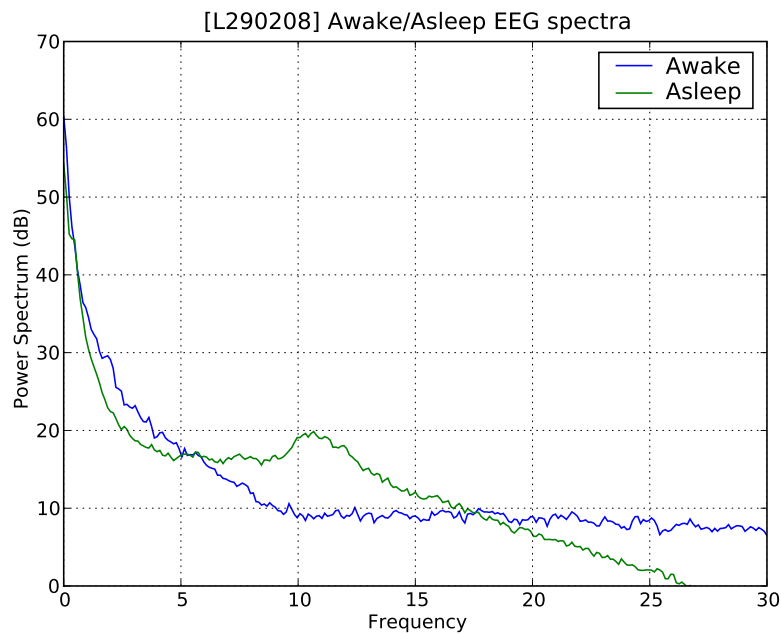


Figure 73: EEG Spectrum of patient L290208

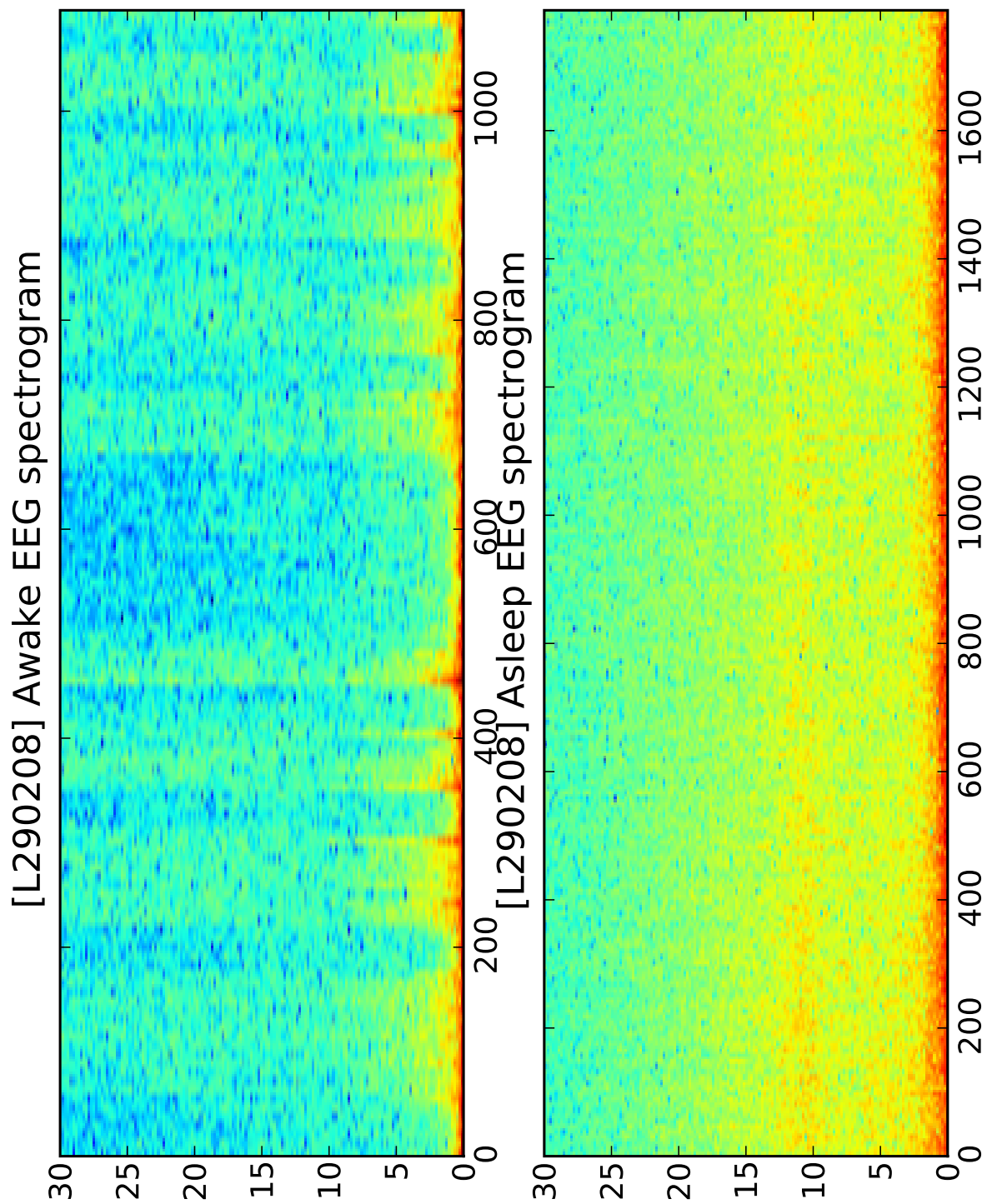


Figure 74: EEG Spectrogram of patient L290208

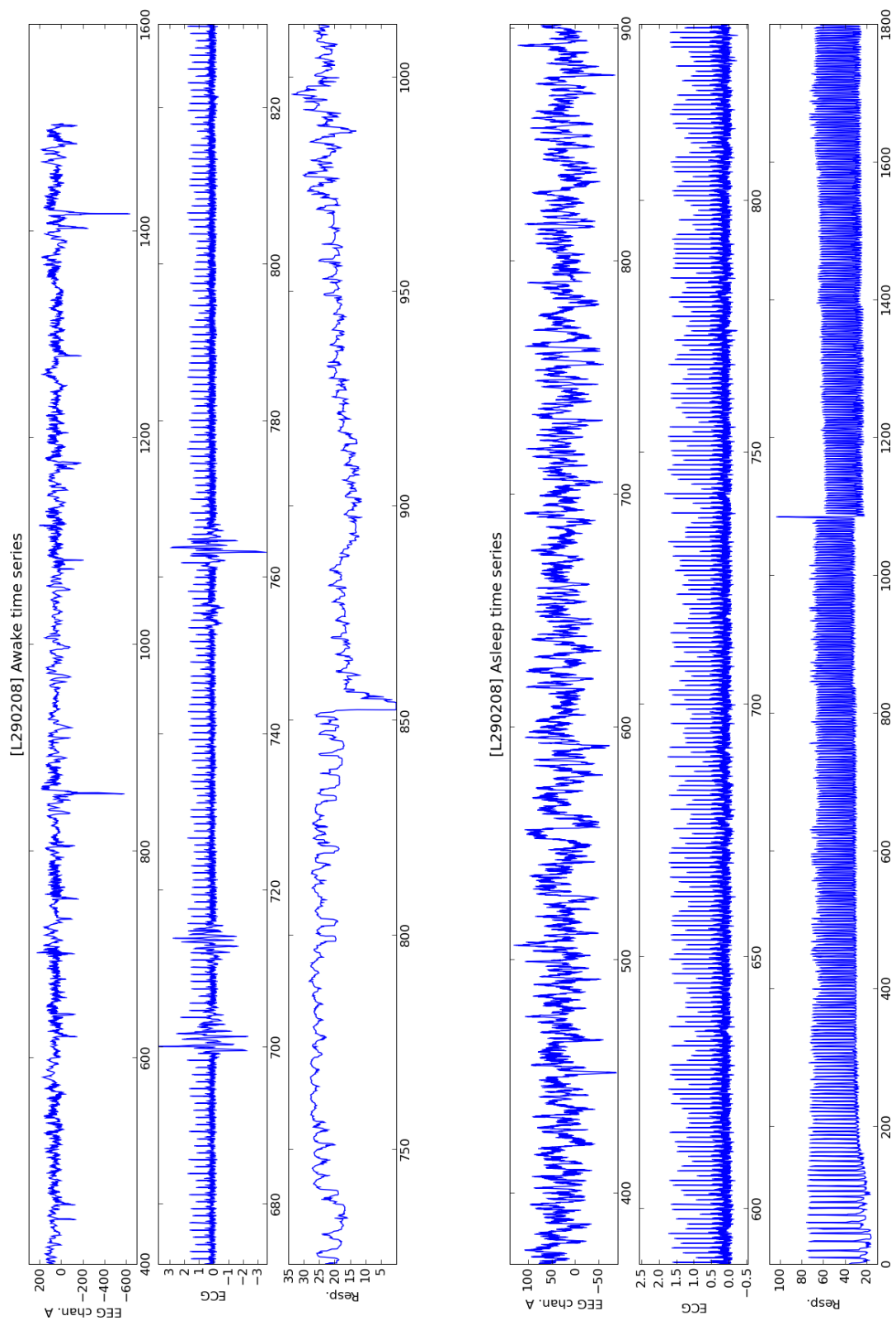


Figure 75: Time series samples of patient L290208

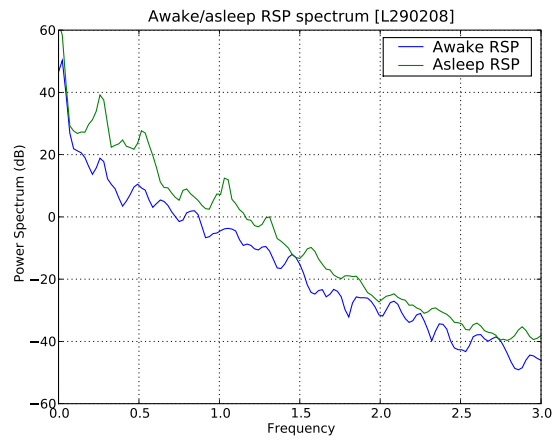
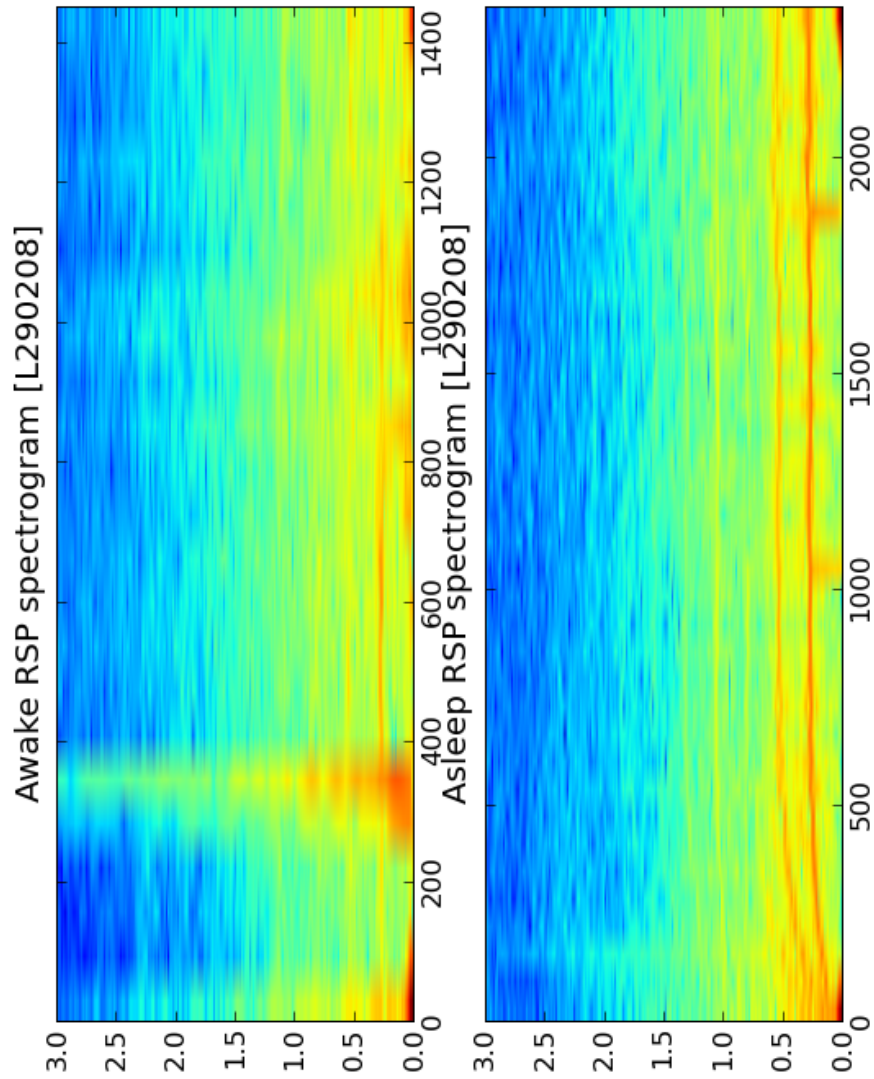


Figure 76: Time series samples of patient L290208

3.20 L290507

Comments

Propofol was administered. Exactly reverse activity in EEG bands than other patients. Has suspect low frequency delta activity in awake state.

Awake EEG Strong activity in theta/alpha band 8Hz, sharper peak. Low power activity in delta band (0.9, 1.9, 2.9Hz). Spectrogram shows almost exact stable rhythm throughout recording - suspect non-physiological origin.

Awake ECG Baseline variations, bipolar R wave, good quality.

Awake Respiration Good waveform, some irregularities, missed breathing (?). Valleys contaminated with noise.

Asleep EEG No well-defined activity.

Asleep ECG Strong bipolar R peaks, stable baseline.

Asleep Respiration Spiky waveform, contamination of valleys with some noise, R-peak positions ??

Plots

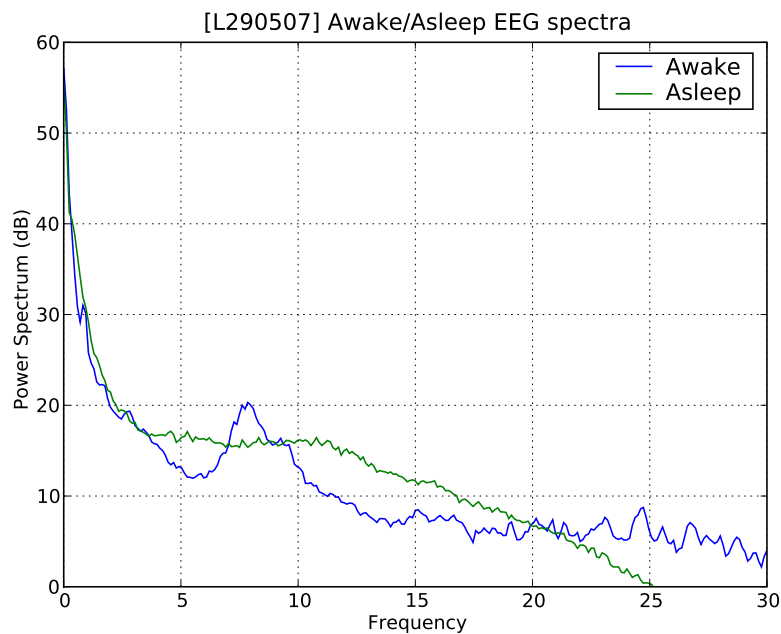


Figure 77: EEG Spectrum of patient L290507

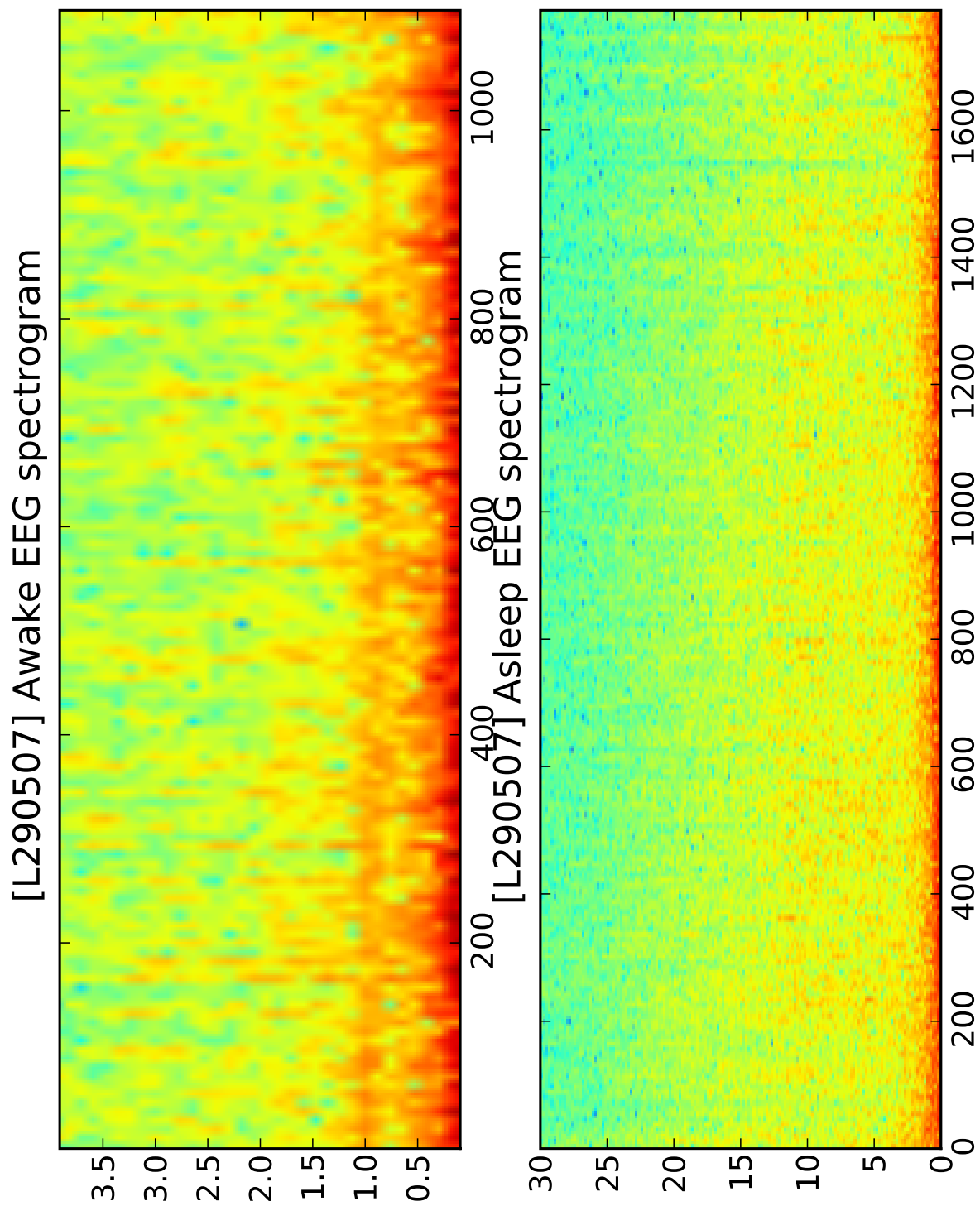


Figure 78: EEG Spectrogram of patient L290507

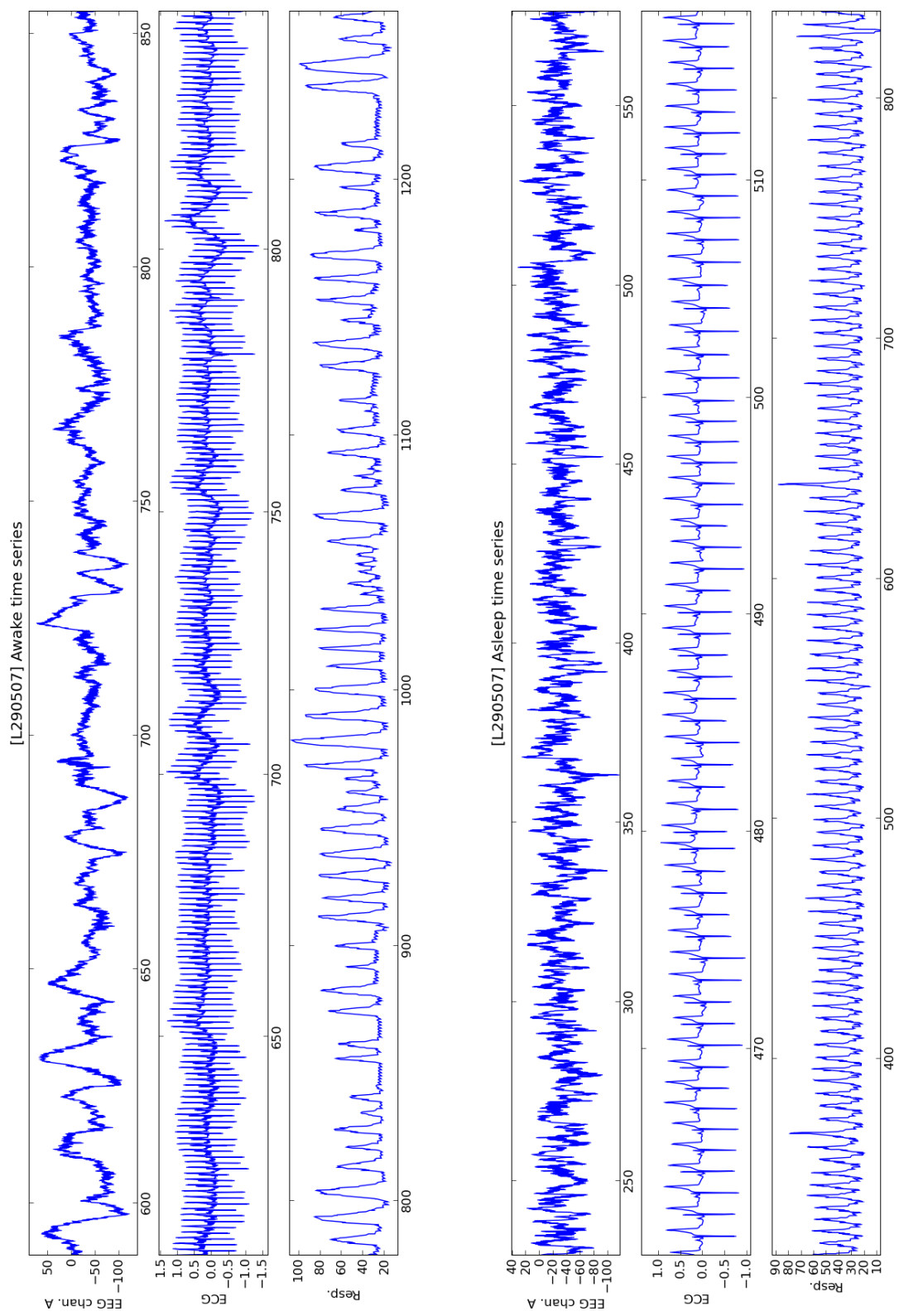


Figure 79: Time series samples of patient L290507

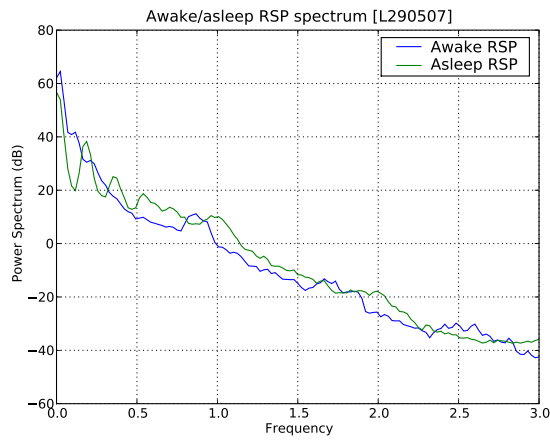
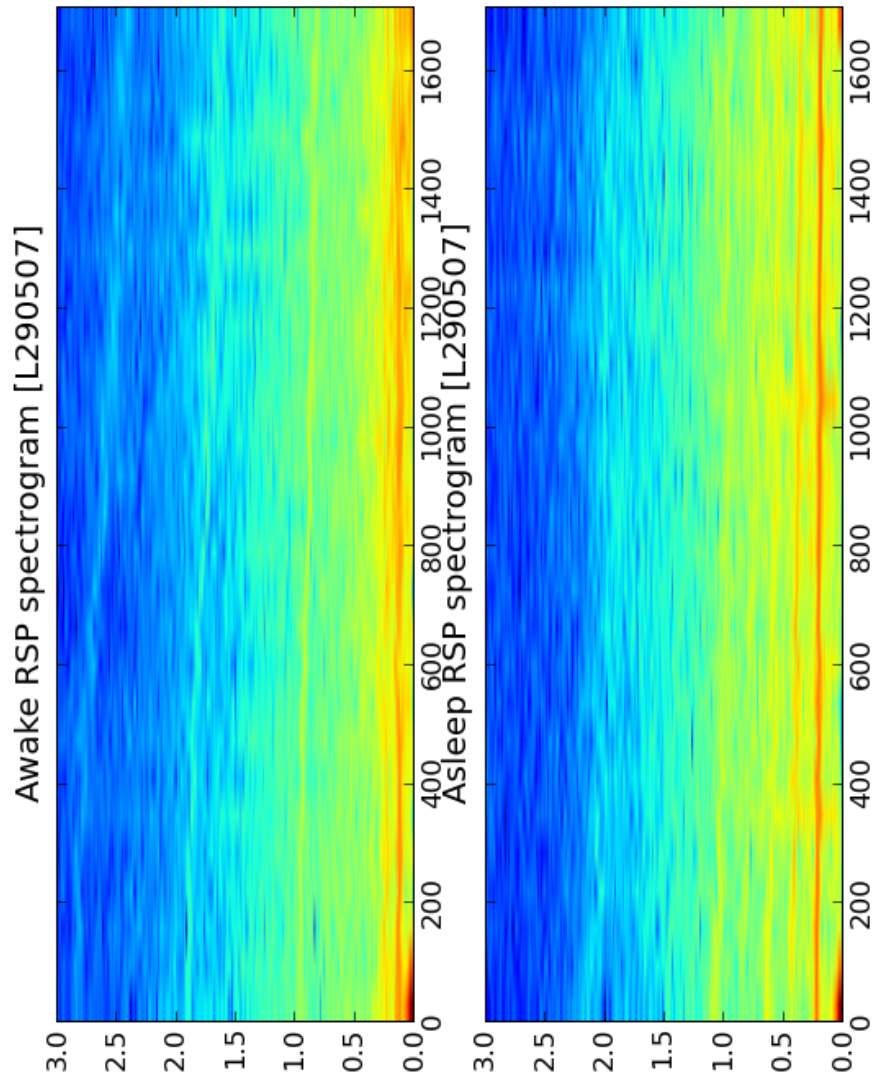


Figure 80: Time series samples of patient L290507

3.21 L290508

Comments

Sevoflurane was administered. Very low EEG amplitudes in asleep state. Spectra of EEG signals are almost straight-line. Signal seems unusable.

Awake EEG Spectrum shows no defined activity and power increases toward 30Hz.

Awake ECG Baseline instability, good signal.

Awake Respiration Respiration signal has good waveform, overall good quality. Some noise in valleys.

Asleep EEG Very non-standard spectrum. Some large amplitude spikes in signal. Seen in spectrogram. Waveform is of very low amplitude.

Asleep ECG Stable baseline.

Asleep Respiration Very nice and stable waveform. One baseline change at 1030s.

Plots

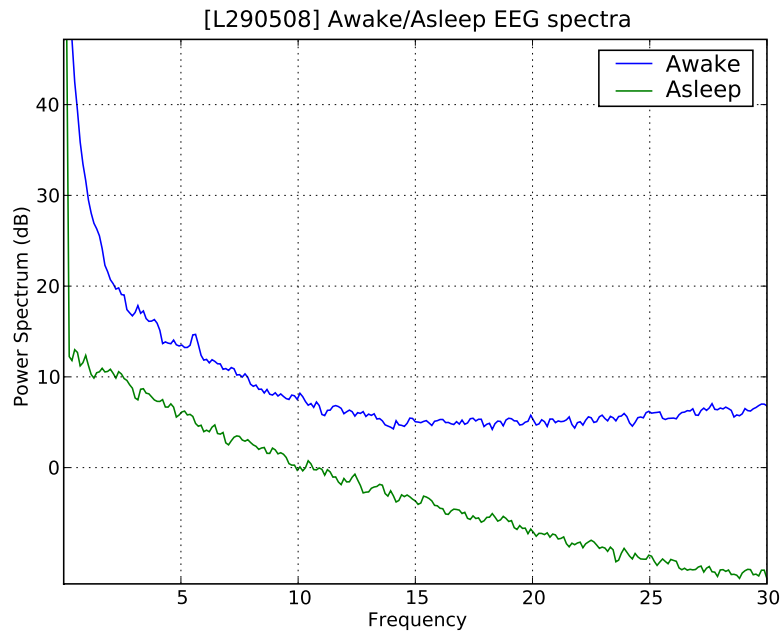


Figure 81: EEG Spectrum of patient L290508

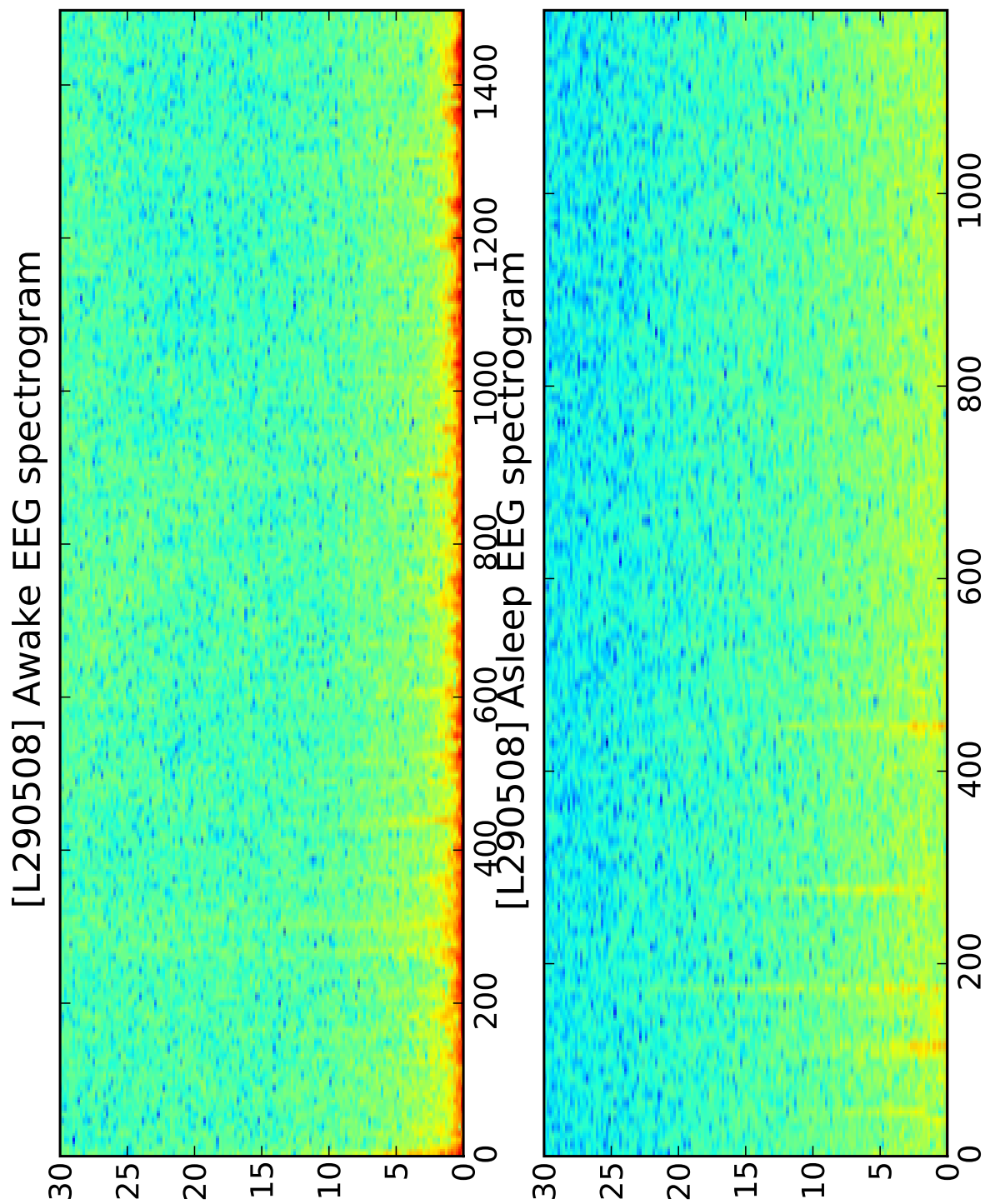


Figure 82: EEG Spectrogram of patient L290508

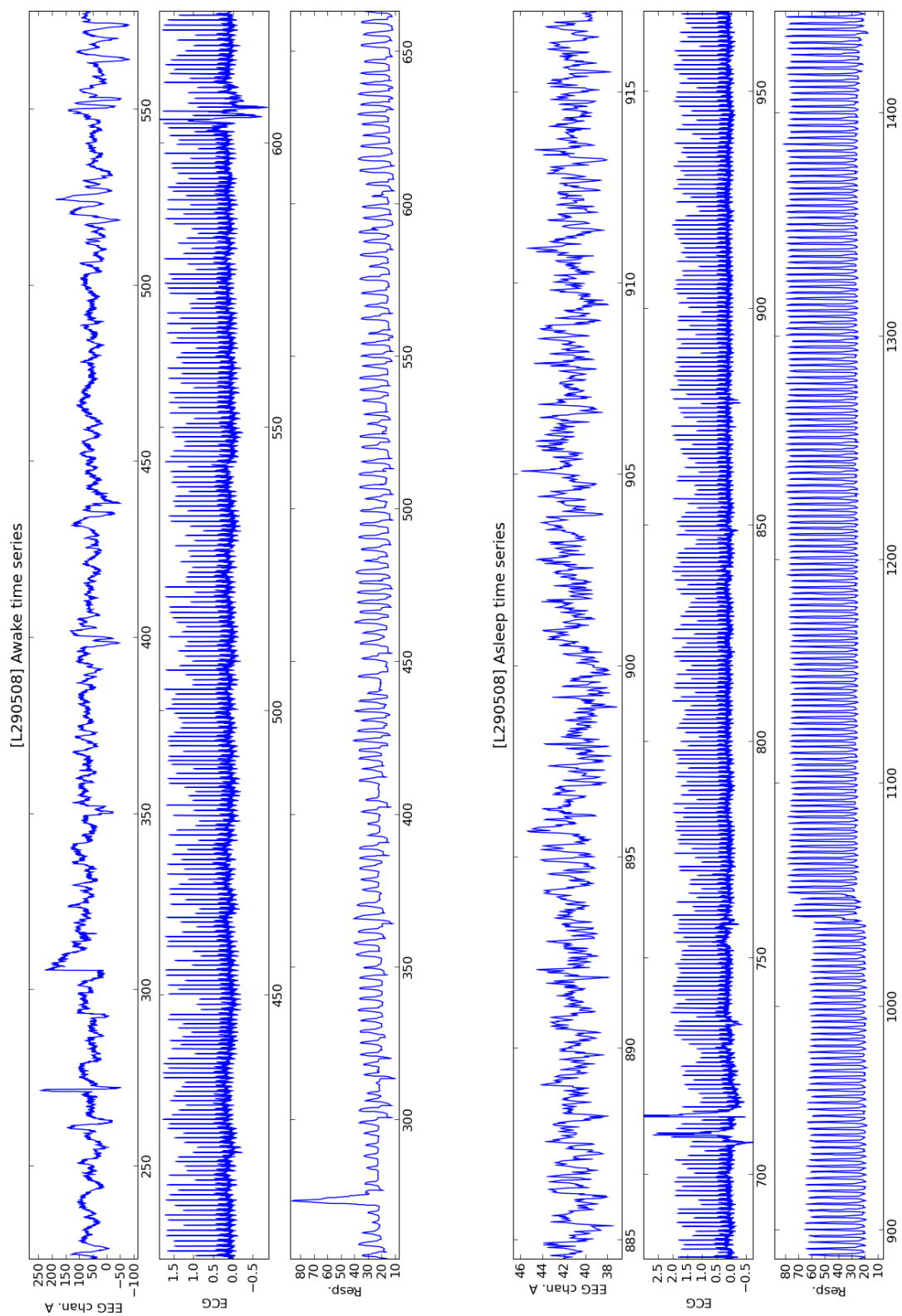


Figure 83: Time series samples of patient L290508

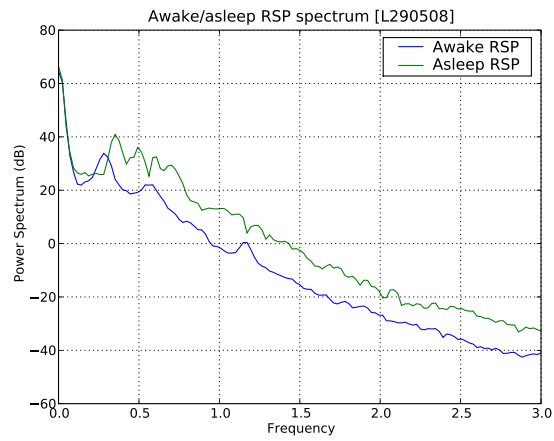
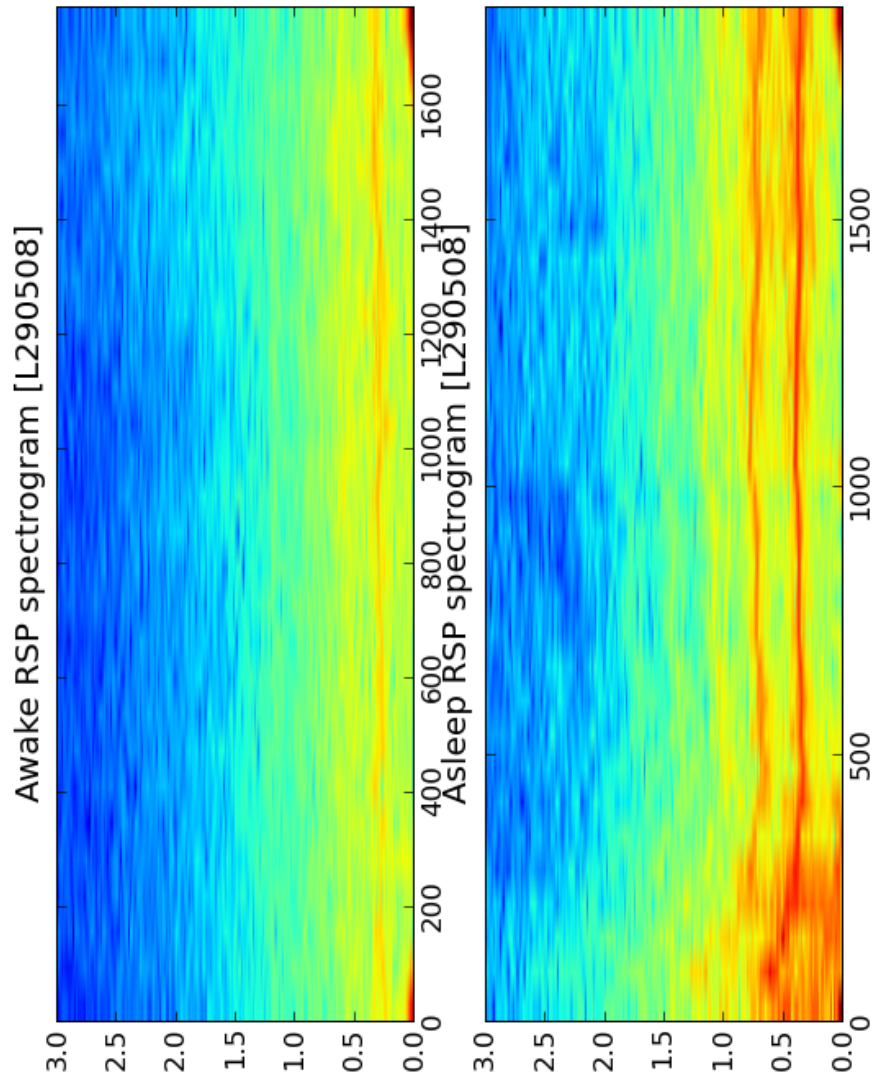


Figure 84: Time series samples of patient L290508

3.22 L300508

Comments

Sevoflurane with curare was administered. Strong 0.3Hz activity in awake state. Suspect not of physiological origin.

Awake EEG Seems contaminated. Very strong low frequency (0.3Hz) activity. No other defined activity.

Awake ECG Bipolar R peaks, stable baseline.

Awake Respiration Good signal.

Asleep EEG Clean signal, 8Hz theta/alpha band activity.

Asleep ECG Clean bipolar R peaks, stable baseline.

Asleep Respiration Valleys contaminated. Sharp peaks, nice waveform, reasonably stable amplitude.

Plots

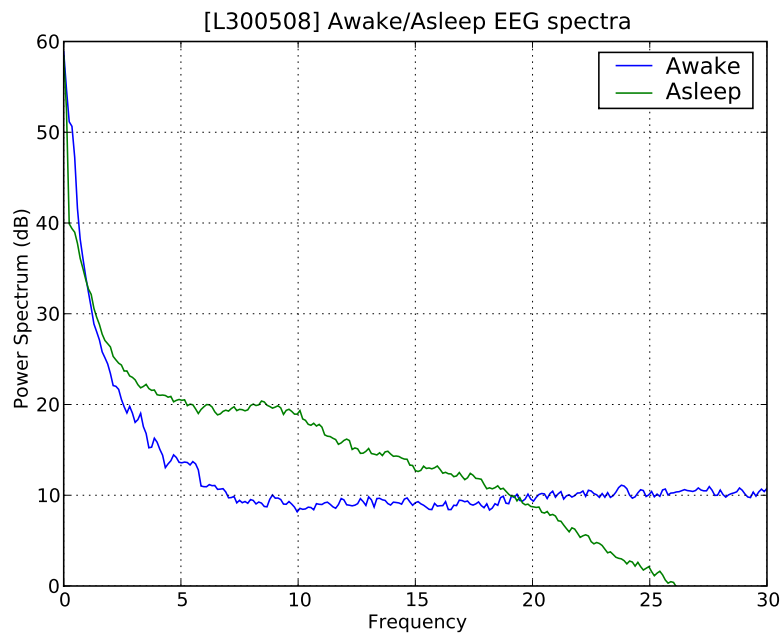


Figure 85: EEG Spectrum of patient L300508

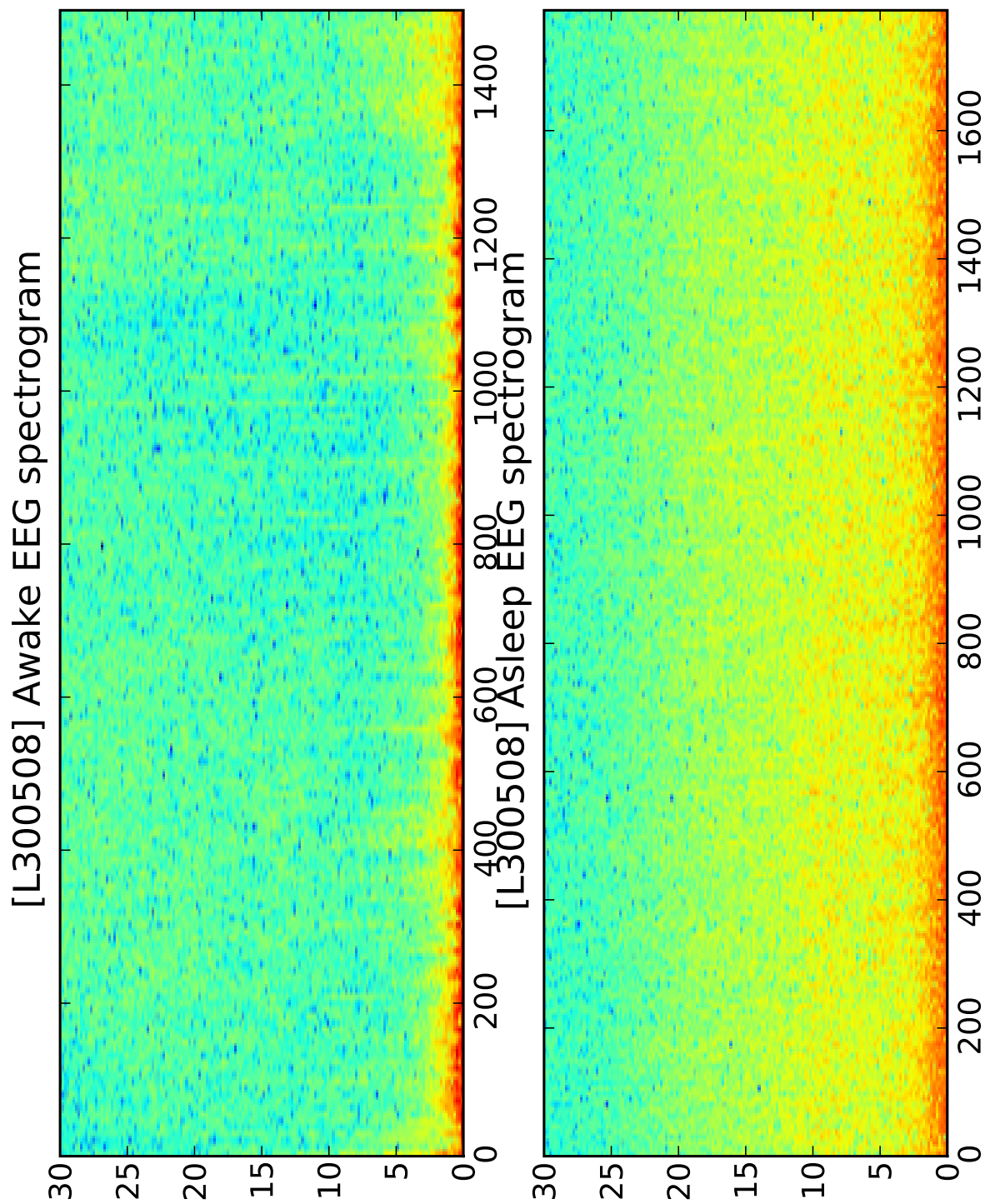


Figure 86: EEG Spectrogram of patient L300508

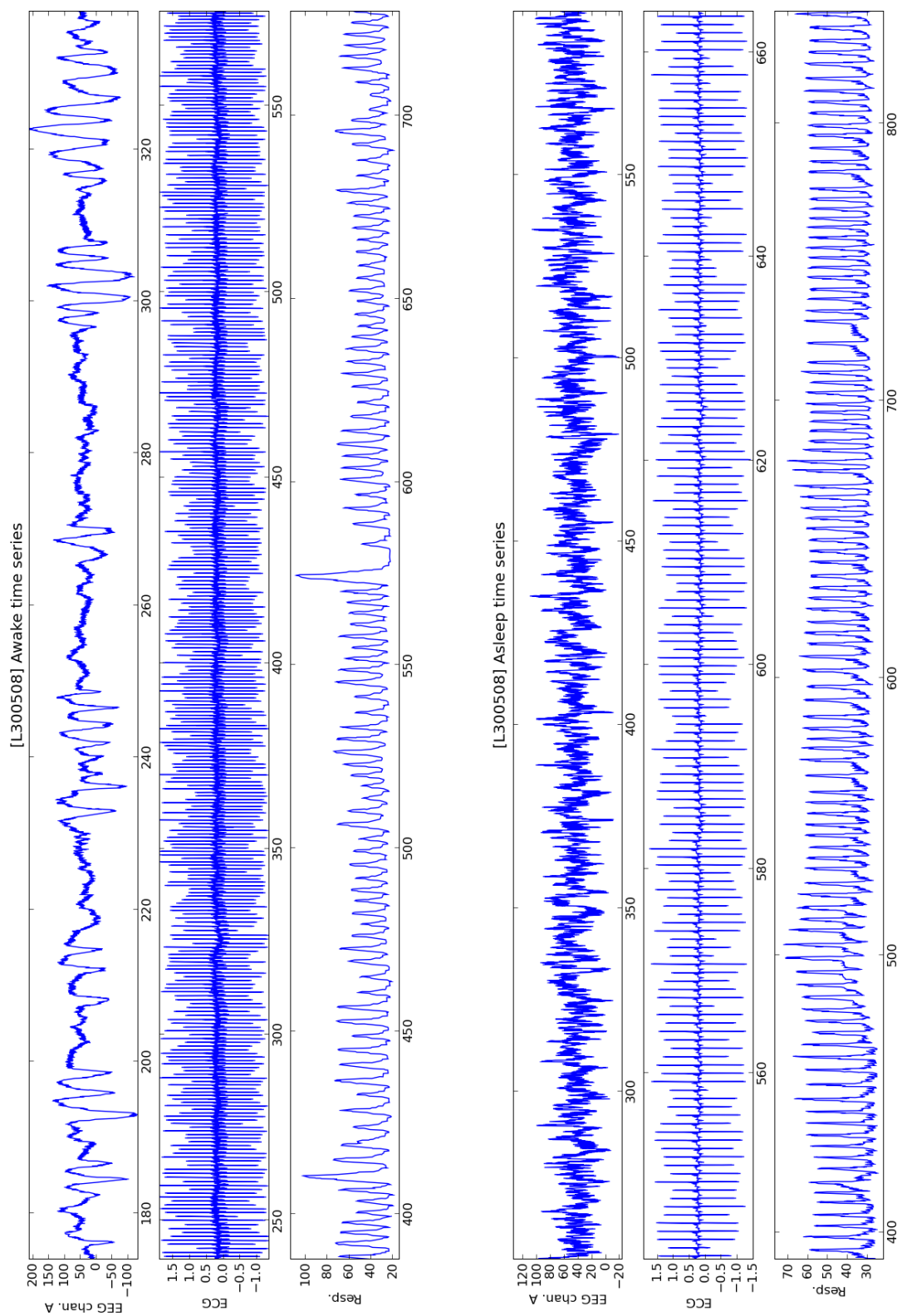


Figure 87: Time series samples of patient L300508

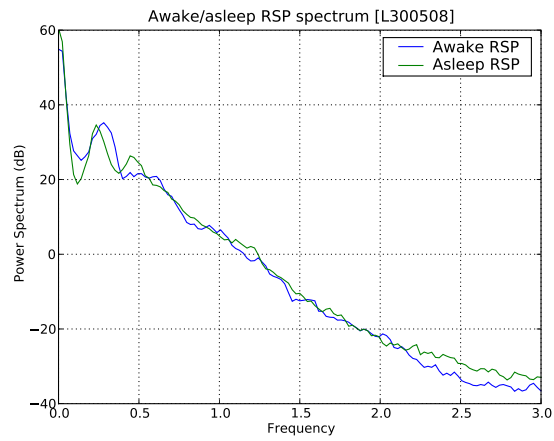
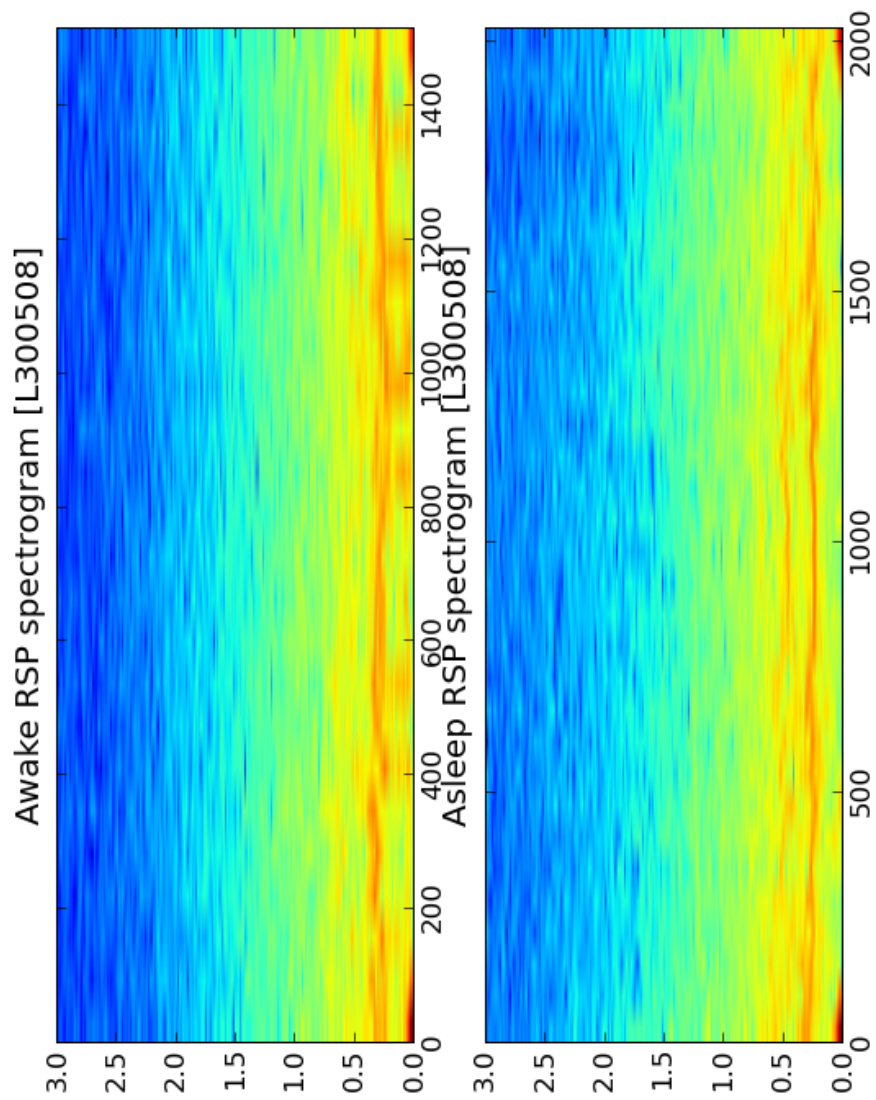


Figure 88: Time series samples of patient L300508

3.23 U103

Comments

Propofol was administered. Not used in analysis.

Awake EEG Diffuse 18Hz beta band activity. Good signal.

Awake ECG High frequency noise contamination, unstable baseline.

Awake Respiration Good waveform, some amplitude variations.

Asleep EEG Well-defined 9Hz alpha band activity.

Asleep ECG High frequency noise contamination, unstable baseline. Some baseline faults (5). Noise contamination.

Asleep Respiration Changes in amplitude, some irregularities, some unusable breaths.

Plots

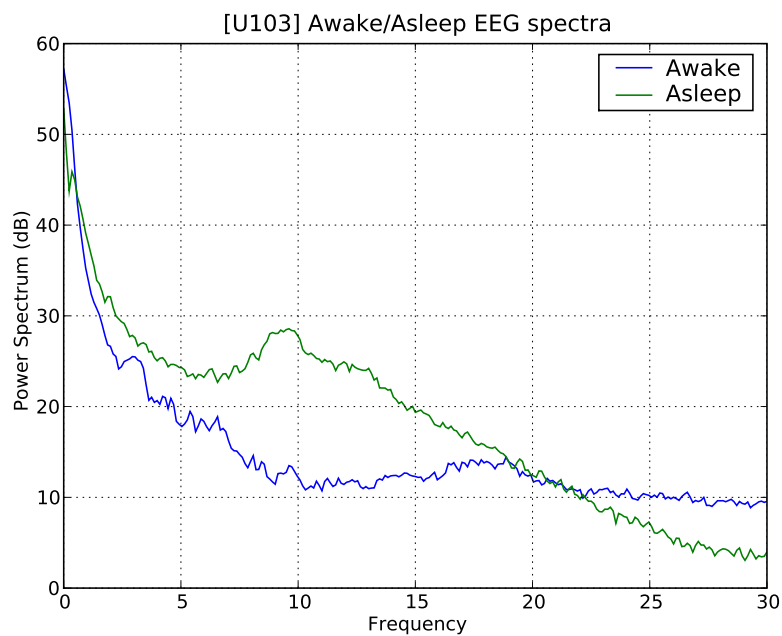


Figure 89: EEG Spectrum of patient U103

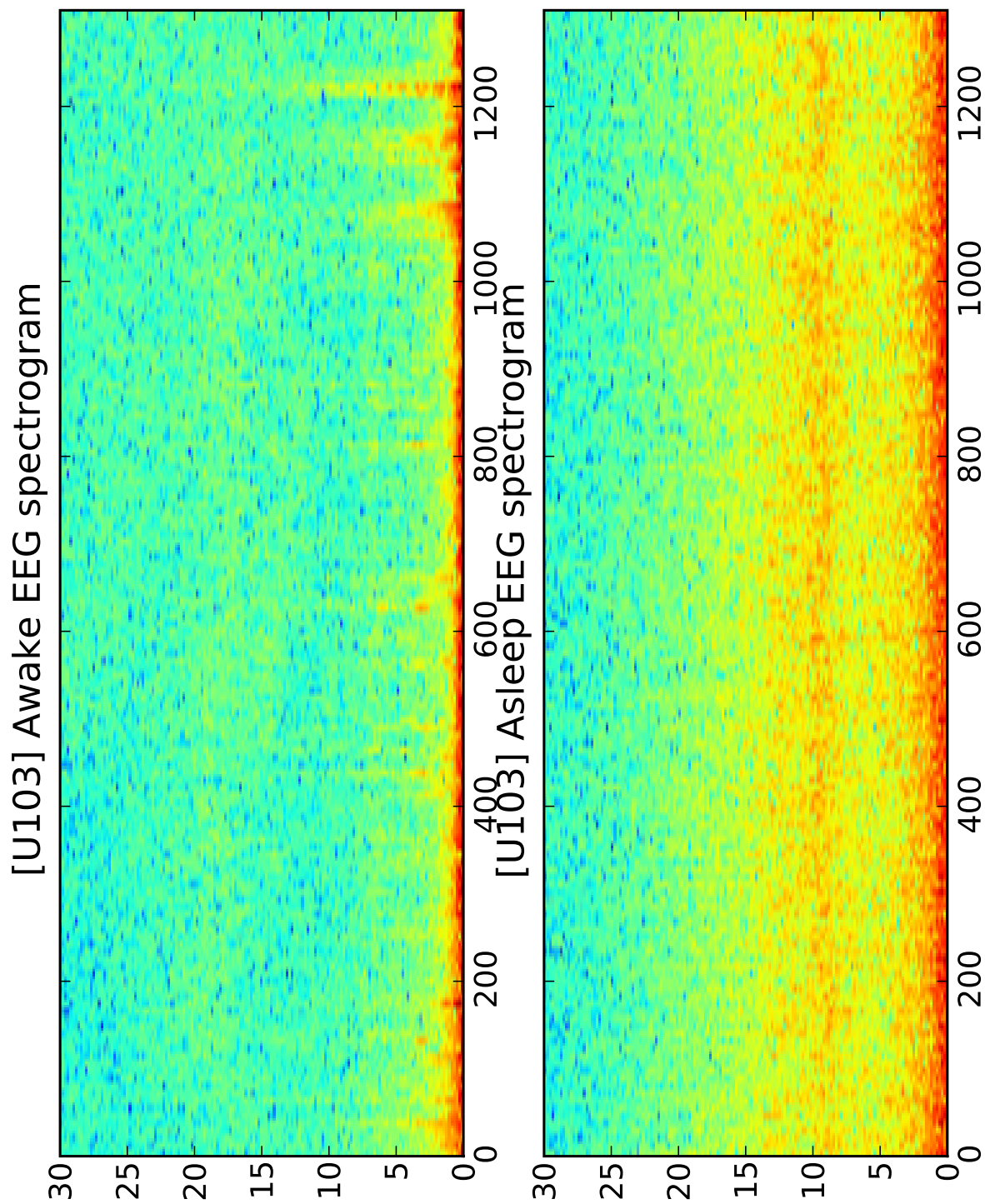


Figure 90: EEG Spectrogram of patient U103

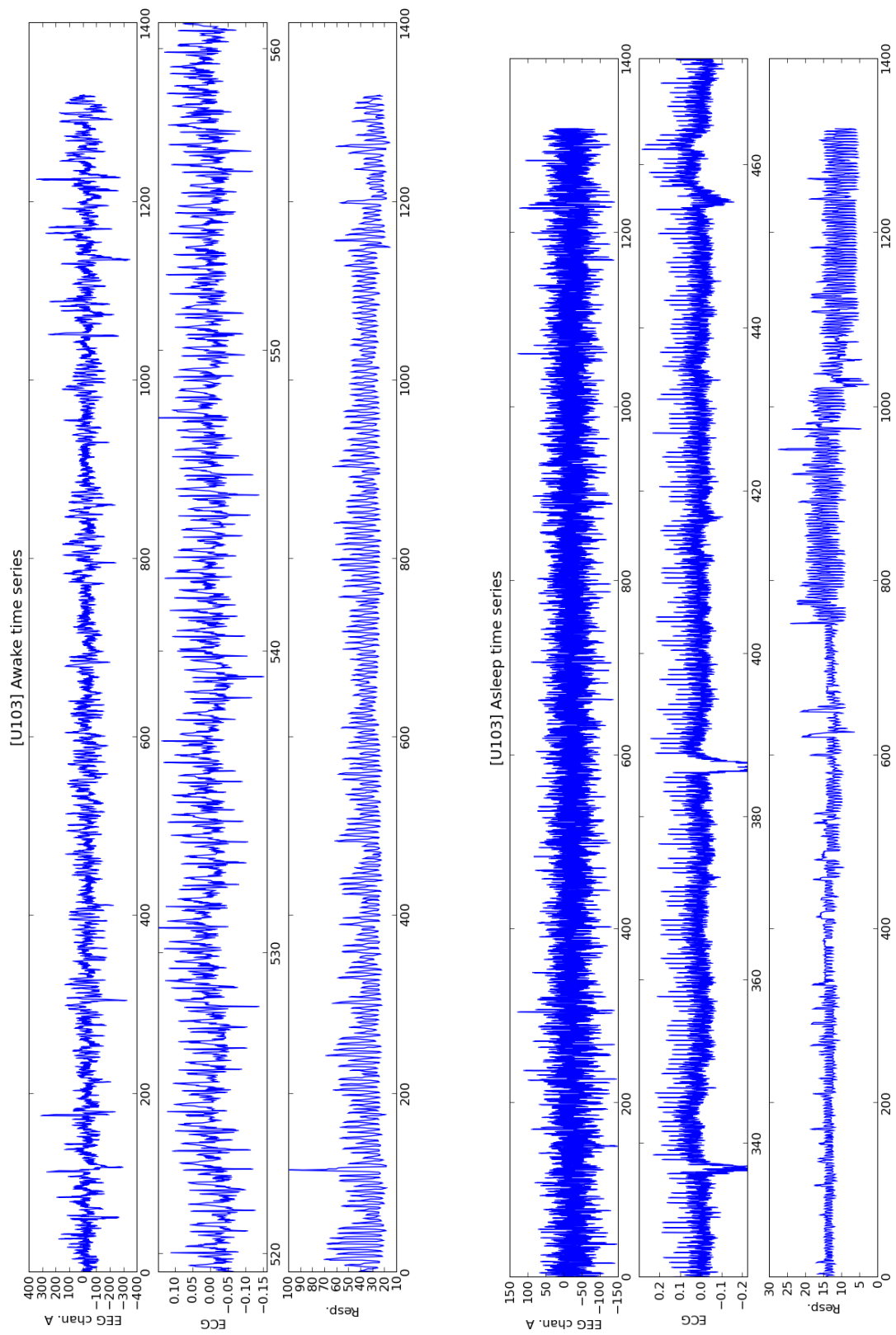


Figure 91: Time series samples of patient U103

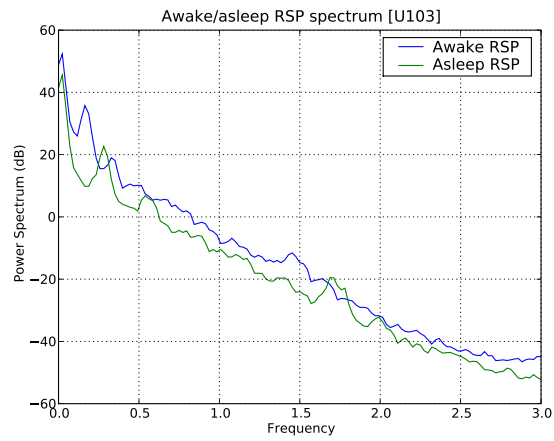
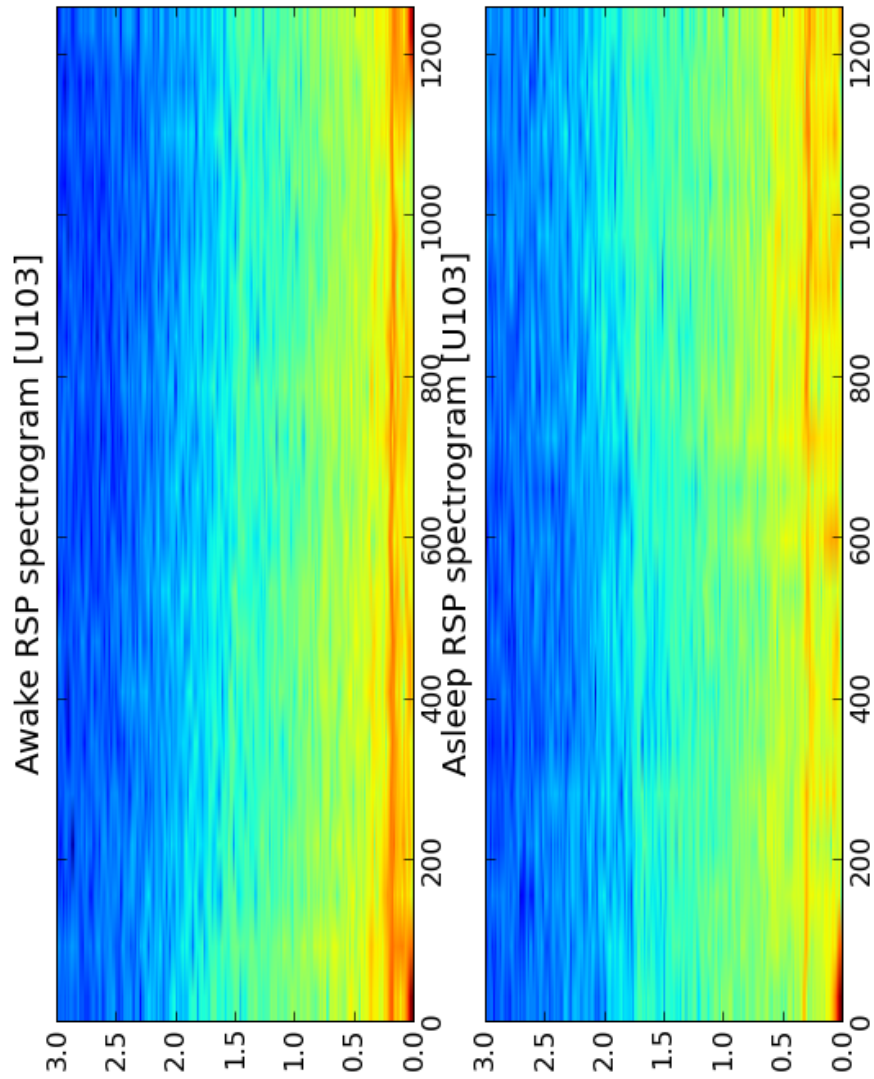


Figure 92: Time series samples of patient U103

3.24 U104

Comments

Sevoflurane with curare was administered.

Awake EEG Low power 10Hz activity, slightly diffuse. High amplitude contamination of EEG - artefacts (?).

Awake ECG Clean signal, single baseline loss at 610s.

Awake Respiration Spiky waveform, amplitude variations, passable quality.

Asleep EEG Stable 9Hz low power alpha band activity. Nice signal.

Asleep ECG Unstable baseline, clean signal.

Asleep Respiration Peaked waveform, nice signal. Valleys with small oscillations.

Plots

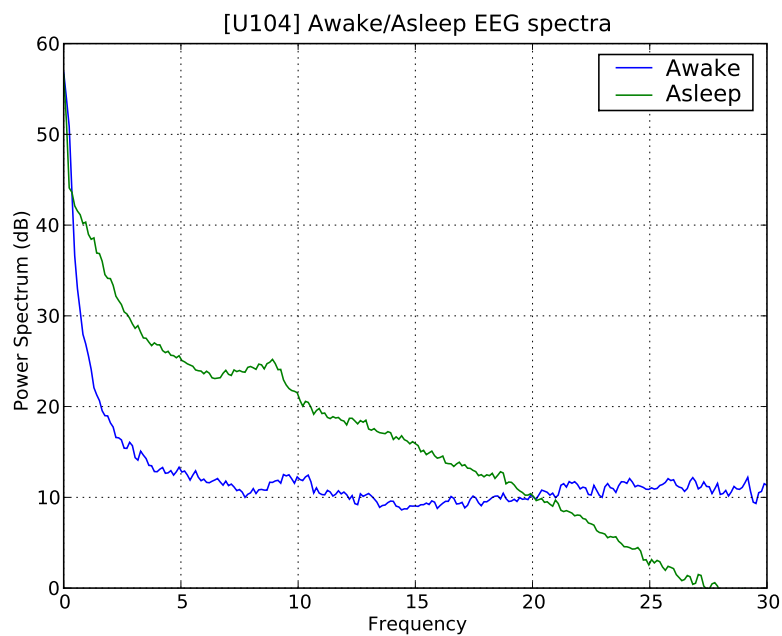


Figure 93: EEG Spectrum of patient U104

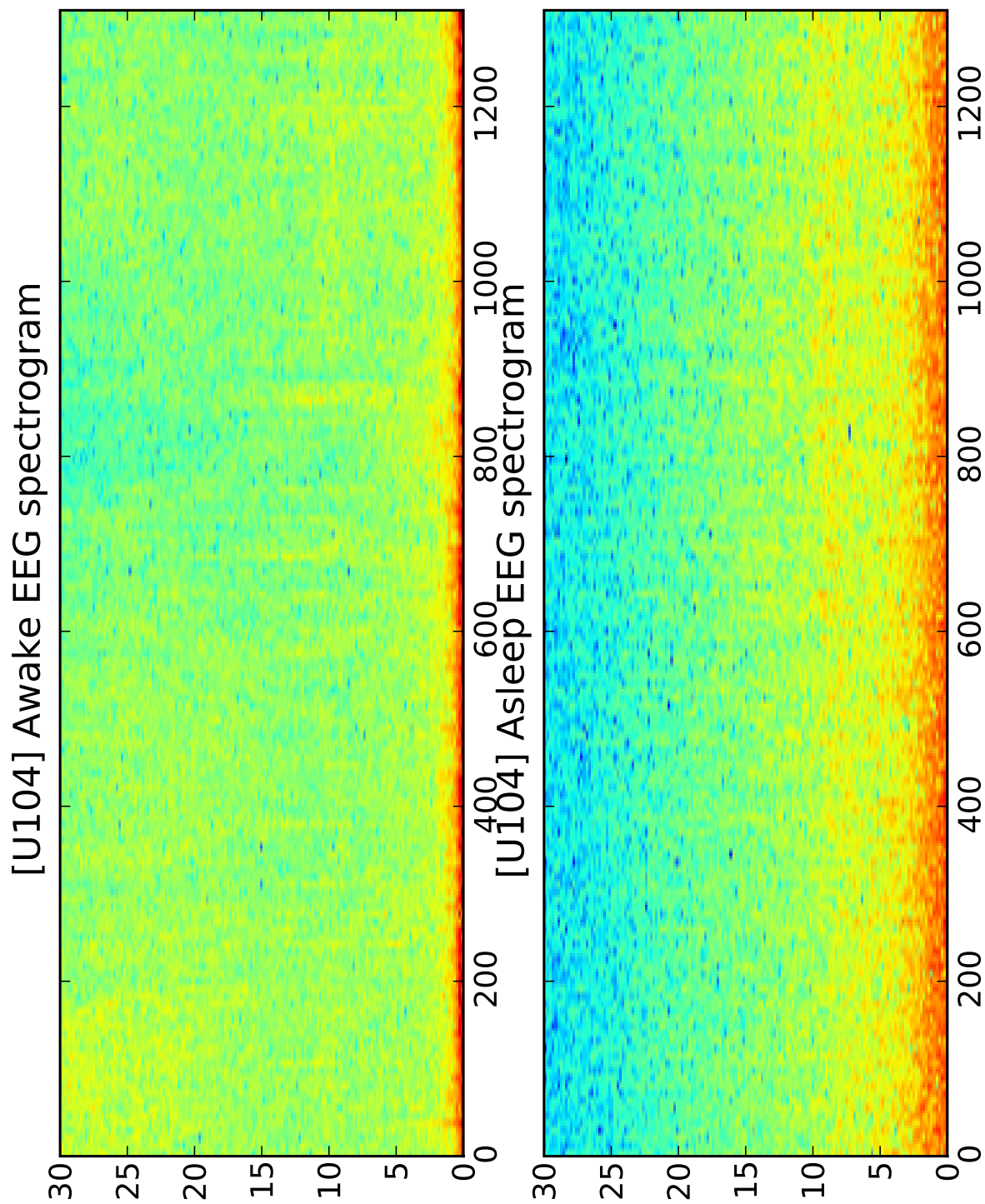


Figure 94: EEG Spectrogram of patient U104

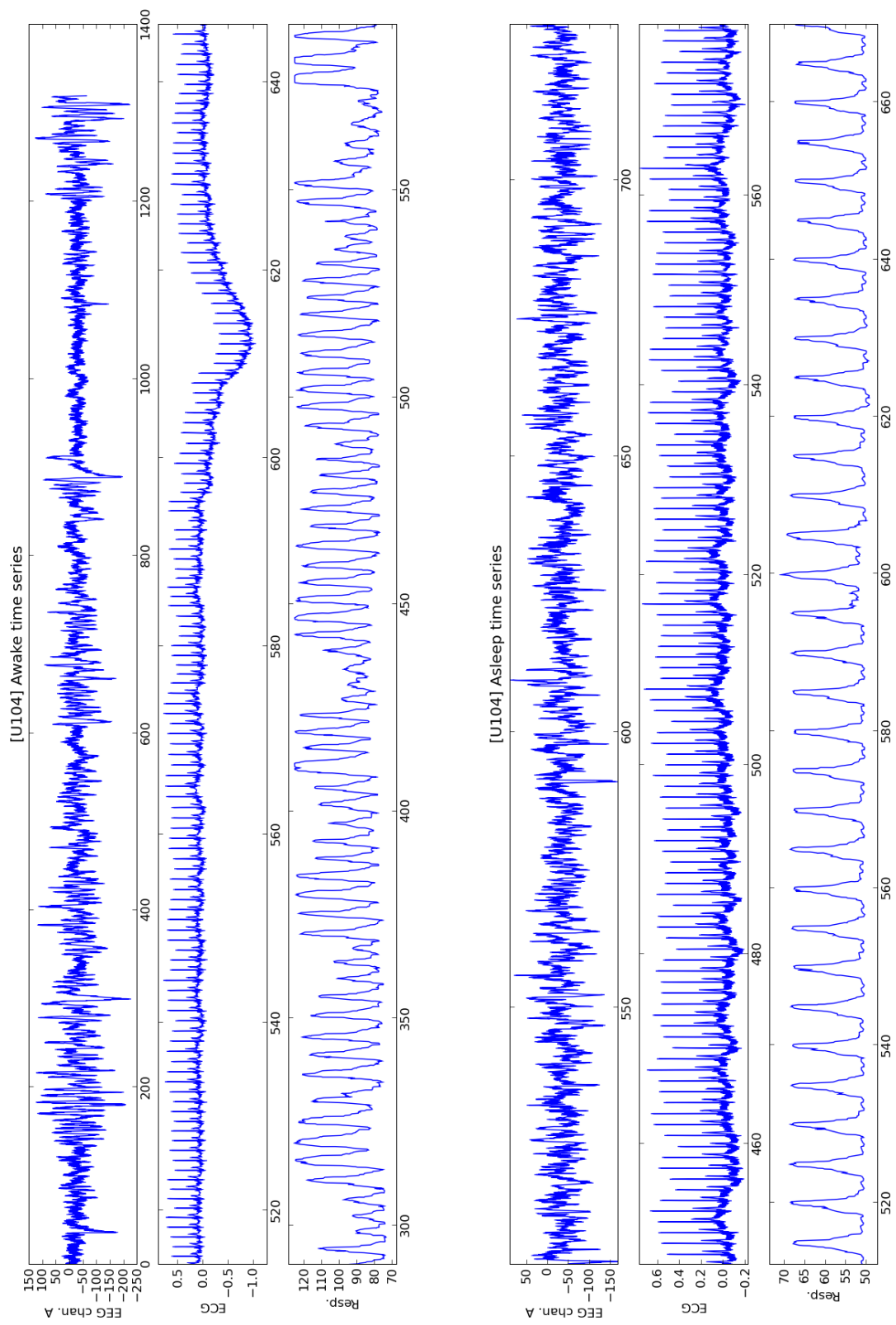


Figure 95: Time series samples of patient U104

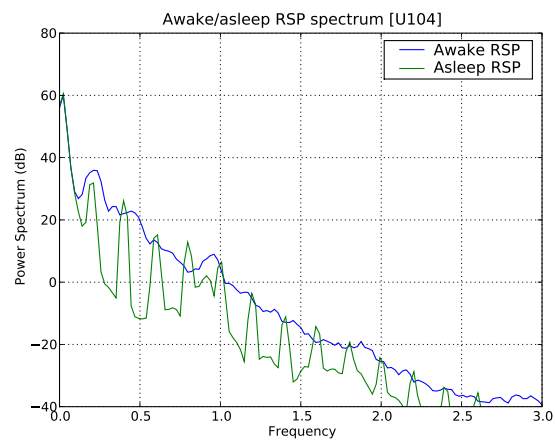
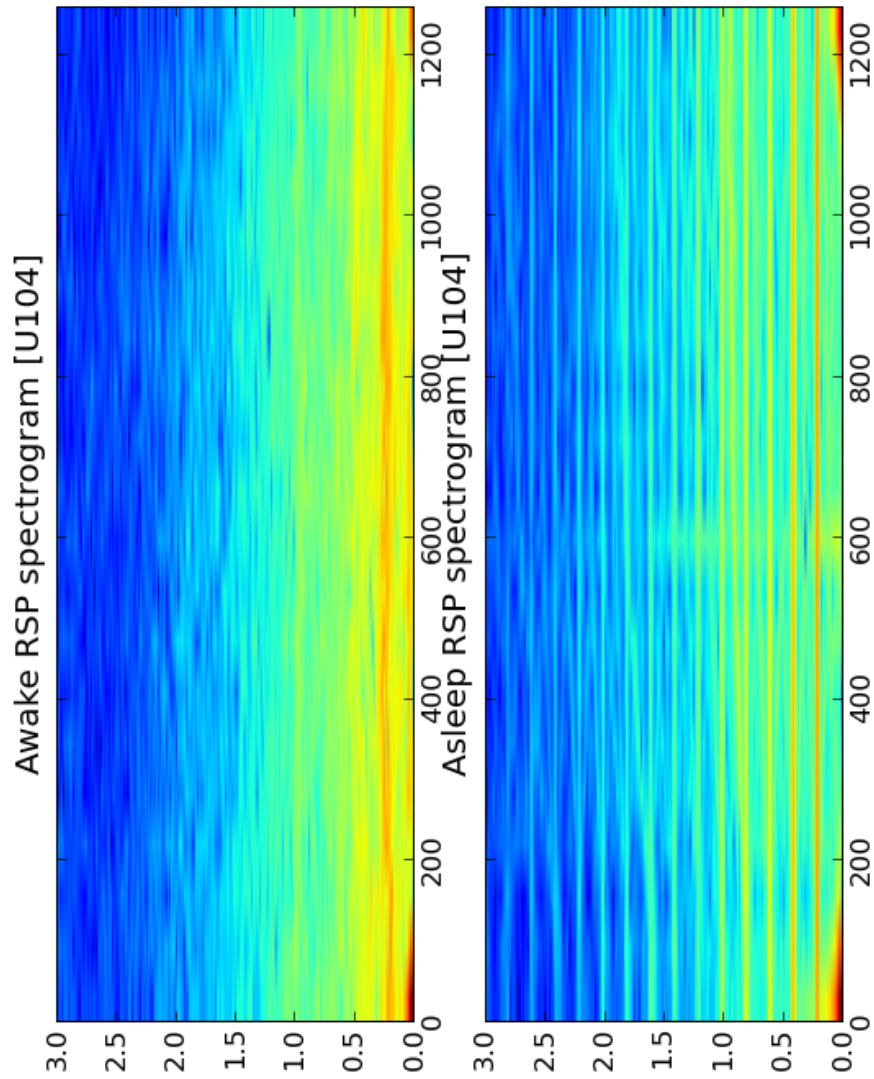


Figure 96: Time series samples of patient U104

3.25 U105

Comments

Sevoflurane with curare was administered.

Awake EEG Very bad signal form. Contamination with high amplitude noise of low frequency ?

Awake ECG Strong bipolar R peaks. Clean.

Awake Respiration Two high amplitude spikes. Stable amplitude otherwise, peaks may be randomly shifted.

Asleep EEG Stable well-defined alpha activity at 10Hz. Small spectral peak at 0.5Hz in delta band.

Asleep ECG Unstable baseline, clear signal. Bipolar R wave.

Asleep Respiration Spiked asymmetric waveform. Peaks may be shifted, noise contamination.

Plots

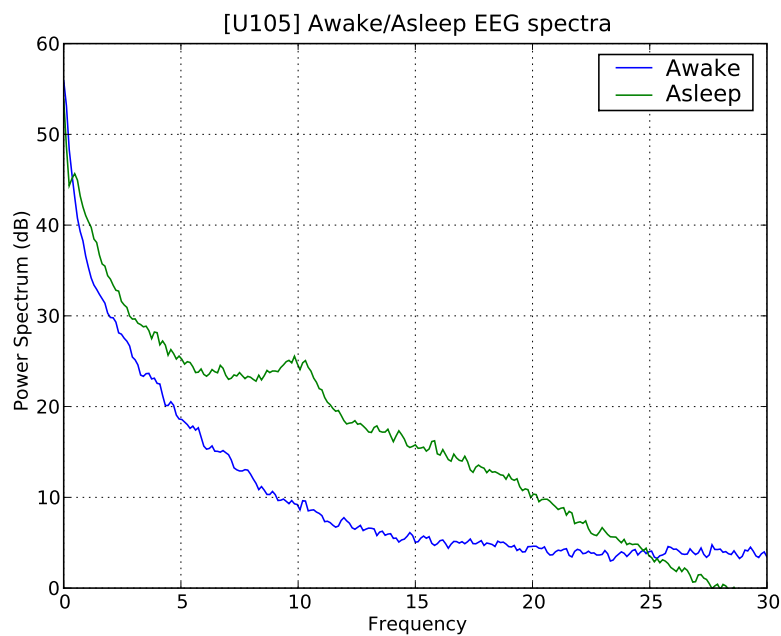


Figure 97: EEG Spectrum of patient U105

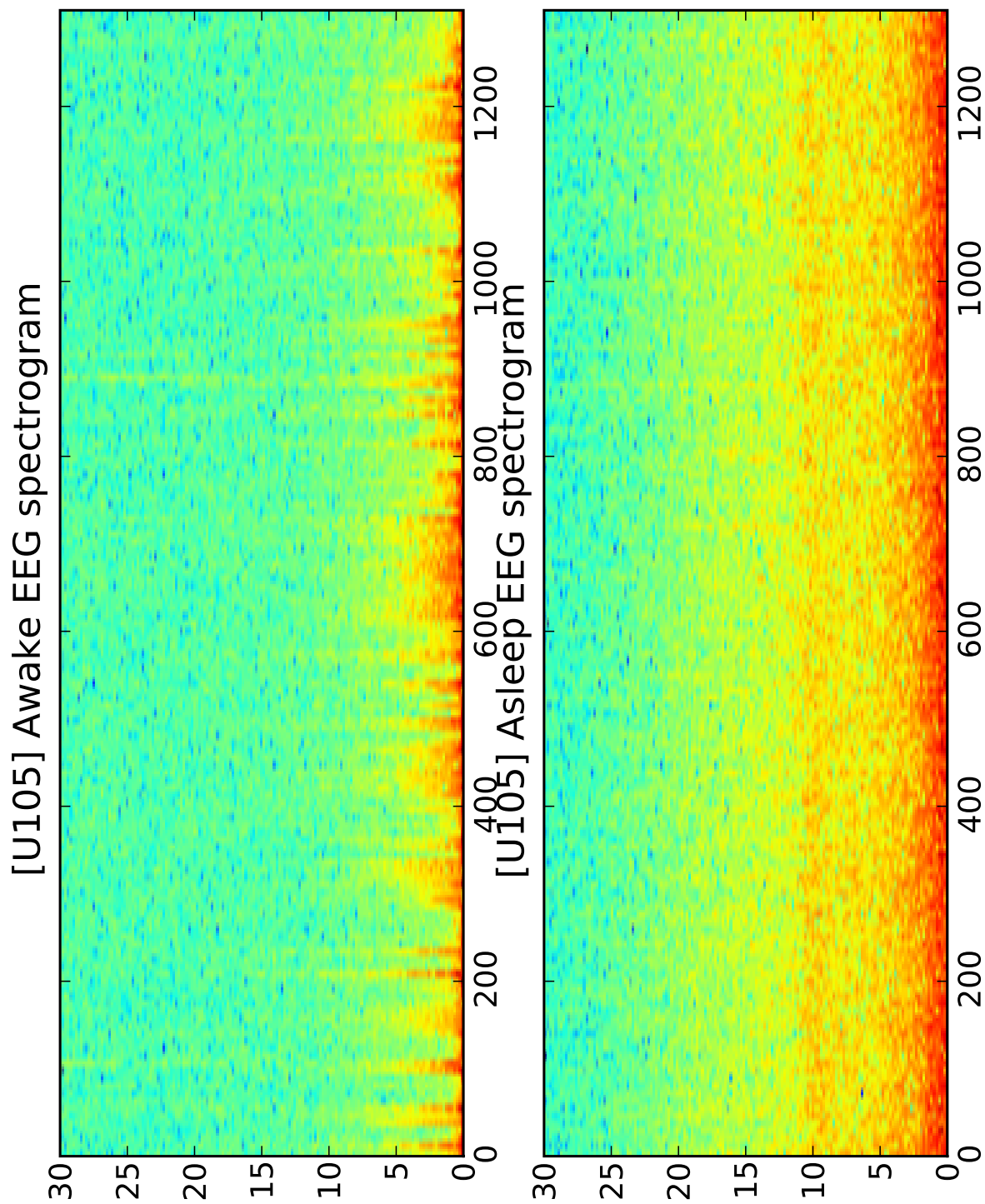


Figure 98: EEG Spectrogram of patient U105

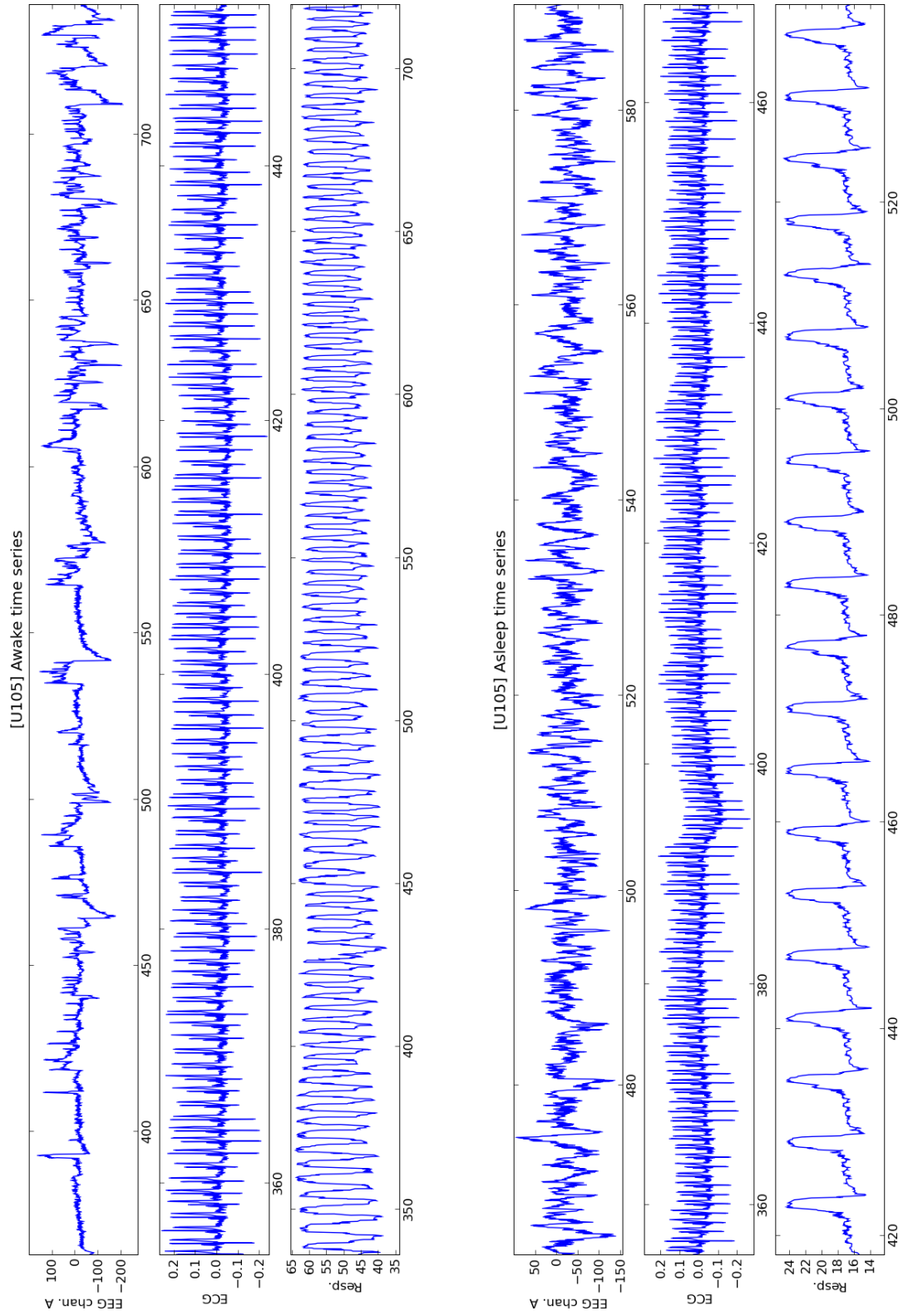


Figure 99: Time series samples of patient U105

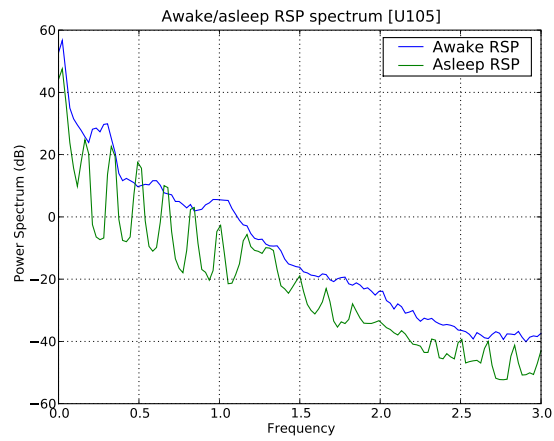
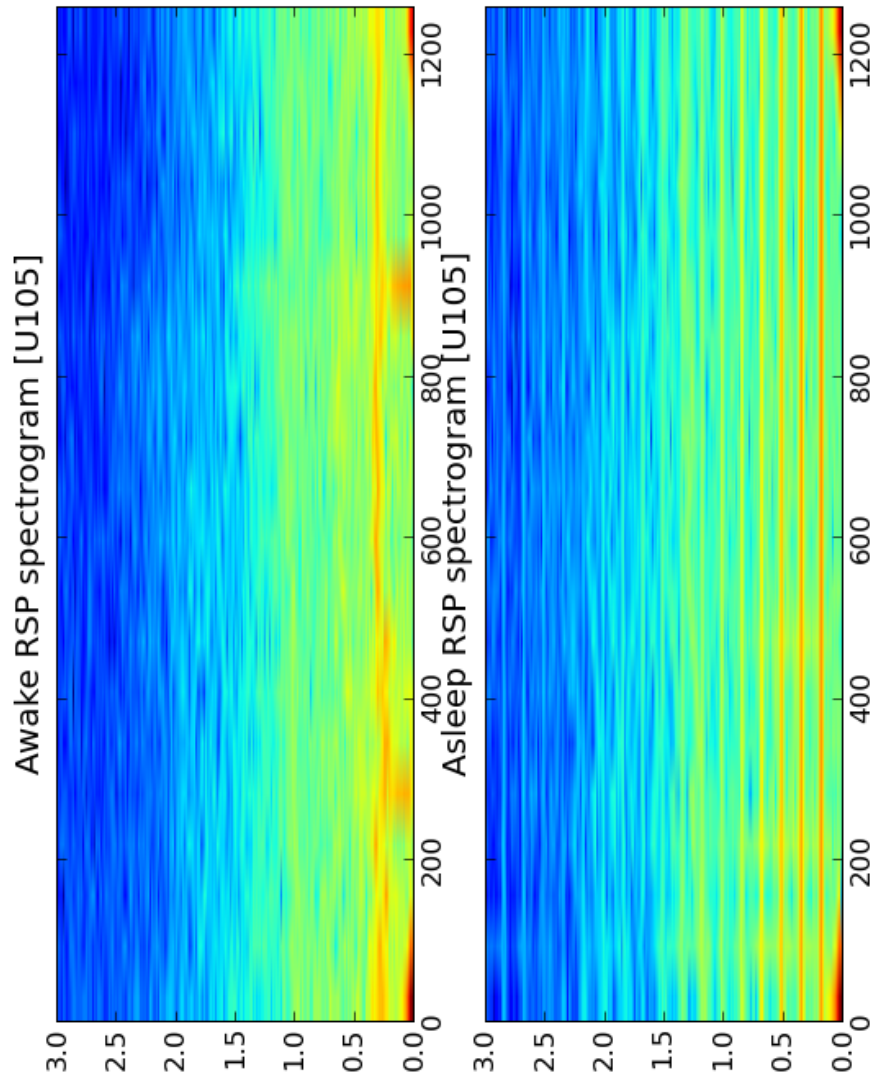


Figure 100: Time series samples of patient U105

3.26 U106

Comments

Propofol with curare was administered. EEG activity not very nice, other signals have very high quality.

Awake EEG No definable activity. Waveform not good - very high amplitude low frequency activity.

Awake ECG Bipolar R peaks, unstable baseline, good signal.

Awake Respiration Slightly unstable amplitude, small trend in series, peaked waveform. Spike at 170s.

Asleep EEG Well-defined activity at 12Hz in the alpha band. Small peak at 0.5Hz, activity in delta band.

Asleep ECG Bipolar R peaks, clean signal, slightly unstable baseline.

Asleep Respiration Perfectly clean waveform, spiked, stable amplitude.

Plots

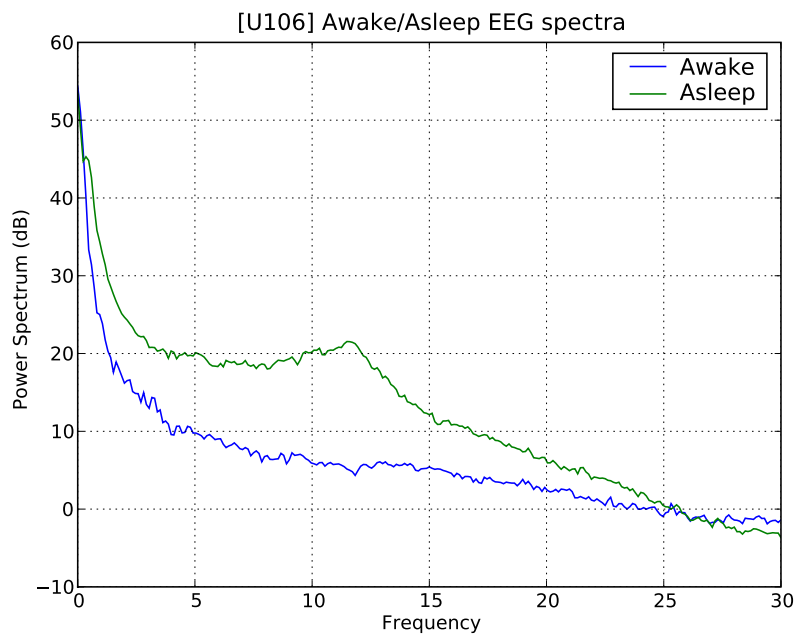


Figure 101: EEG Spectrum of patient U106

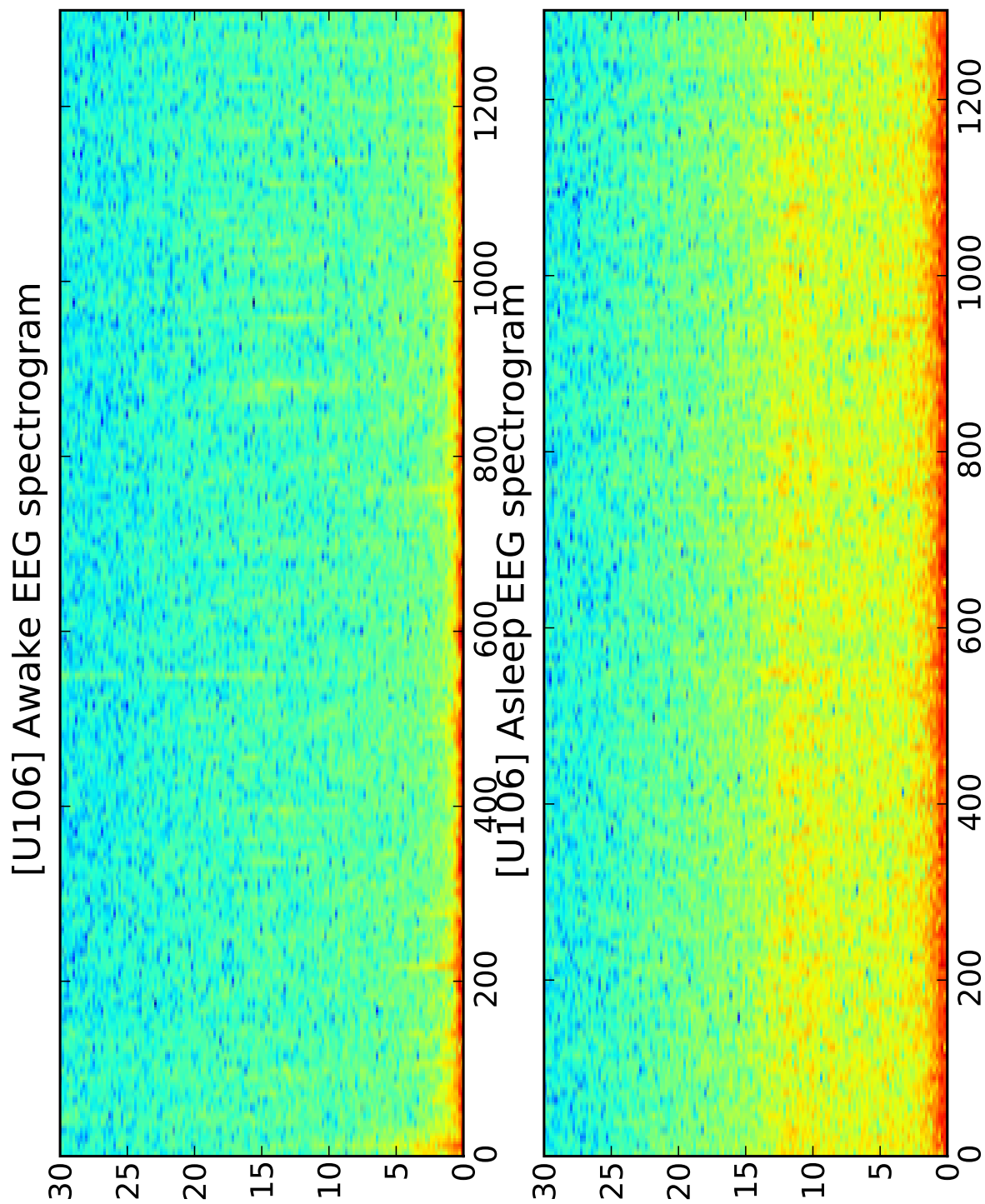


Figure 102: EEG Spectrogram of patient U106

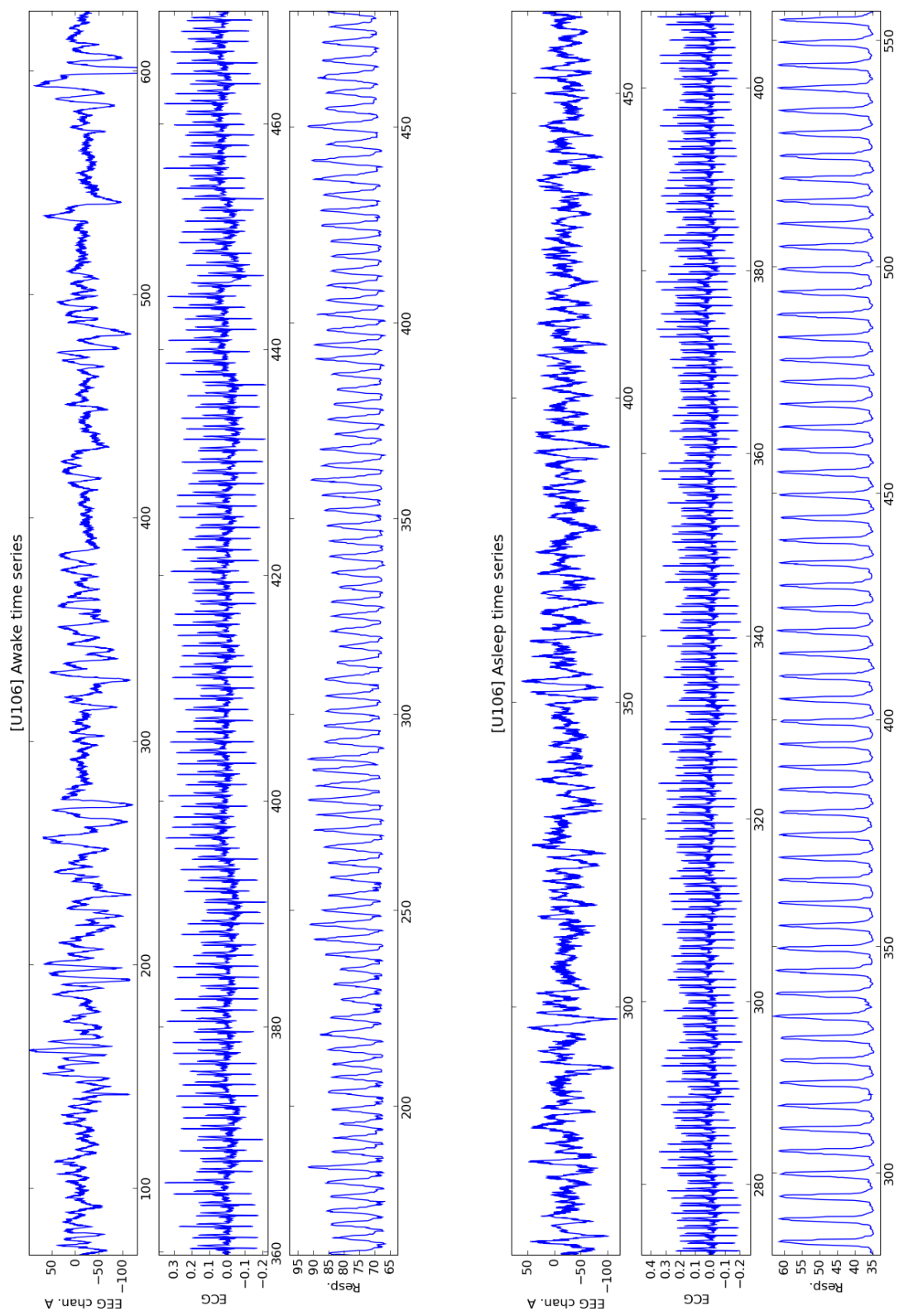


Figure 103: Time series samples of patient U106

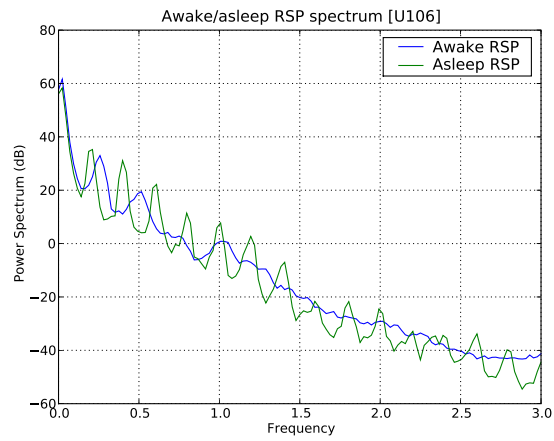
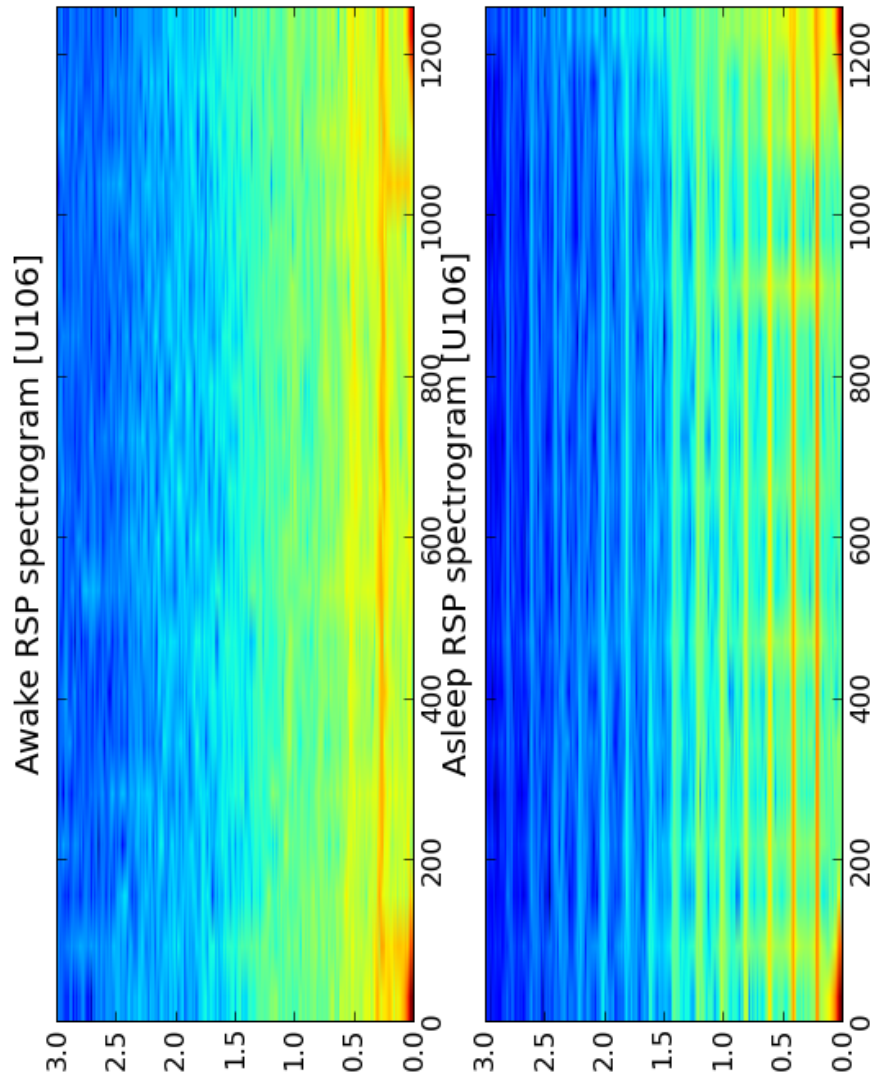


Figure 104: Time series samples of patient U106

3.27 U107

Comments

Sevoflurane was administered.

Awake EEG Low power theta band activity at 6Hz. Very low power unstable activity in delta band at 1.5Hz. Not seen in spectrum. Very low amplitude EEG activity on top of very low frequency high amplitude activity.

Awake ECG Unstable baseline, clean signal.

Awake Respiration Peaked waveform, some contamination, peak positions may be shifted.

Asleep EEG Well-defined activity at 9Hz in alpha band.

Asleep ECG Unstable fast changing baseline, clean signal.

Asleep Respiration Peaked symmetric waveform. Peak positions may be shifted. Slight contamination on peaks and valleys.

Plots

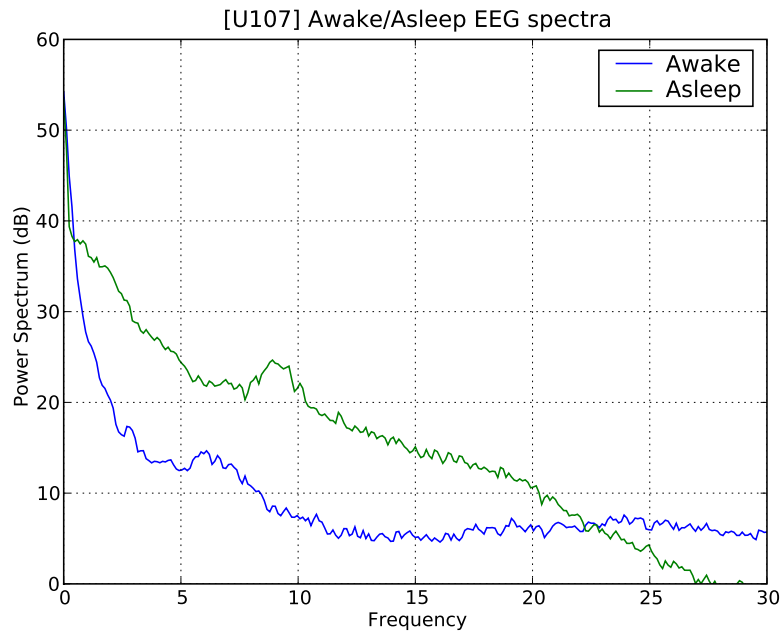


Figure 105: EEG Spectrum of patient U107

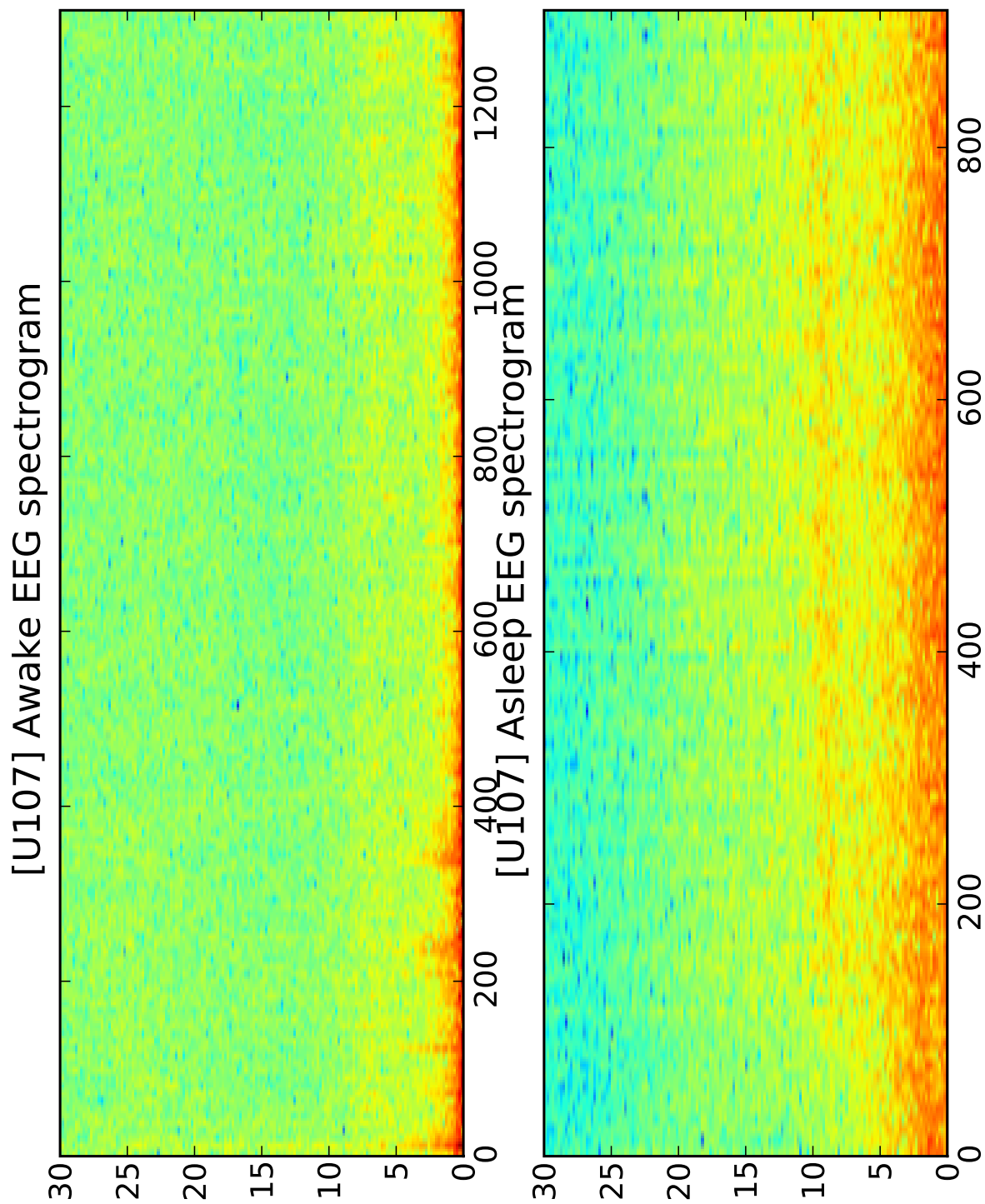


Figure 106: EEG Spectrogram of patient U107

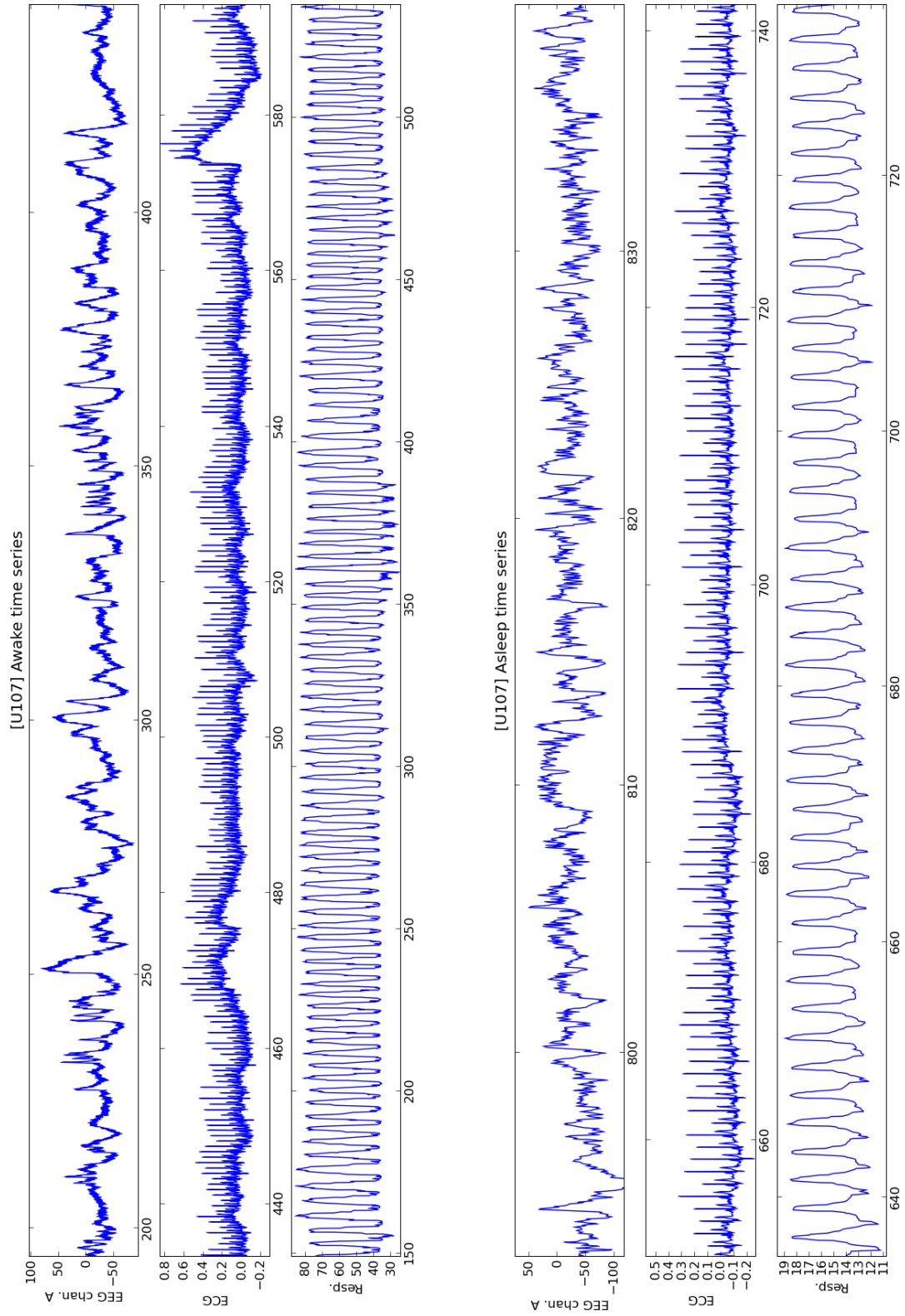


Figure 107: Time series samples of patient U107

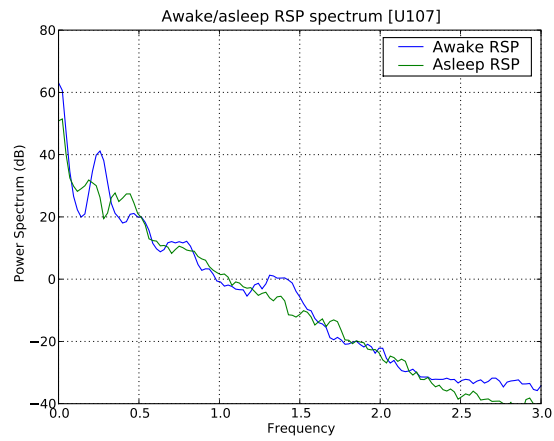
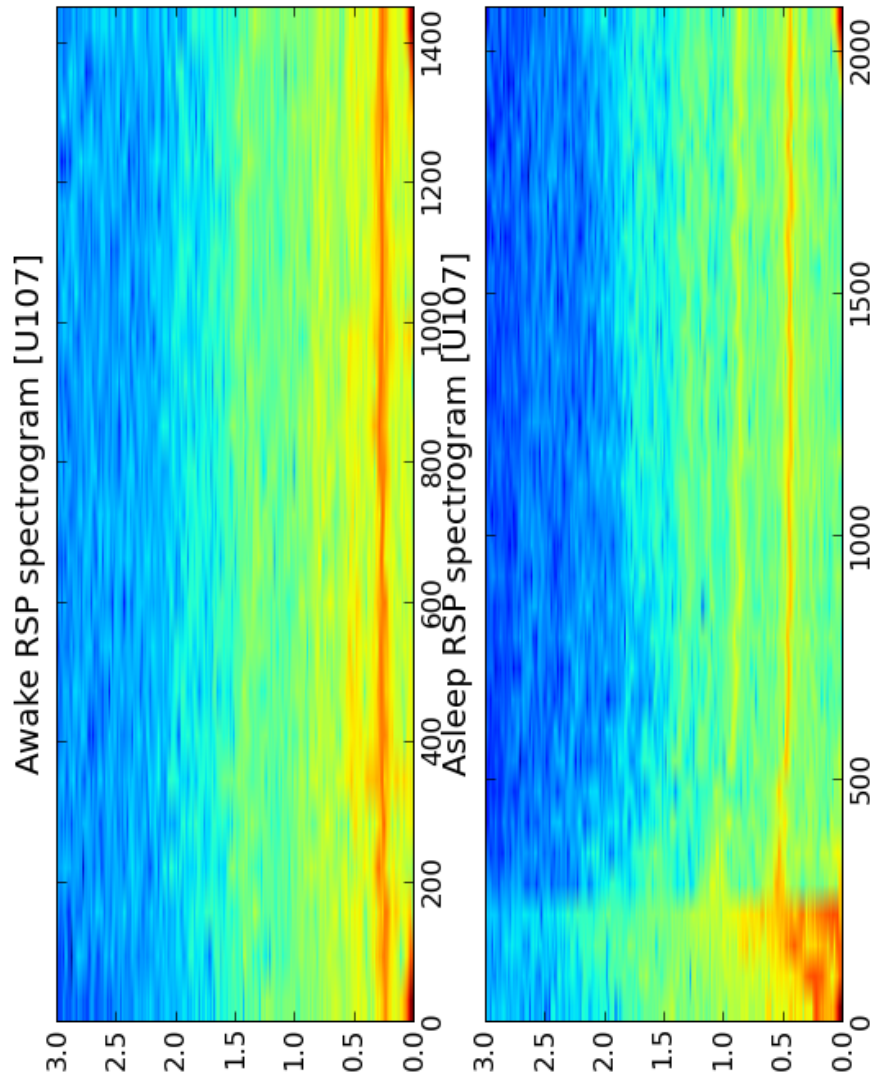


Figure 108: Time series samples of patient U107

3.28 U108

Comments

Propofol with curare was administered. First 900s in sleep useless because of respiration.

Awake EEG Low amplitude EEG signal riding on high amplitude low frequency noise (?). Activity in alpha band 9Hz.

Awake ECG Unstable baseline, bipolar R peaks. Clean signal.

Awake Respiration Unstable waveform, amplitude. High amplitude spikes. Unclear peak positions, may be shifted.

Asleep EEG Well-defined alpha band activity around 9-10Hz.

Asleep ECG Unstable baseline, strong bipolar R peaks.

Asleep Respiration Bad signal faults. Intermittent measurement failure at 900s. Only end is usable 900s+. Good peaked waveform.

Plots

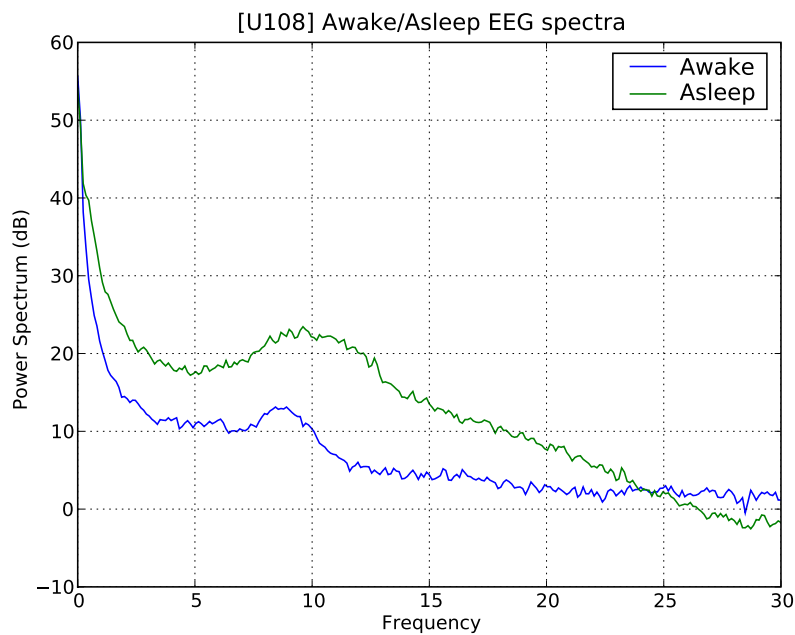


Figure 109: EEG Spectrum of patient U108

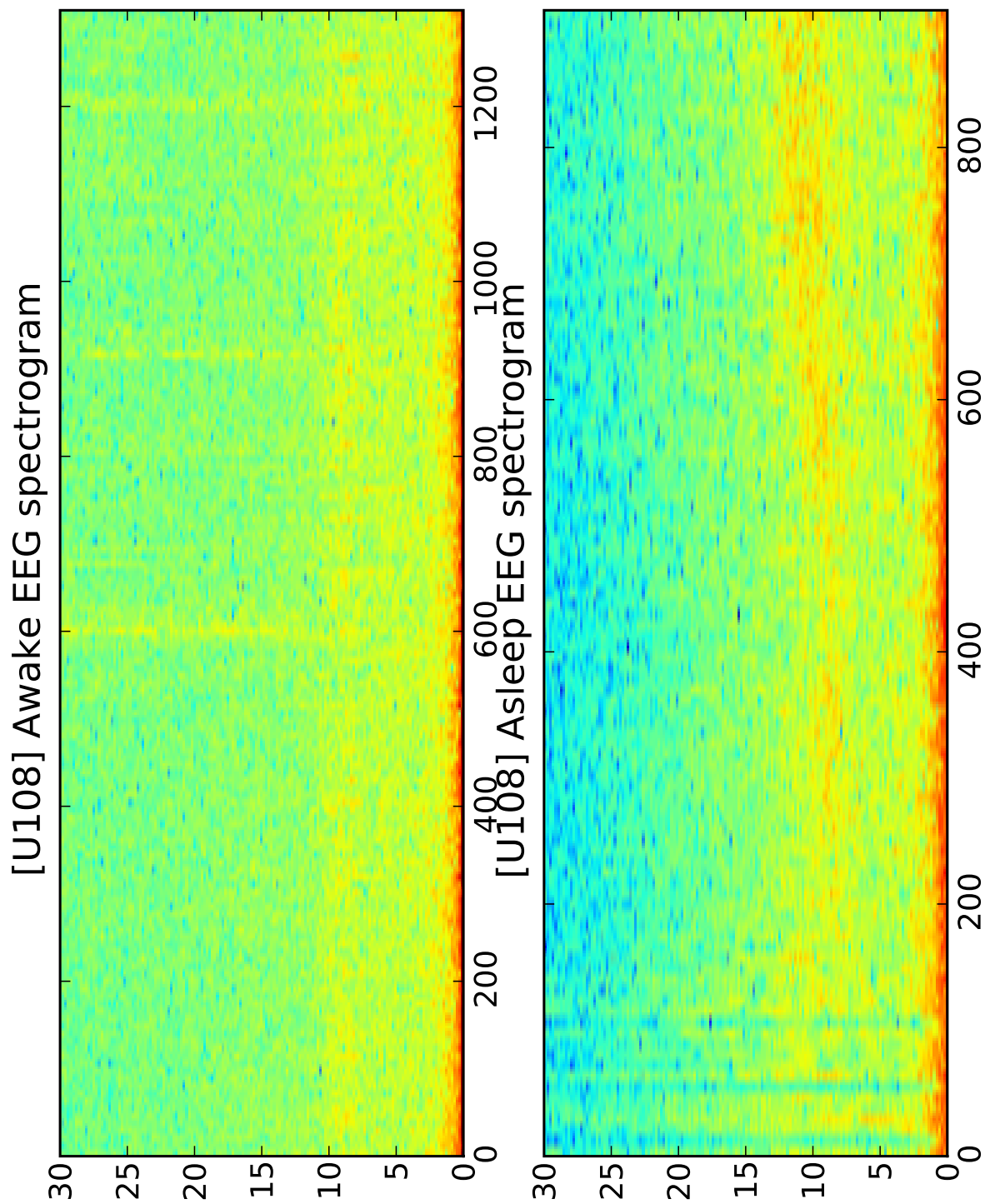


Figure 110: EEG Spectrogram of patient U108

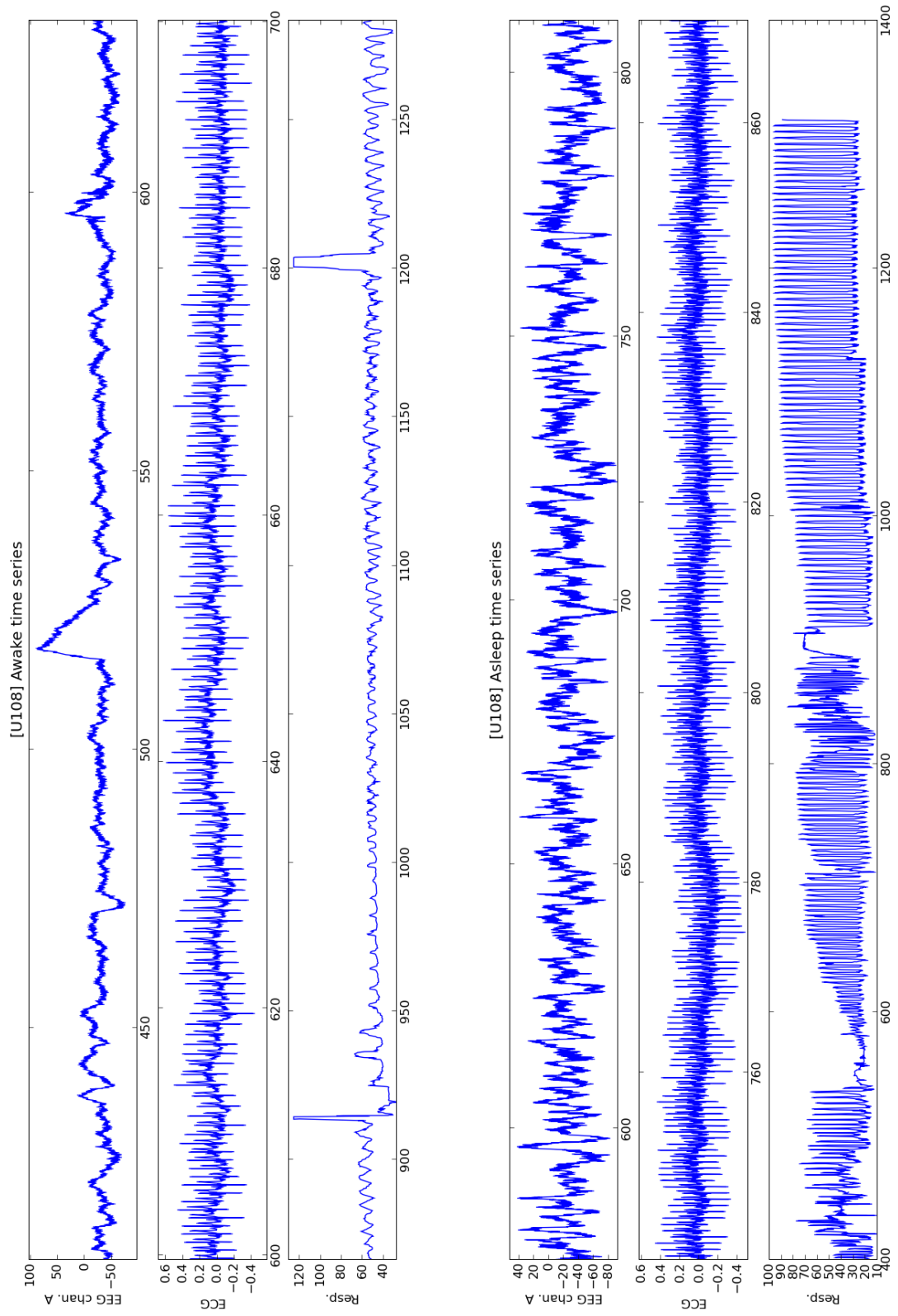


Figure 111: Time series samples of patient U108

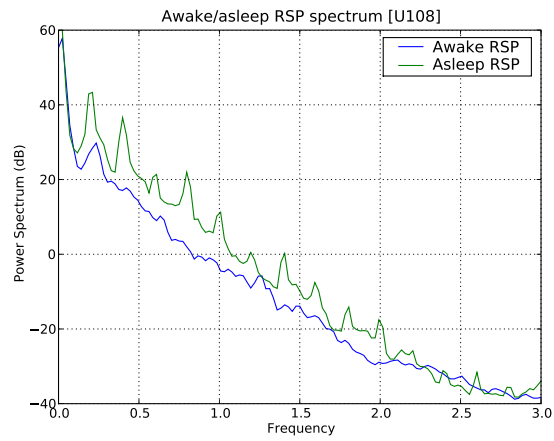
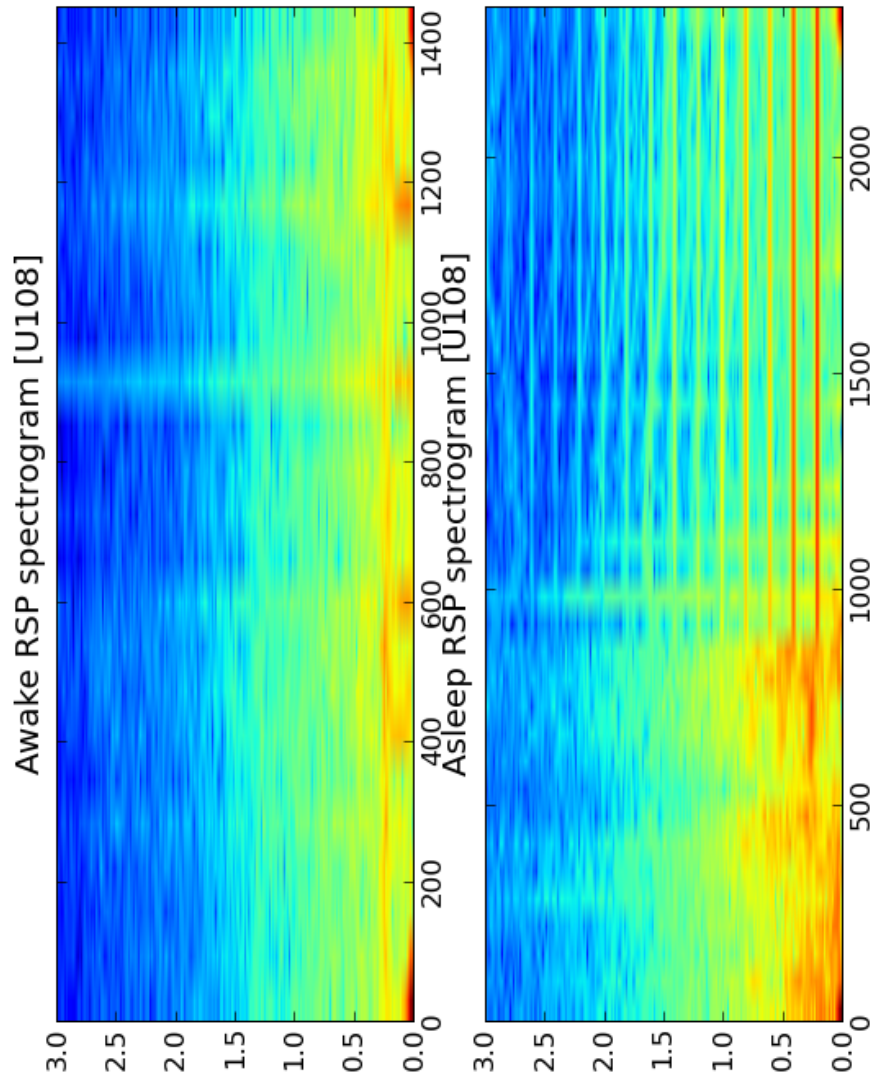


Figure 112: Time series samples of patient U108

3.29 U109

Comments

Propofol was administered.

Awake EEG No clear activity. High freq low amp waves over very low frequency high amplitude waves.

Awake ECG Baseline instability, good signal.

Awake Respiration Some baseline instability, nice waveform, some amplitude spikes (3), good quality.

Asleep EEG Low power alpha activity at 11Hz. Good signal.

Asleep ECG Two baseline losses (1000s, 1700s). Some amplitude variation.

Asleep Respiration Some noise contamination in lower parts, nice waveform, some point faults. Regular high amplitude spikes.

Plots

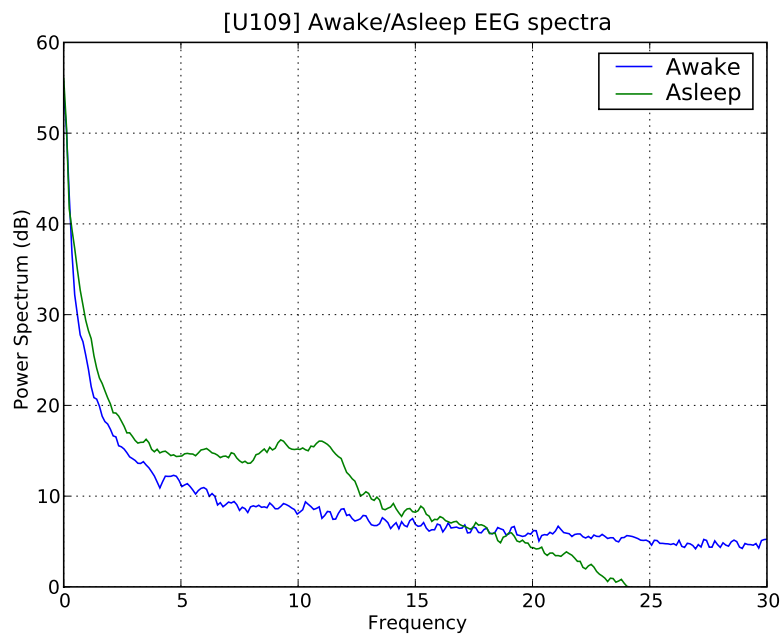


Figure 113: EEG Spectrum of patient U109

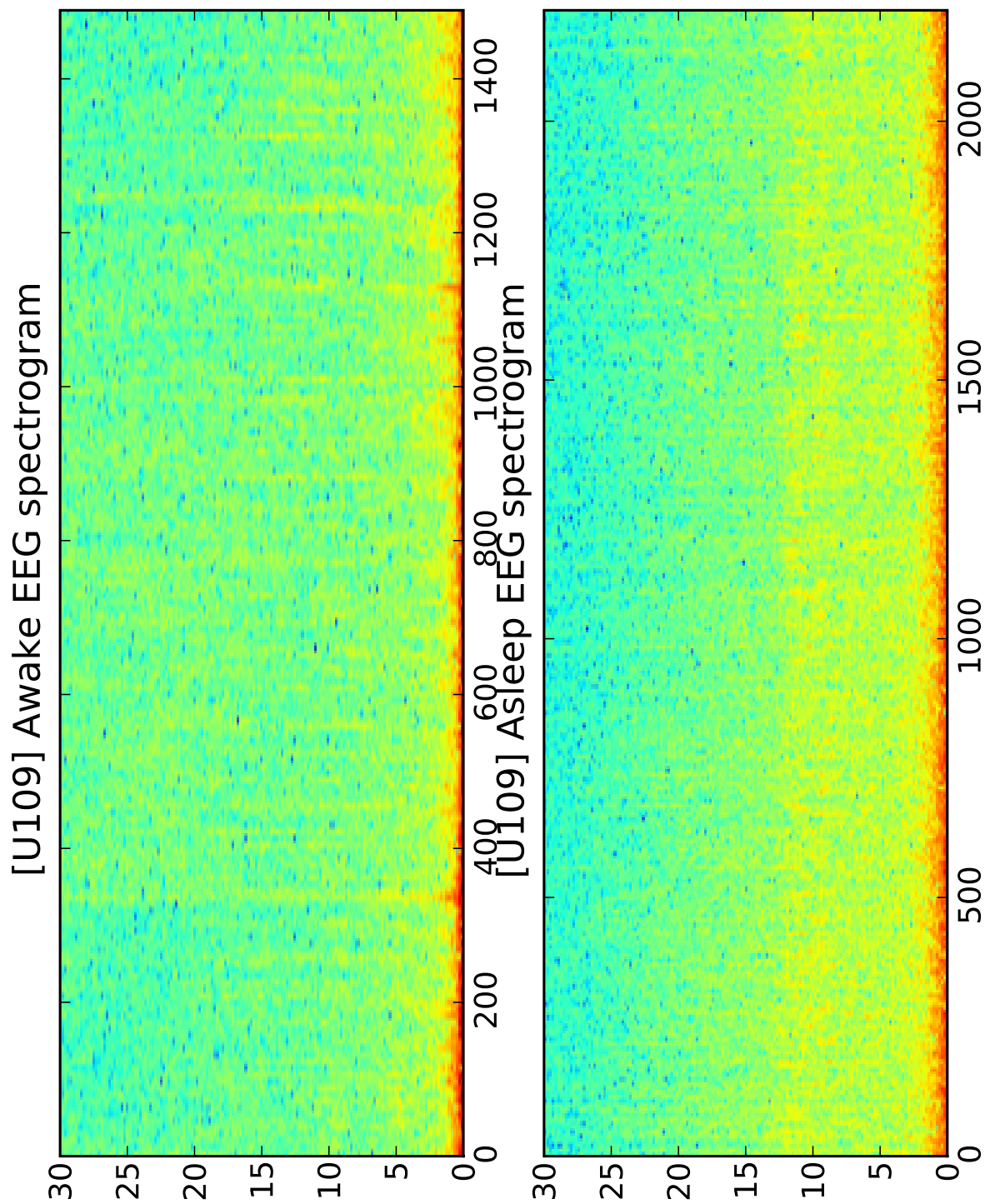


Figure 114: EEG Spectrogram of patient U109

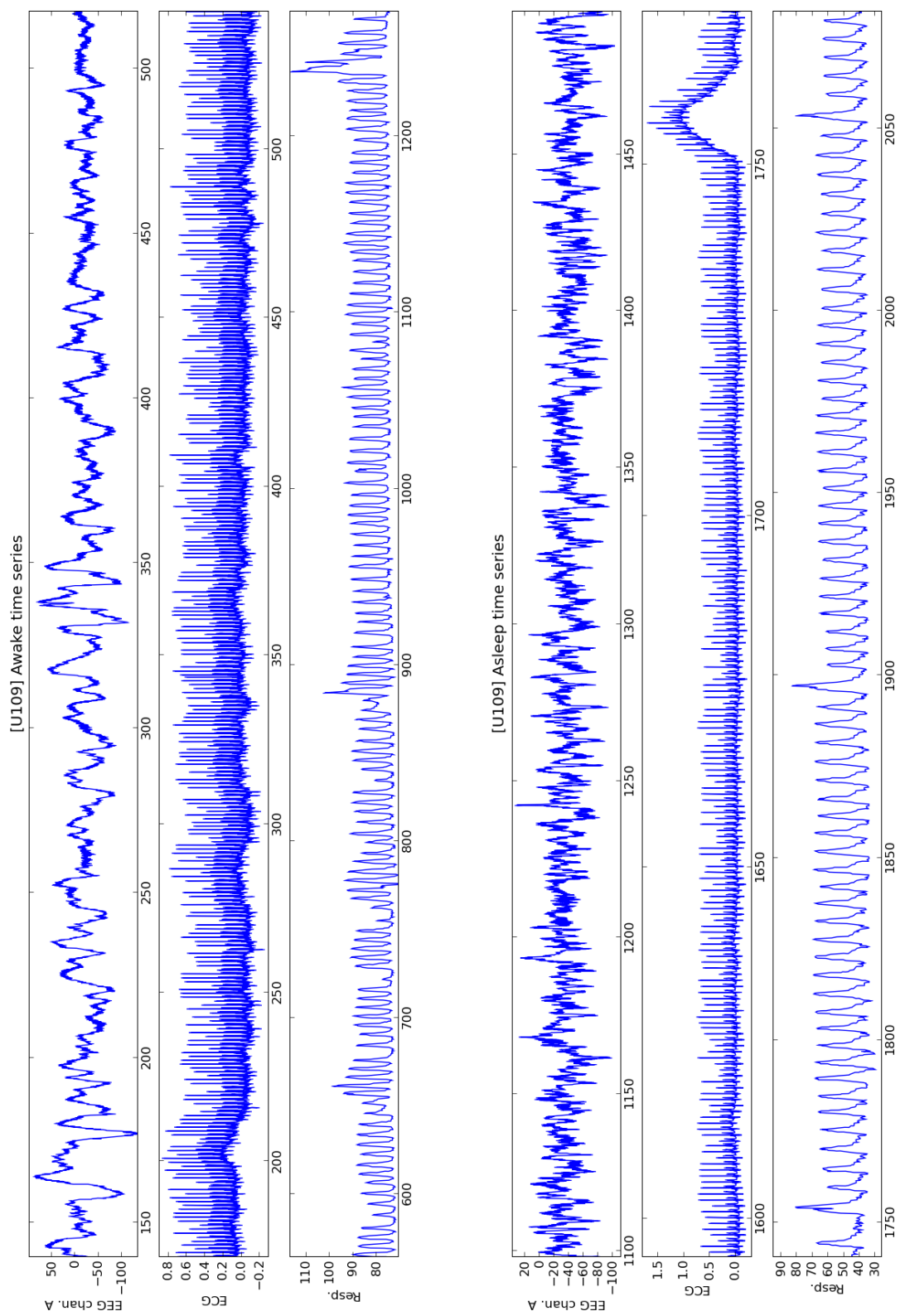


Figure 115: Time series samples of patient U109

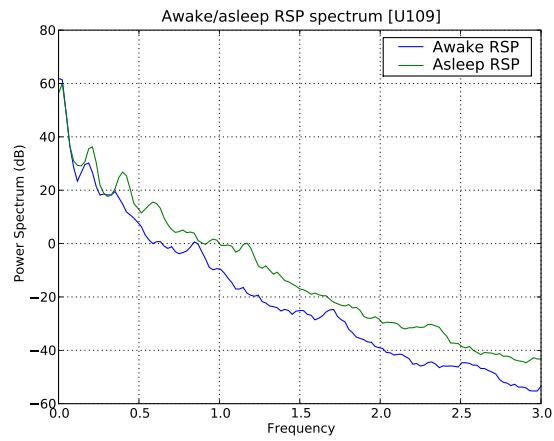
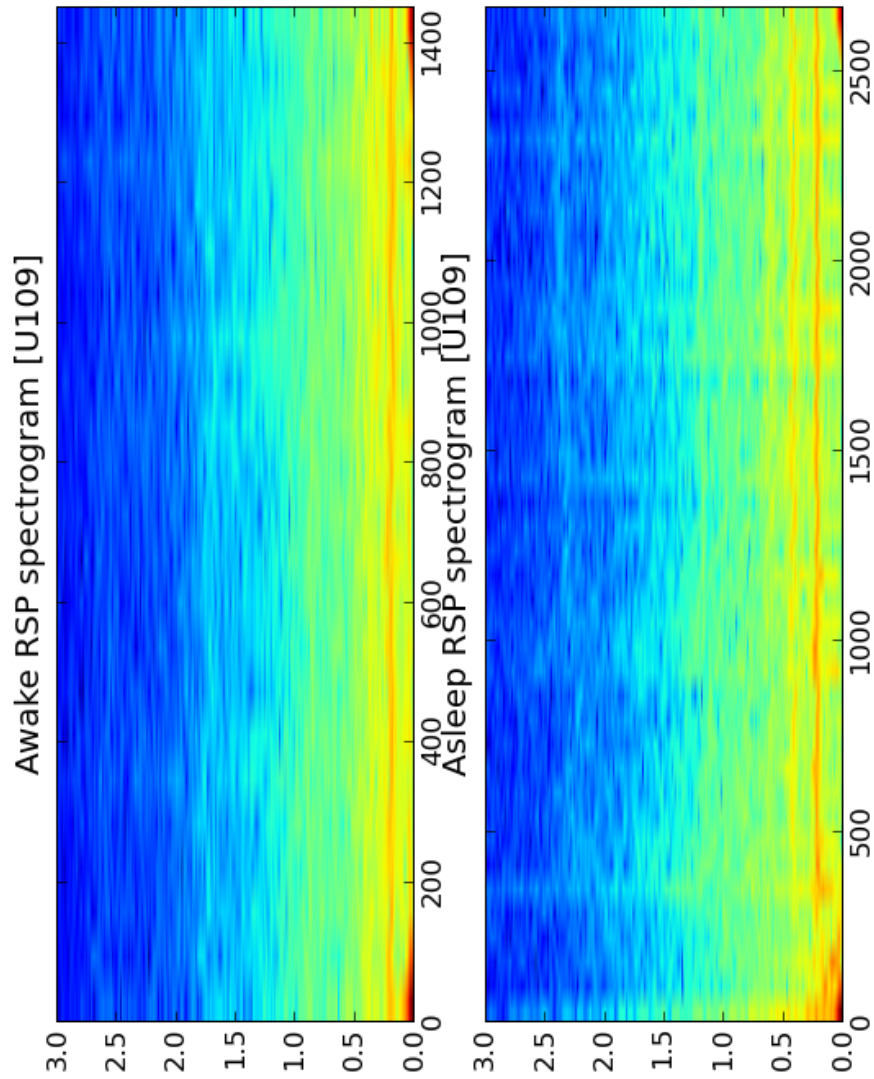


Figure 116: Time series samples of patient U109

3.30 U111

Comments

Sevoflurane was administered. Unusable patient, awake recording is 300s.

Awake EEG Clear signal errors.

Awake ECG Reverse polarity unstable ECG

Awake Respiration Contaminated peaks.

Asleep EEG Clear 11Hz alpha bad activity.

Asleep ECG Reverse polarity ECG, good signal with some baseline instability.

Asleep Respiration Contaminated waveform, sharp but multiple peaks.

Plots

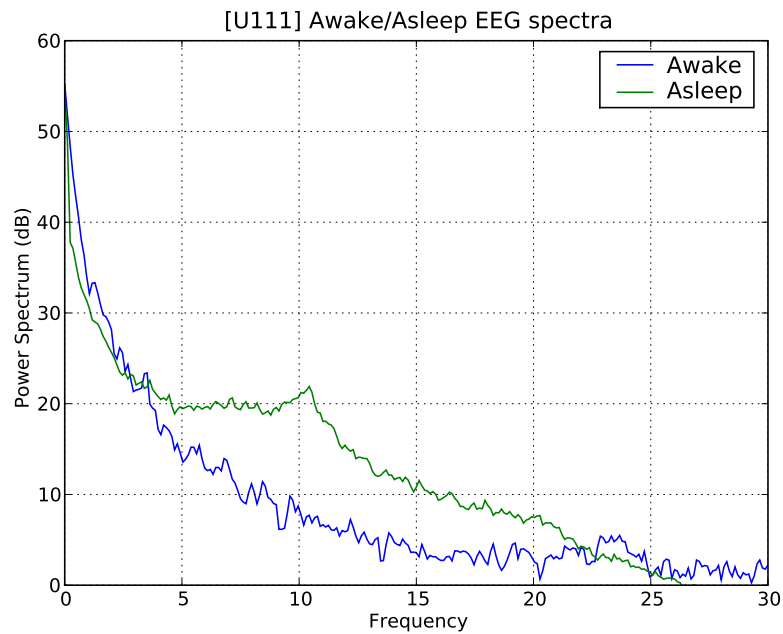


Figure 117: EEG Spectrum of patient U111

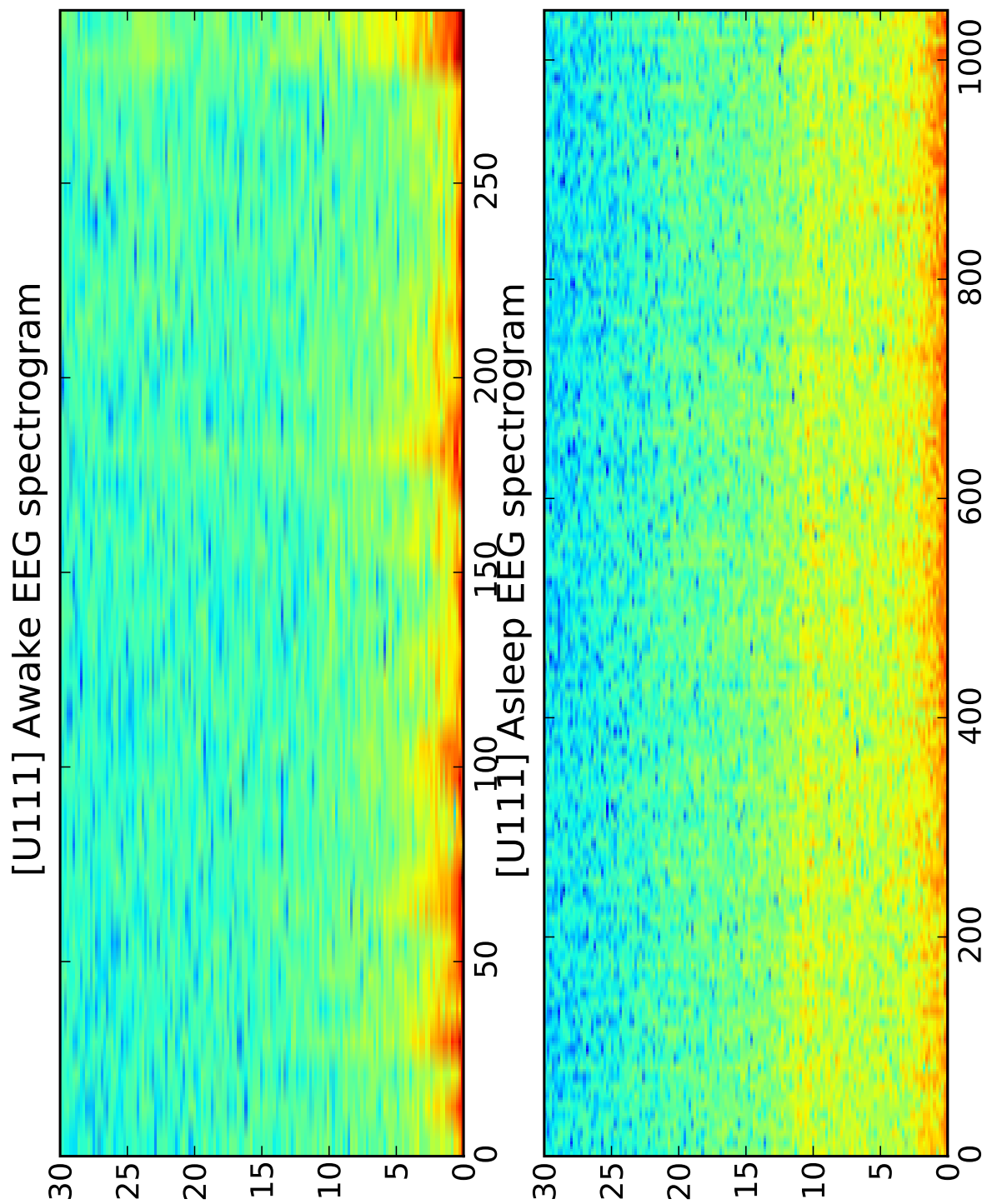


Figure 118: EEG Spectrogram of patient U111

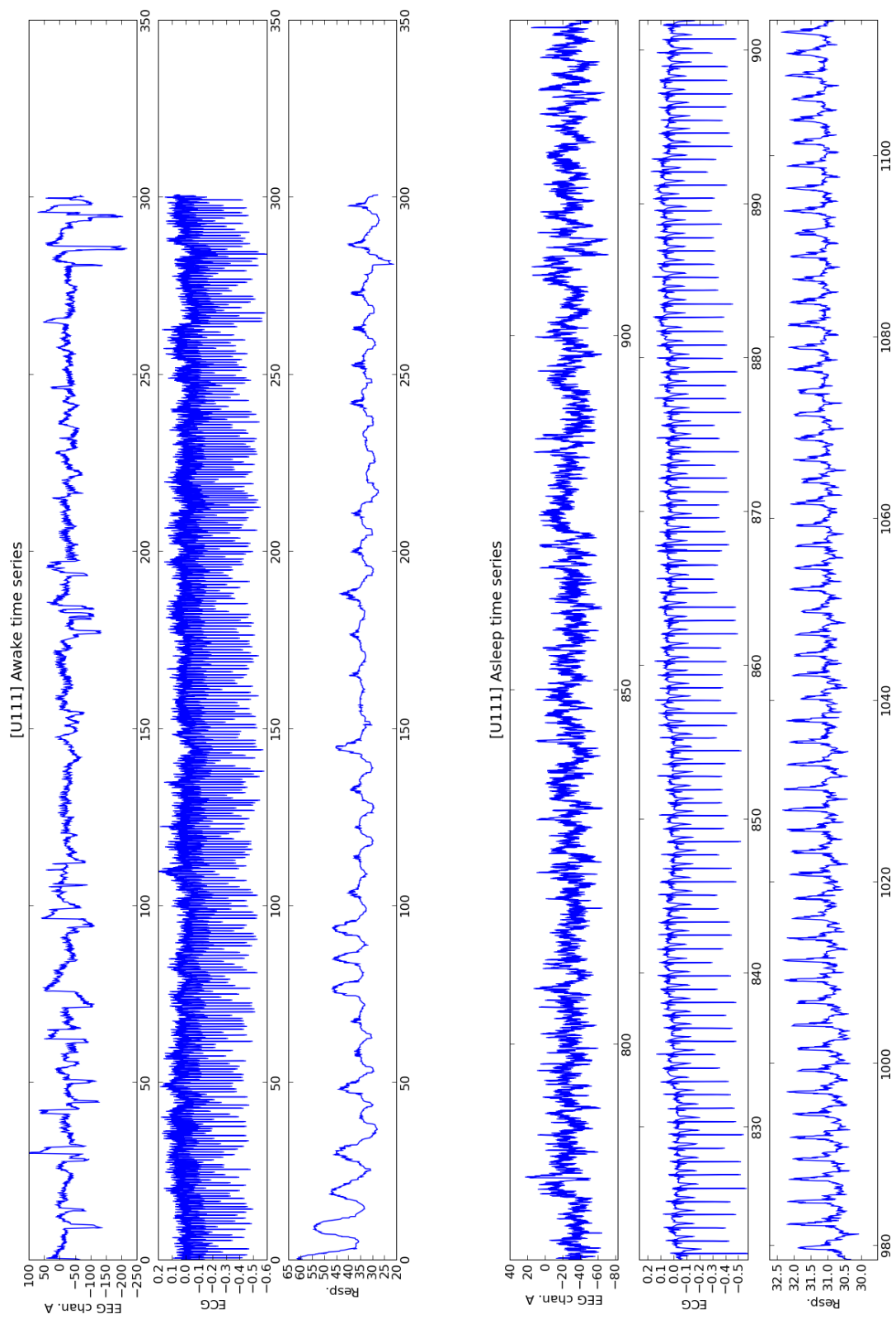


Figure 119: Time series samples of patient U111

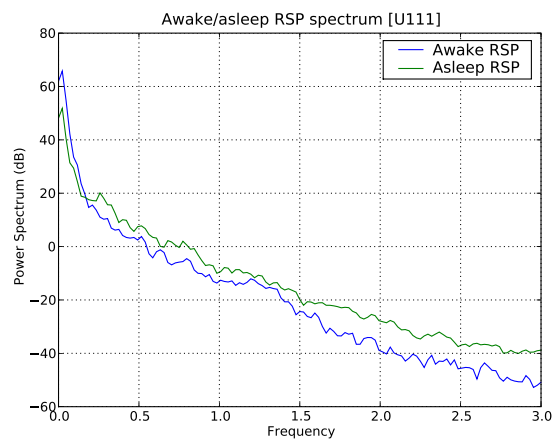
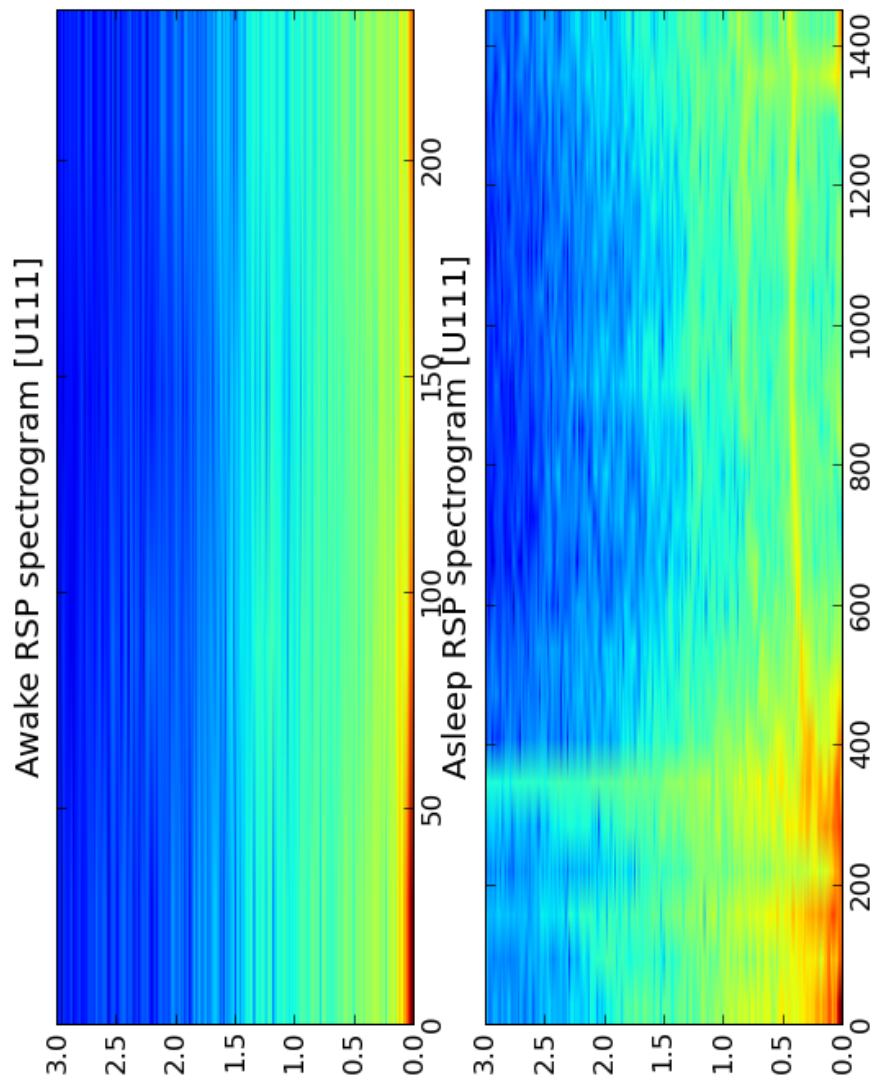


Figure 120: Time series samples of patient U111

3.31 U112

Comments

Sevoflurane with curare was administered. Awake state respiration seems unusable. Asleep state is nicely measured.

Awake EEG Some high amplitude faults. Very low amplitude signal. No clear activity but suspect low power theta/alpha activity at 8Hz.

Awake ECG Unstable baseline with reasonable waveform.

Awake Respiration Intermittent signal losses, some contamination. Two spikes (180s, 1380s). Bad signal.

Asleep EEG Clear 6Hz theta band activity. Suspect 0.5Hz activity in delta band, very low power, somewhat visible in spectrogram.

Asleep ECG Unstable baseline with nice signal.

Asleep Respiration Regular breathing, good waveform.

Plots

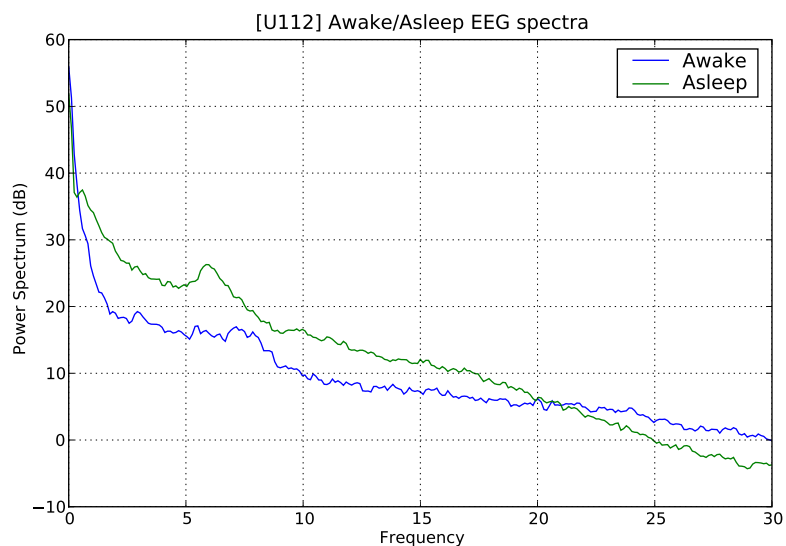


Figure 121: EEG Spectrum of patient U112

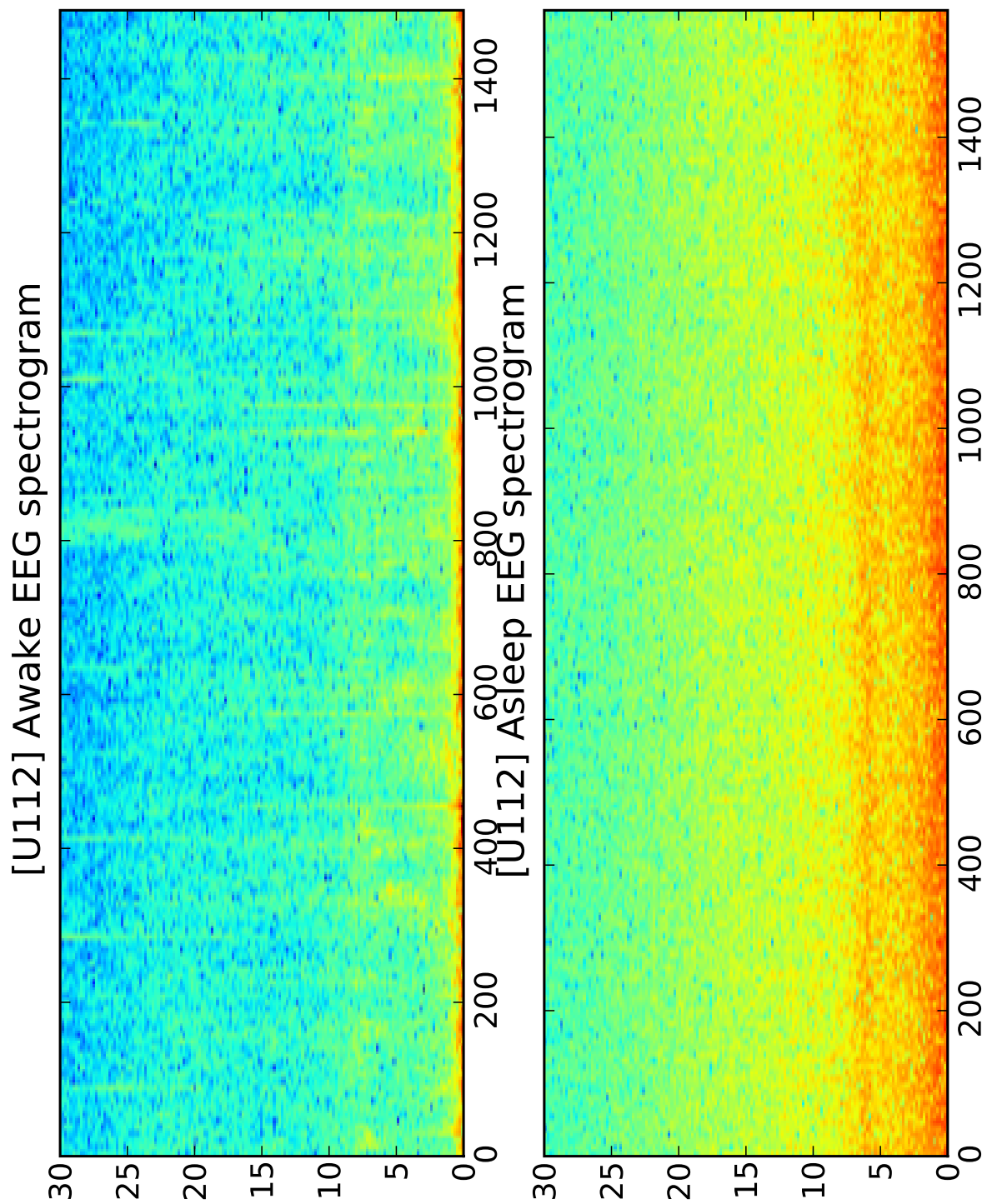


Figure 122: EEG Spectrogram of patient U112

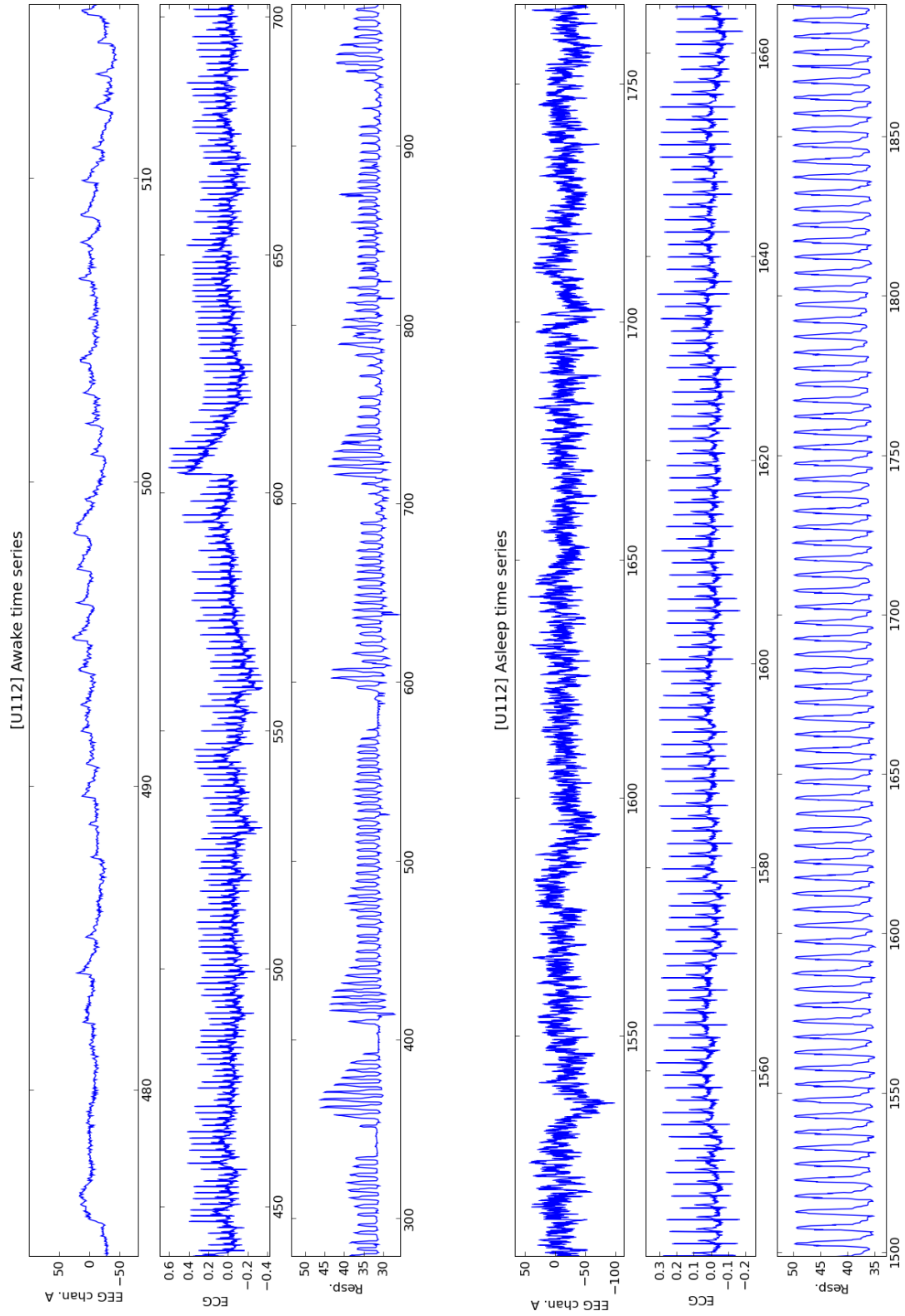


Figure 123: Time series samples of patient U112

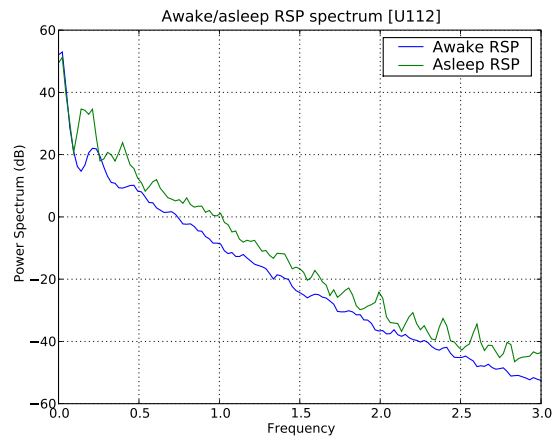
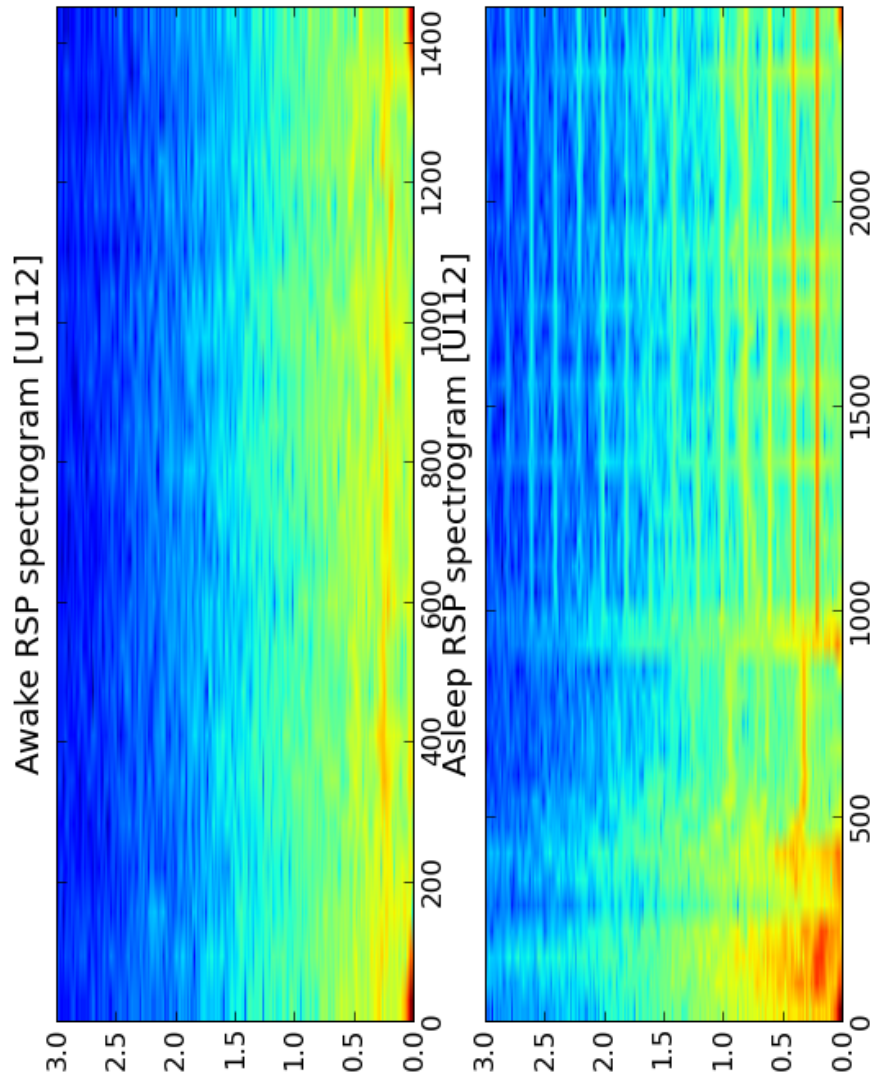


Figure 124: Time series samples of patient U112

3.32 U113

Comments

Propofol was administered. Respiration in awake state may not be clear.

Awake EEG Non-stationary amplitude (higher at end). Suspect 8Hz theta/alpha band activity. Weak 17Hz beta band activity.

Awake ECG Some amplitude instability, good baseline, nice signal.

Awake Respiration Contaminated signal, peaks unclear. Peaks may be shifted.

Asleep EEG Clear alpha band 12Hz activity. Strong 0.3Hz activity of unknown origin.

Asleep ECG Clear signal. Amplitude variations.

Asleep Respiration Clear signal, peaked sharp waveform. Slightly contaminated valleys.

Plots

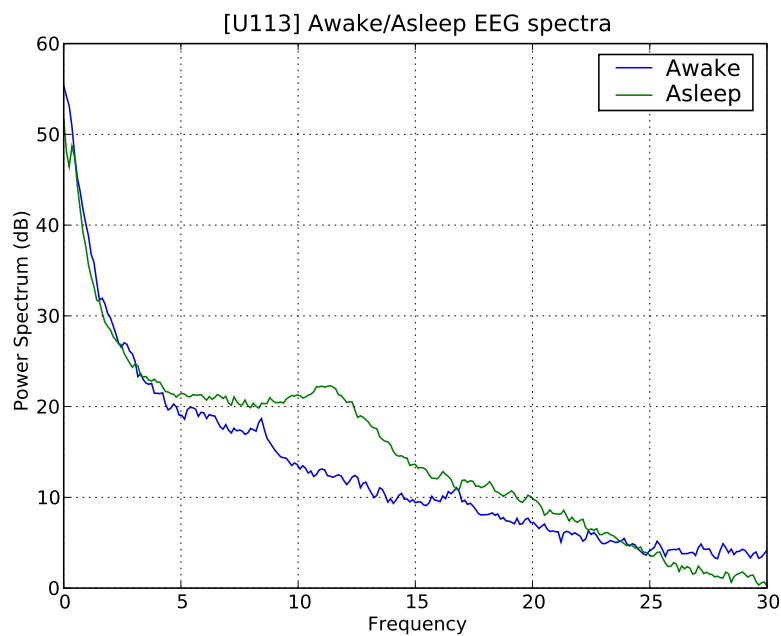


Figure 125: EEG Spectrum of patient U113

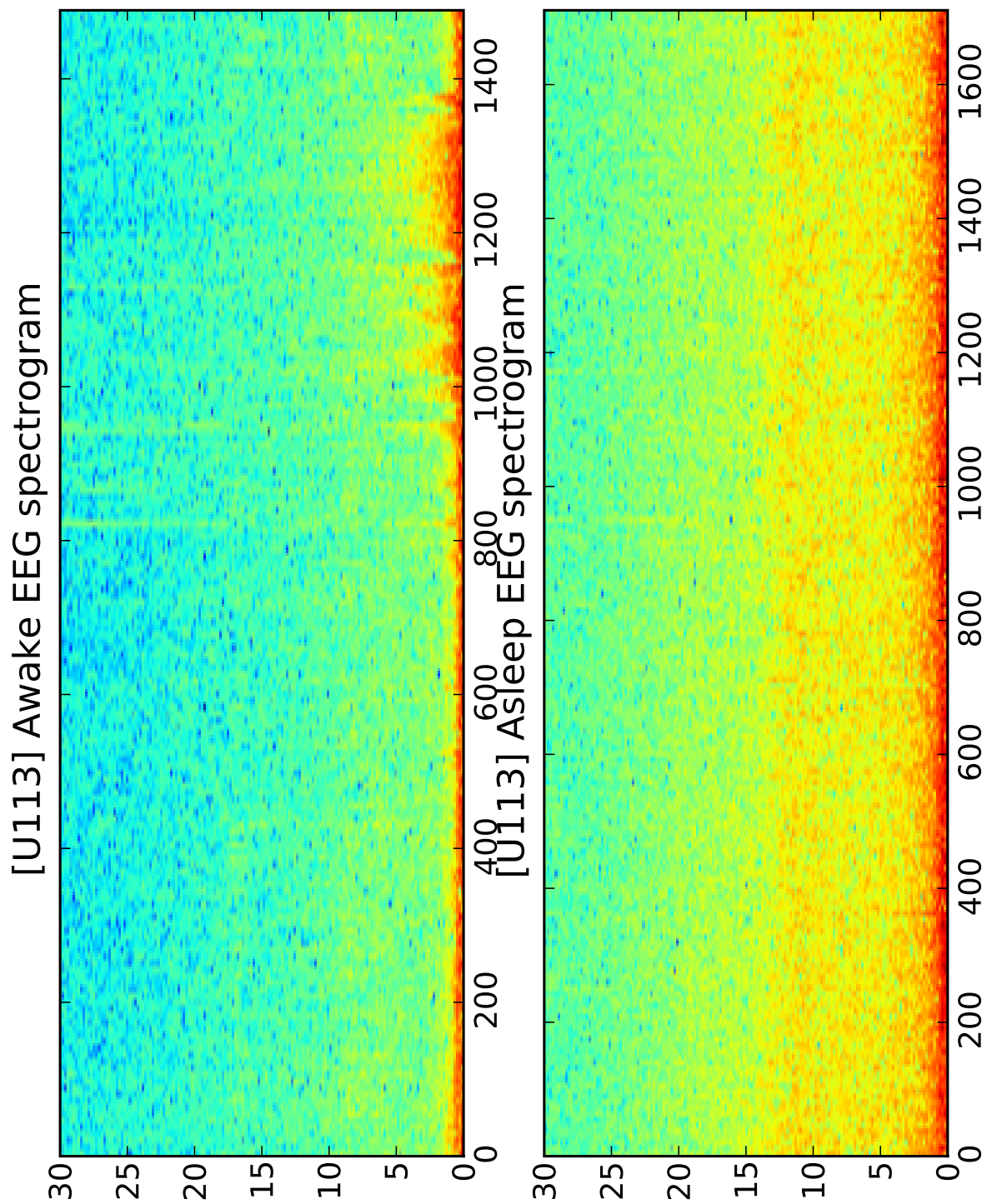


Figure 126: EEG Spectrogram of patient U113

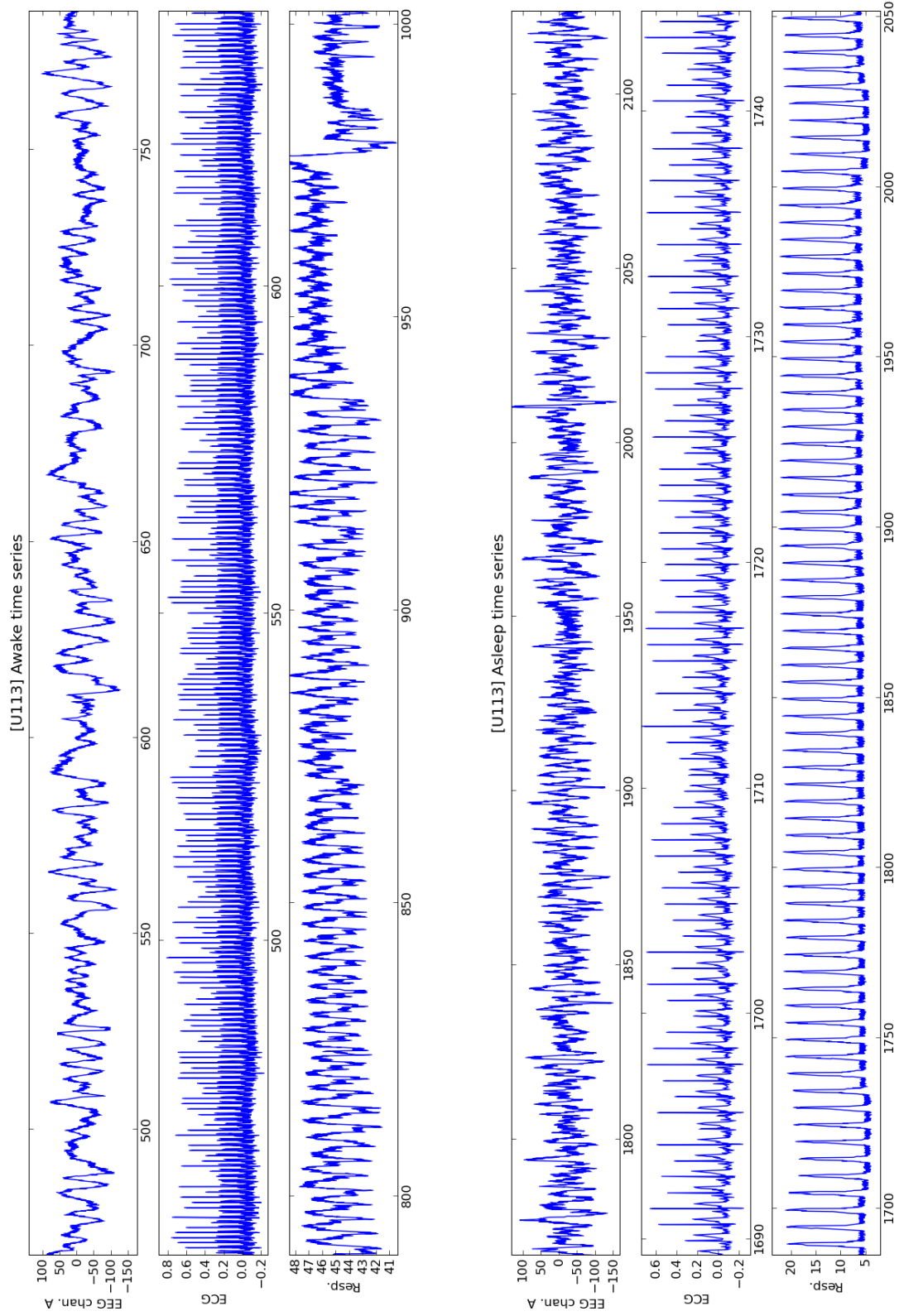


Figure 127: Time series samples of patient U113

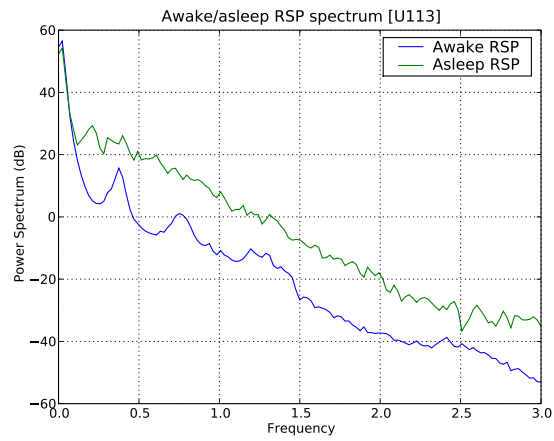
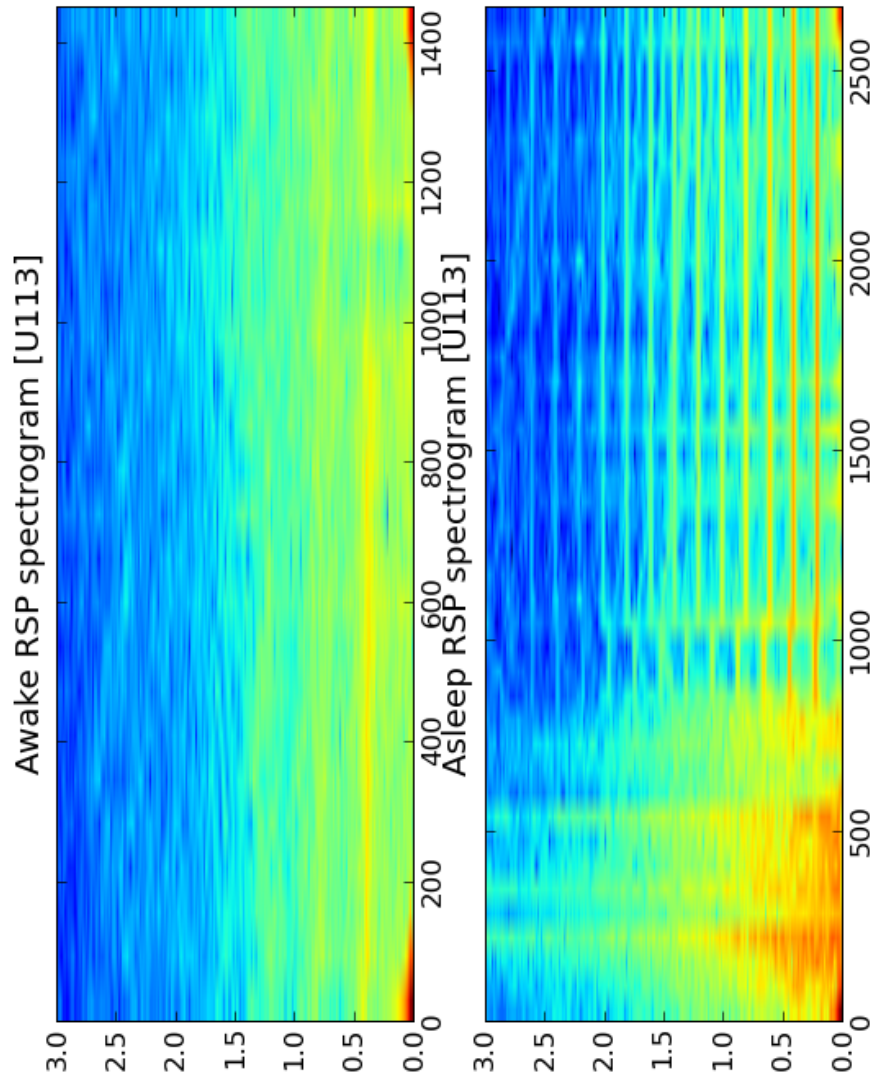


Figure 128: Time series samples of patient U113

3.33 U114

Comments

Sevoflurane was administered. Awake state respiration might be unusable.

Awake EEG Nonstandard waveform. Higher power at end of signal. No clear activity. Suspect not EEG (connection, sensors?).

Awake ECG Clear waveform, stable baseline.

Awake Respiration Noise contaminated waveform. Some signal losses. Bad quality.

Asleep EEG Clear 8Hz alpha/theta activity. Clear signal.

Asleep ECG Some baseline instability, good signal.

Asleep Respiration Some noise contamination, peaked signal, good quality.

Plots

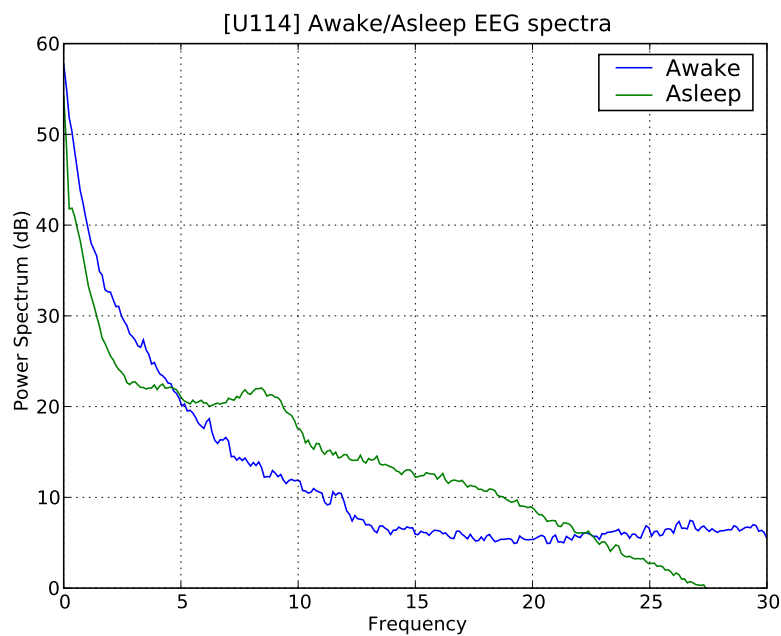


Figure 129: EEG Spectrum of patient U114

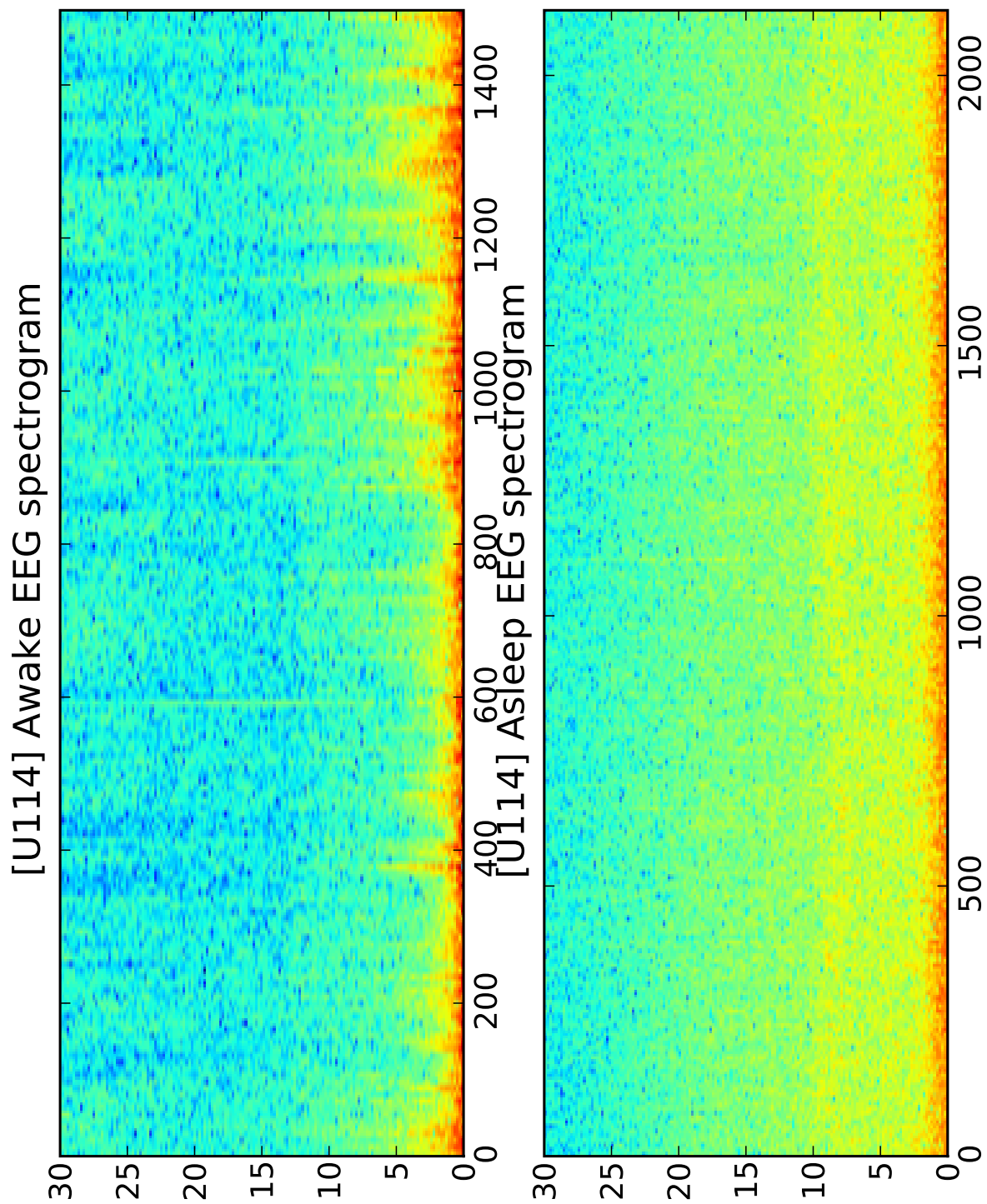


Figure 130: EEG Spectrogram of patient U114

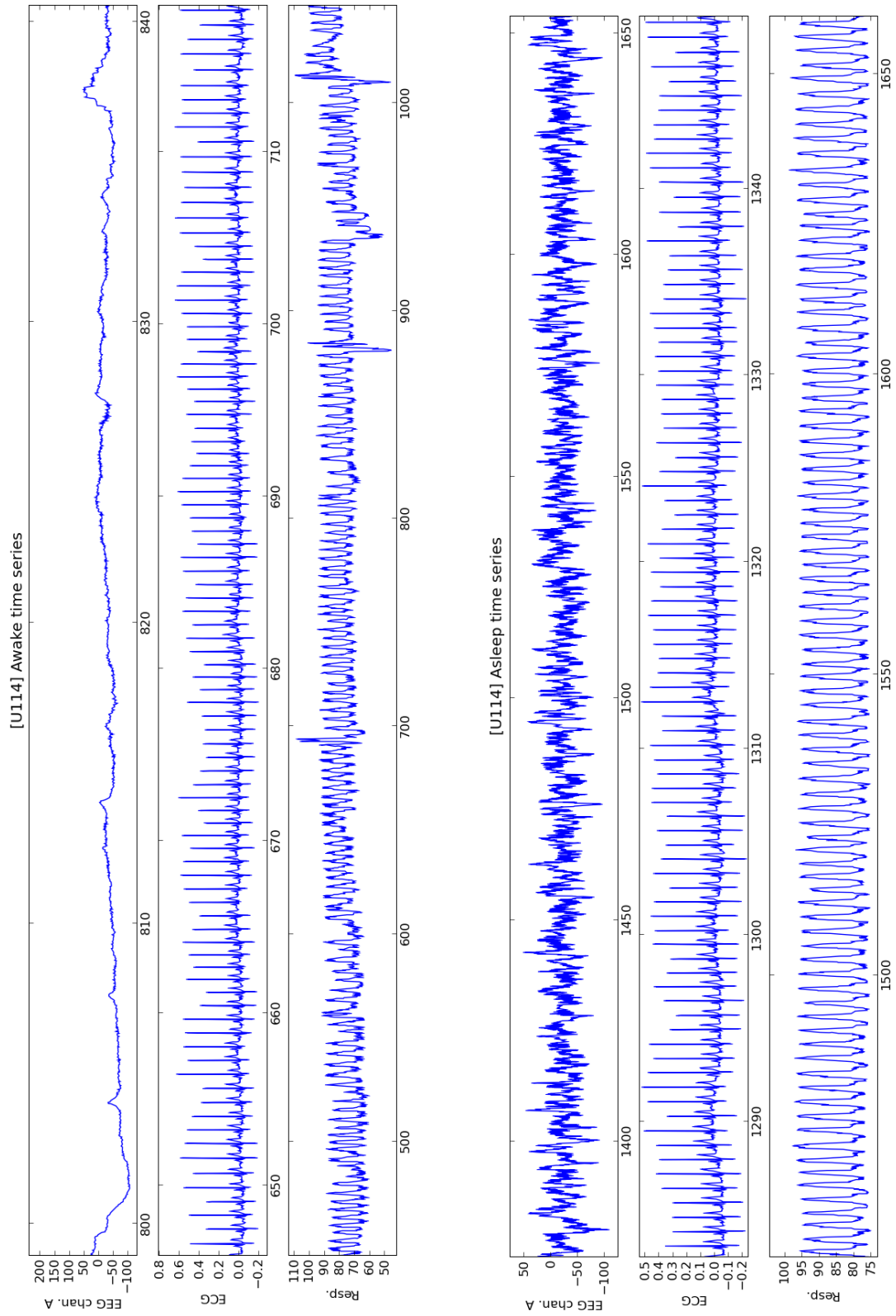


Figure 131: Time series samples of patient U114

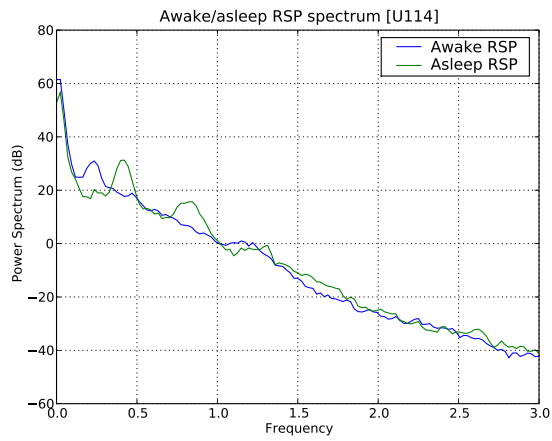
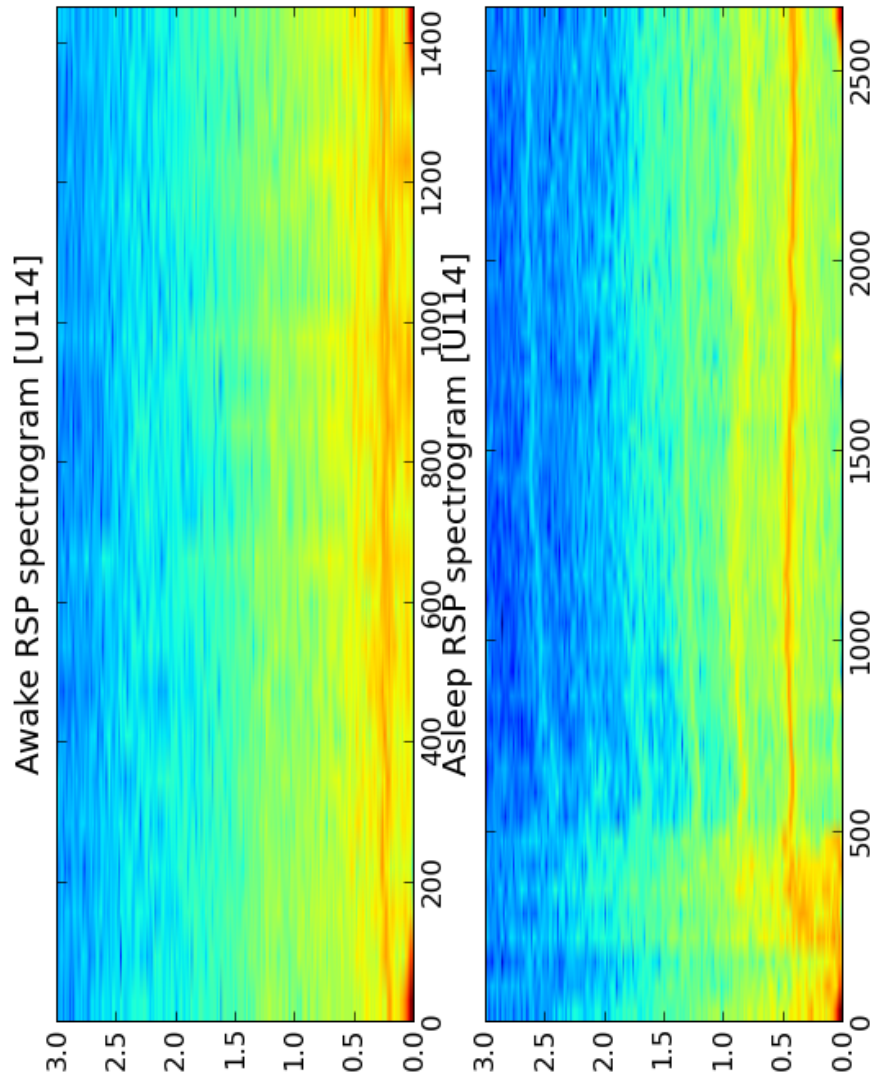


Figure 132: Time series samples of patient U114

3.34 U115

Comments

Propofol with curare was administered. Awake EEG is highly suspect, not understood.

Awake EEG Very nonstandard EEG signal. Spectrum shows some theta 6Hz. Possibly 12Hz activity in alpha band.

Awake ECG Clean signal, low baseline instability.

Awake Respiration Some signal losses, otherwise reasonable waveform. Contamination of valleys.

Asleep EEG High amp. spike at 1300s. Otherwise clean waveform. Well-defined activity at 11-12Hz.

Asleep ECG Isolated baseline instability, good signal.

Asleep Respiration Oscillations in valleys, clear peaks. Good signal.

Plots

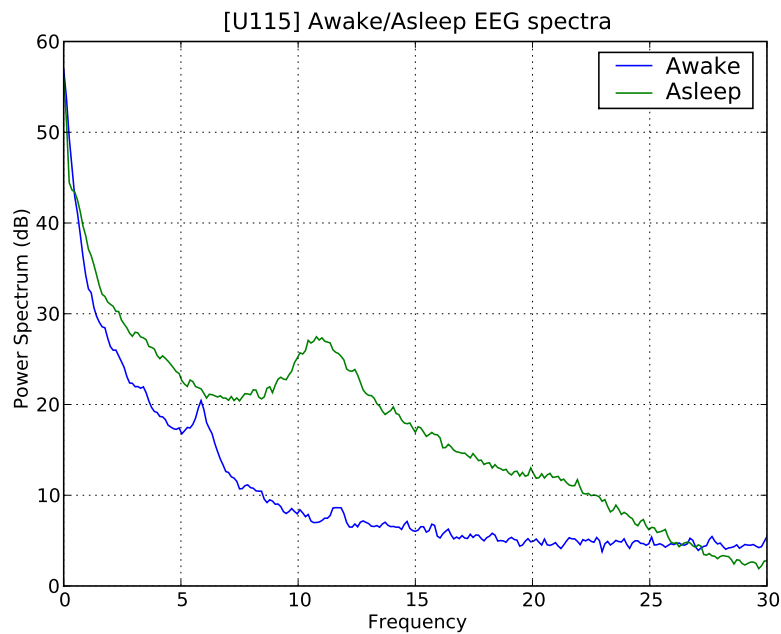


Figure 133: EEG Spectrum of patient U115

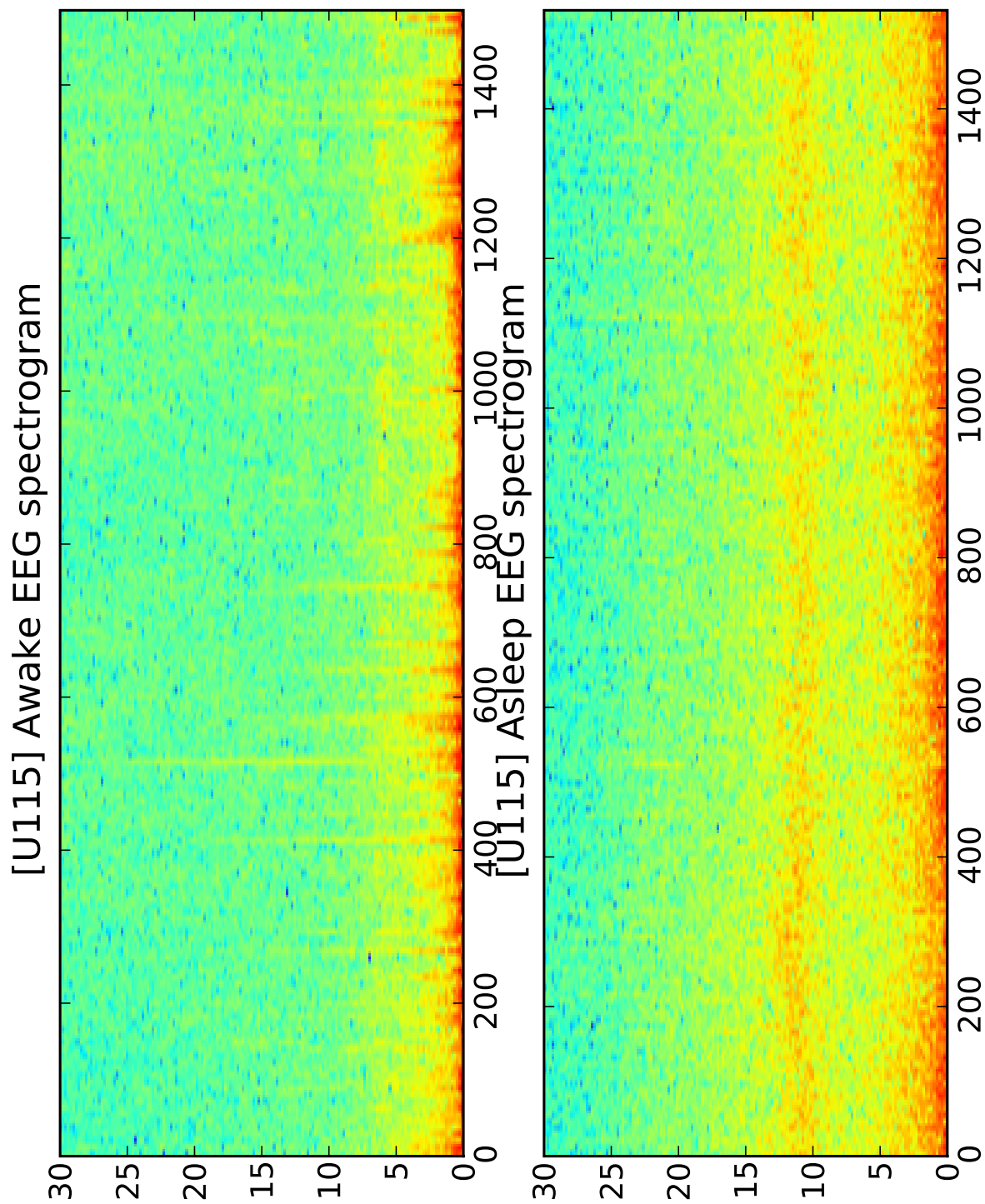


Figure 134: EEG Spectrogram of patient U115

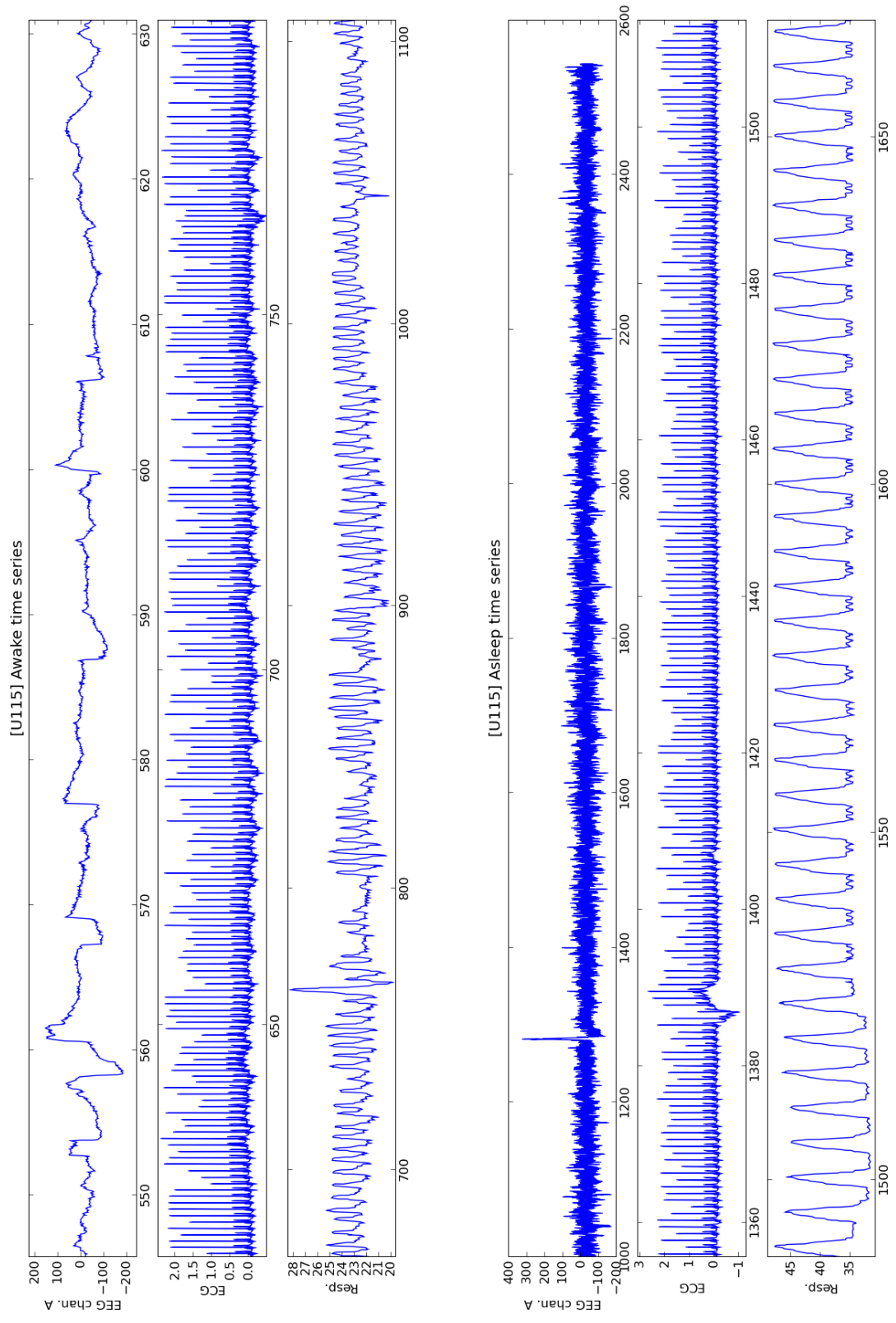


Figure 135: Time series samples of patient U115

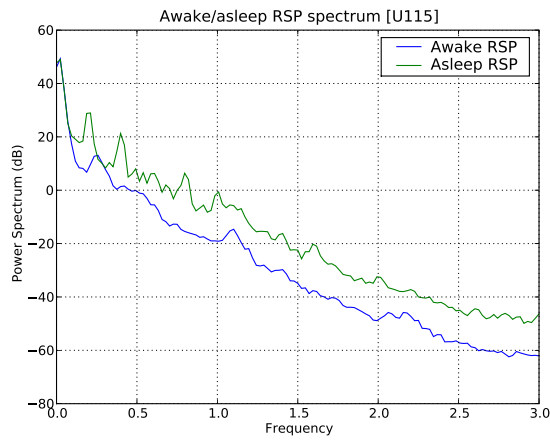
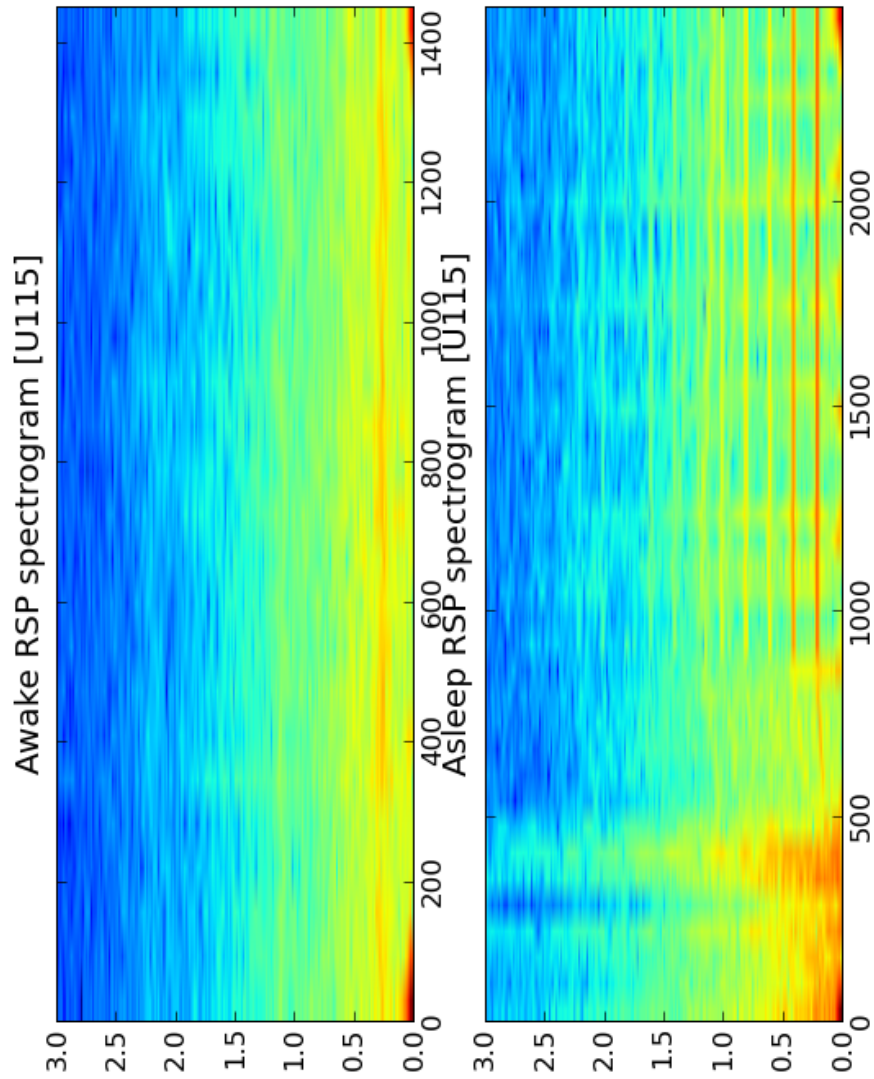


Figure 136: Time series samples of patient U115

3.35 U116

Comments

Sevoflurane was administered. Awake EEG may be unusable. Awake respiration is quite bad in some places.

Awake EEG High amplitude contamination. Signal waveform not clear.

Awake ECG Clear signal. Isolated signal losses.

Awake Respiration Unstable nonsymmetric peaks, contamination in valleys. Long signal loss at 550s. Amplitude instability. Bad quality.

Asleep EEG Clear 10Hz alpha activity. Delta band 0.5Hz activity, low power.

Asleep ECG Clear signal. Bipolar R peaks.

Asleep Respiration Amplitude variation, clean peaked waveform.

Plots

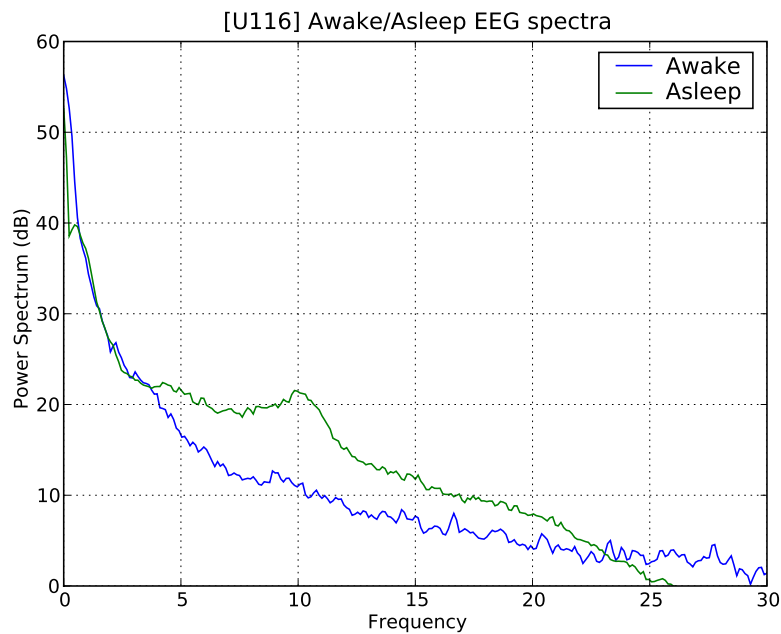


Figure 137: EEG Spectrum of patient U116

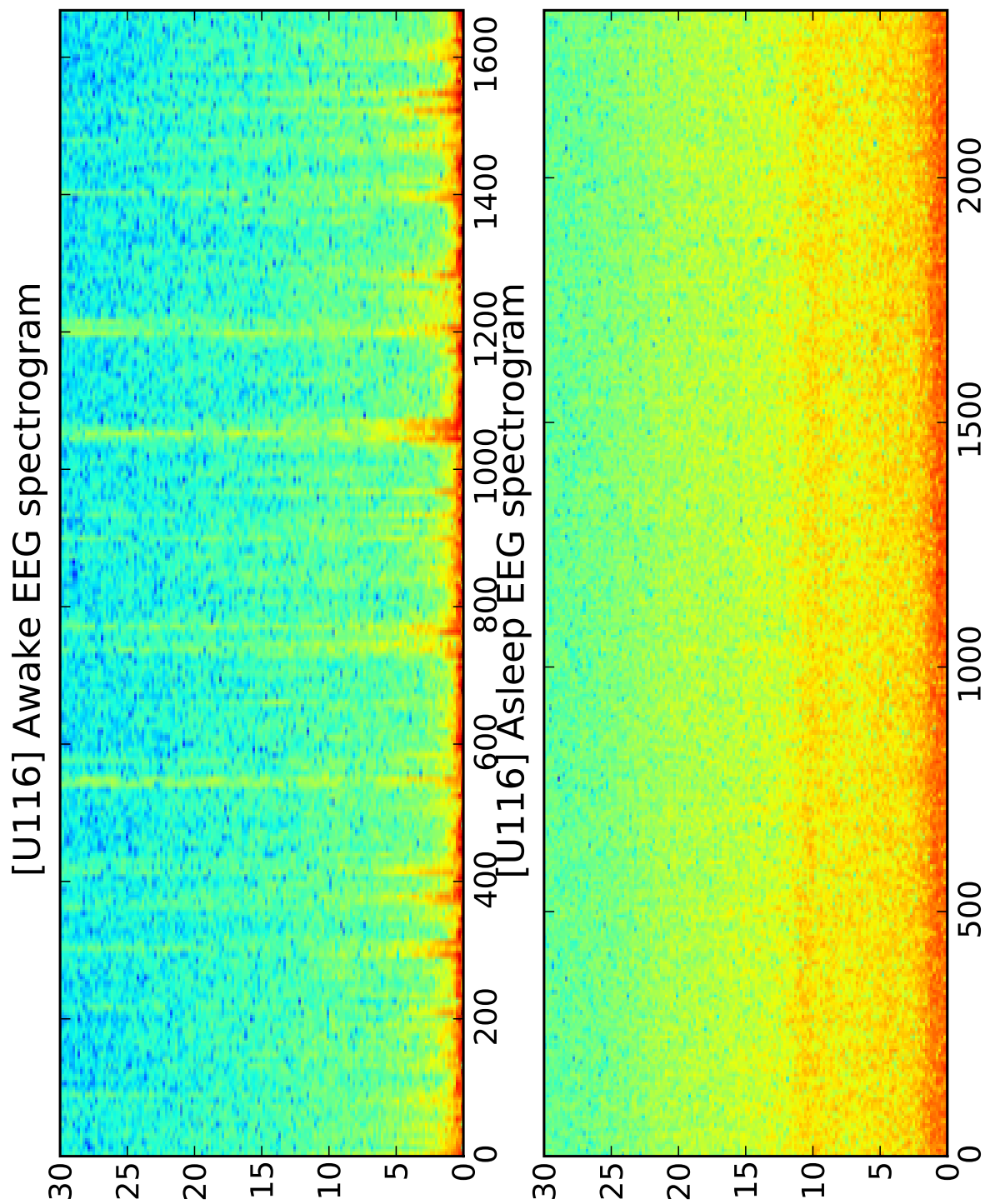


Figure 138: EEG Spectrogram of patient U116

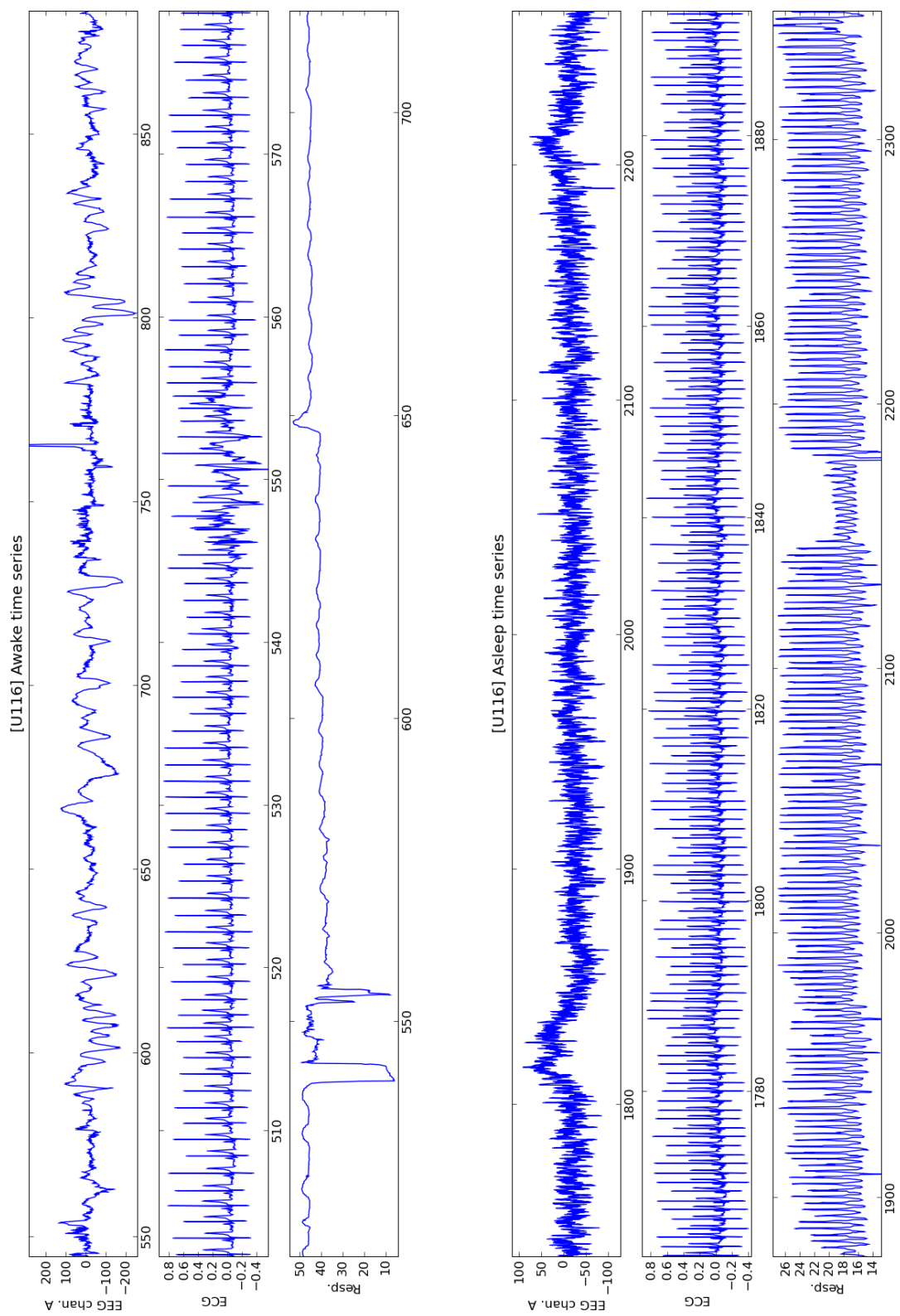


Figure 139: Time series samples of patient U116

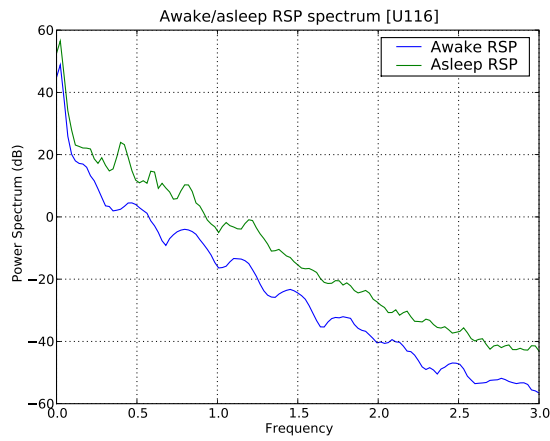
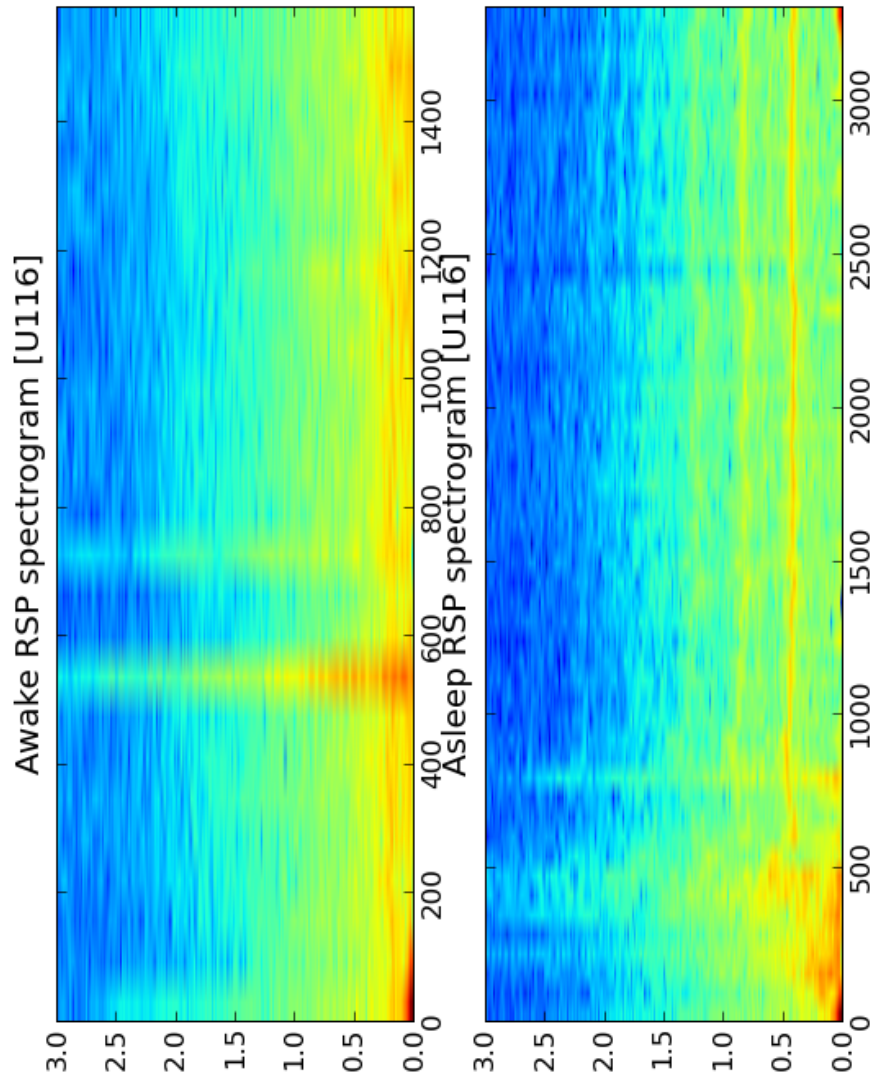


Figure 140: Time series samples of patient U116

3.36 U117

Comments

Propofol was administered. Respiration and EEG may be unreliable.

Awake EEG No clear activity. Signal waveform does not look like EEG in many places.

Awake ECG Clear signal with stable baseline.

Awake Respiration Very bad signal with intermittent losses in many occasions.

Asleep EEG Low amplitude signal. Clear alpha band 10Hz activity in spectrum.

Asleep ECG Clear signal with stable baseline.

Asleep Respiration Some noise contamination of peaks. Peaks may be shifted.

Plots

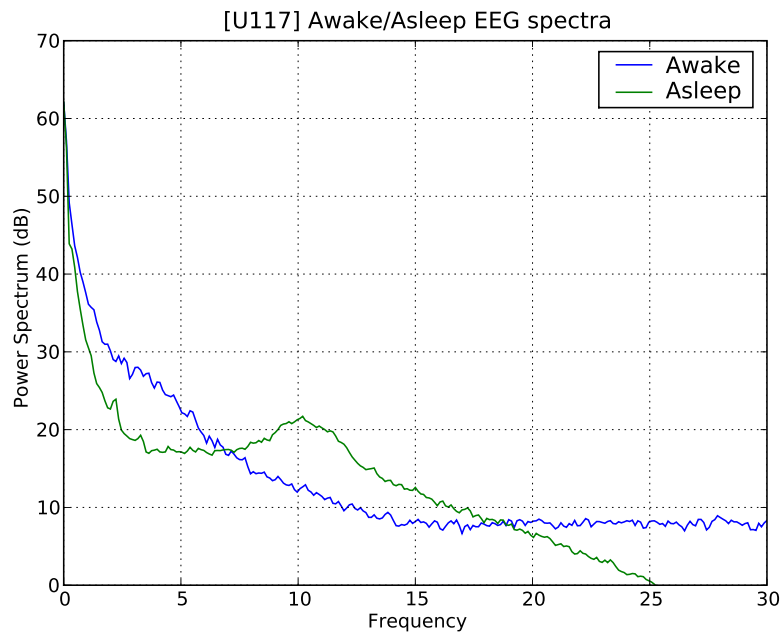


Figure 141: EEG Spectrum of patient U117

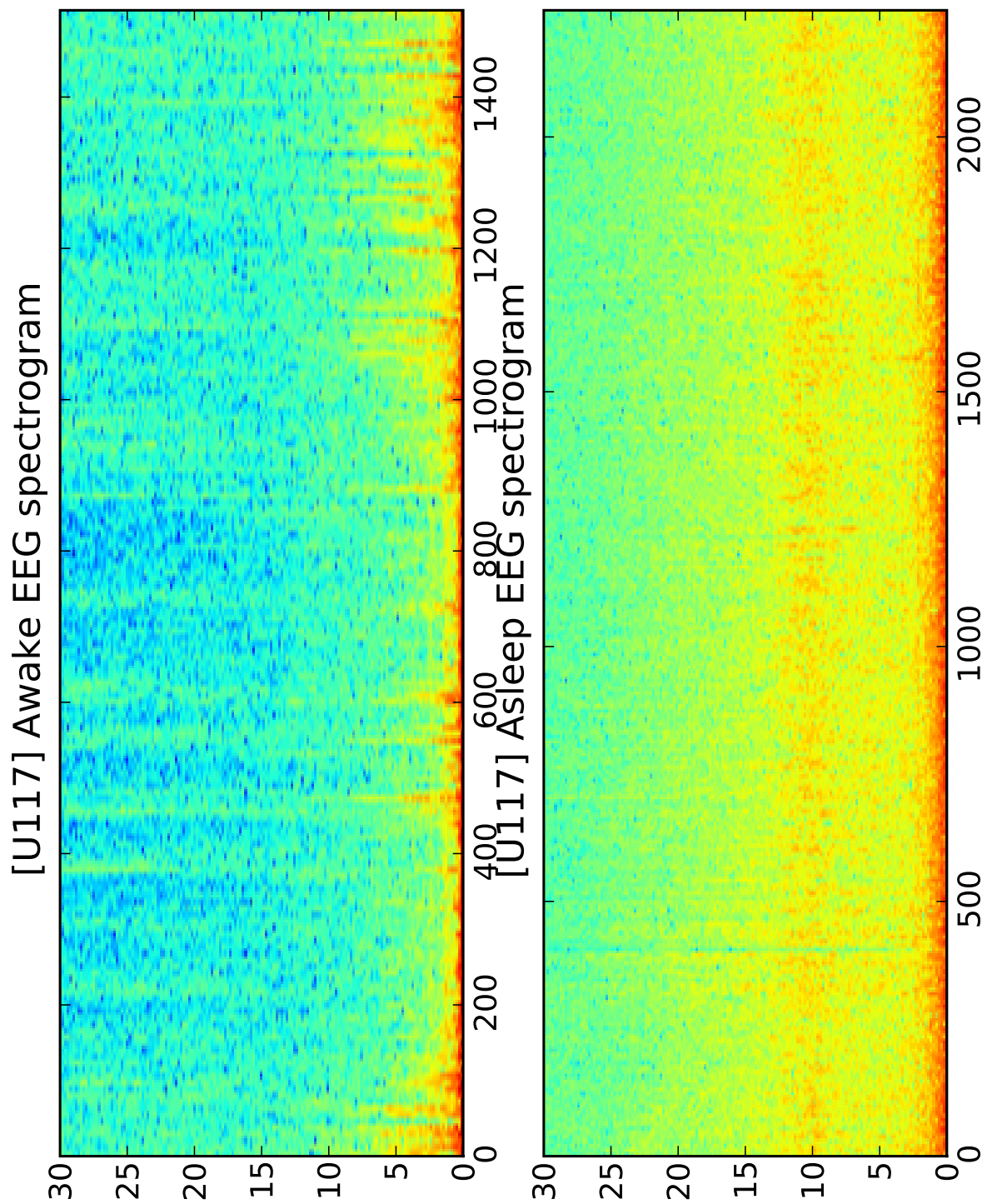


Figure 142: EEG Spectrogram of patient U117

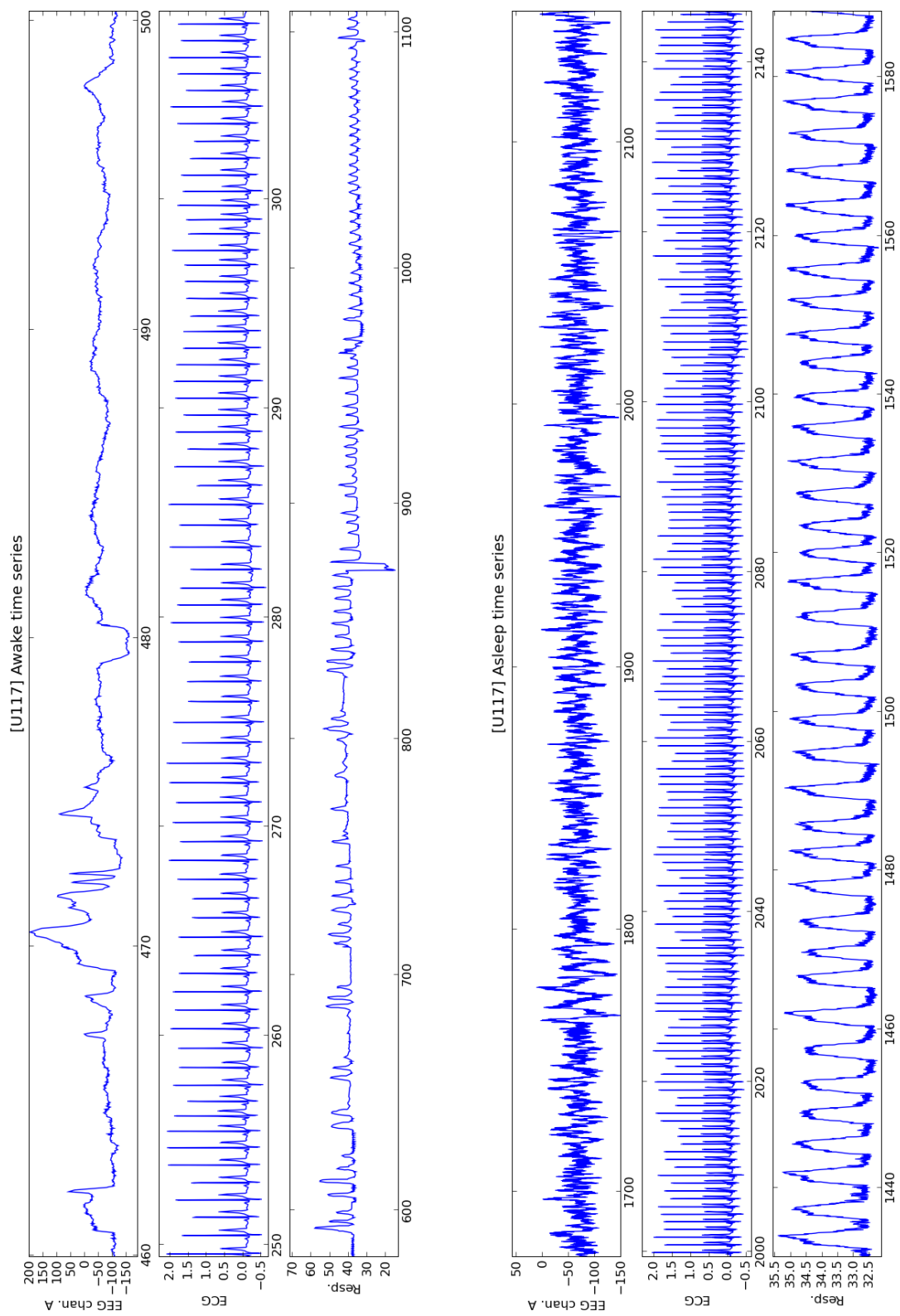


Figure 143: Time series samples of patient U117

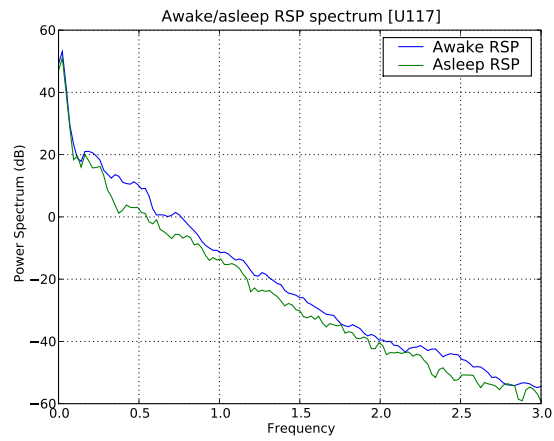
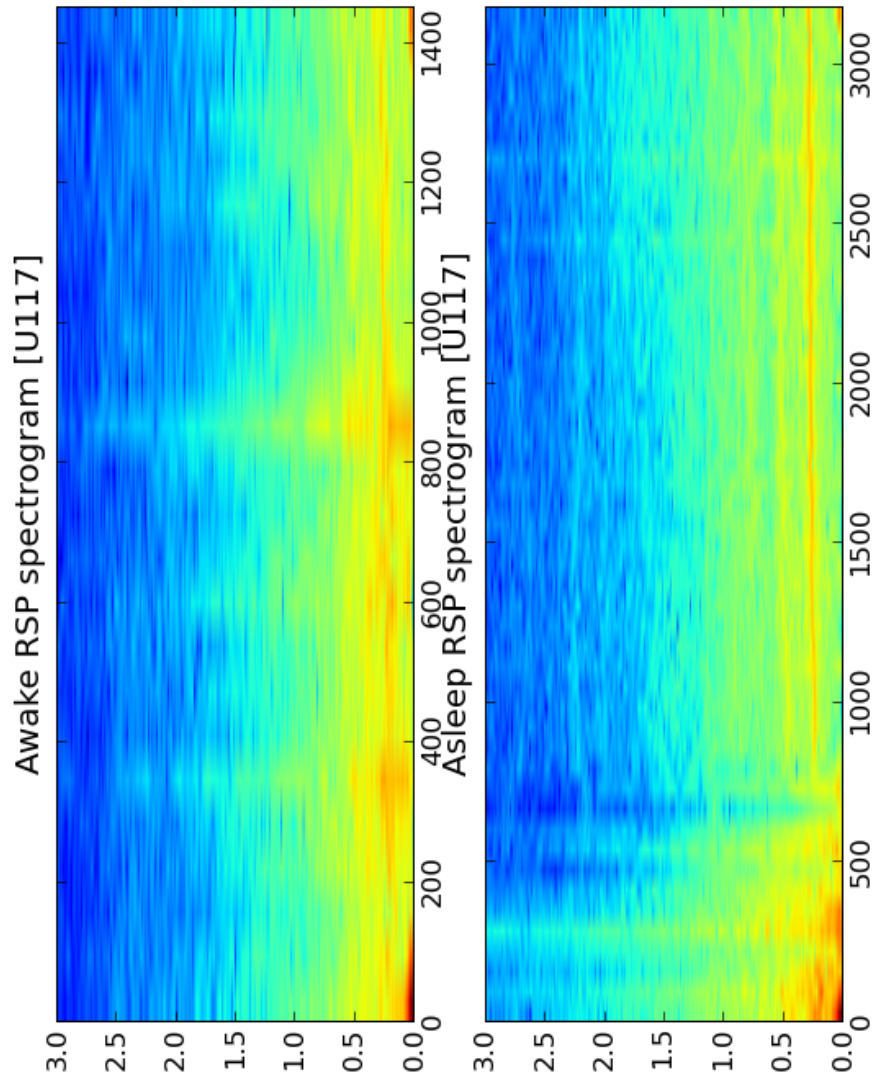


Figure 144: Time series samples of patient U117

3.37 U118

Comments

Propofol with curare was administered. Patient may be unusable, contamination in multiple time series (awake ECG, asleep RSP).

Awake EEG Waveform does not resemble EEG in many segments.

Awake ECG Highly unstable baseline, noise contamination.

Awake Respiration Unreliable waveform in some places. Mostly clean peaks.

Asleep EEG Clear 12Hz activity in alpha band.

Asleep ECG Unstable baseline, reverse polarity R peak, low frequency peaks (!).

Asleep Respiration Peaked sharp waveform, noise contamination in baseline.

Plots

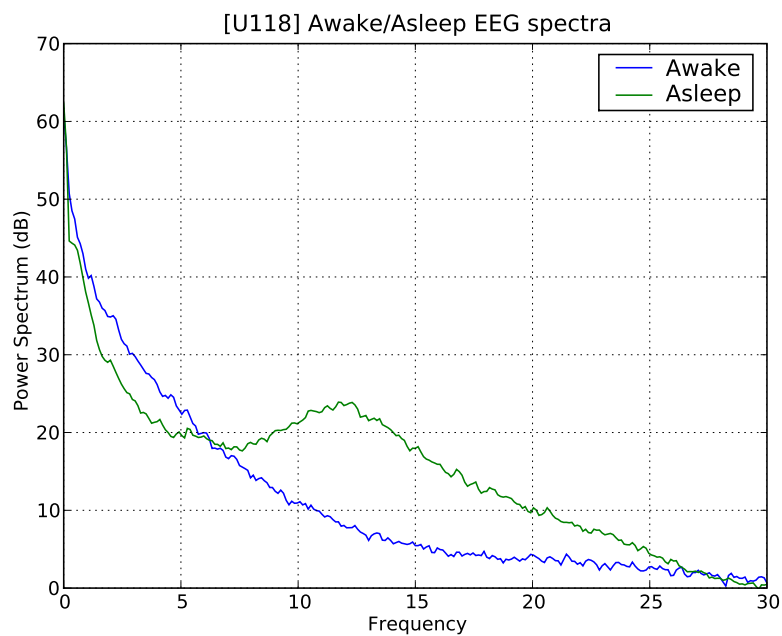


Figure 145: EEG Spectrum of patient U118

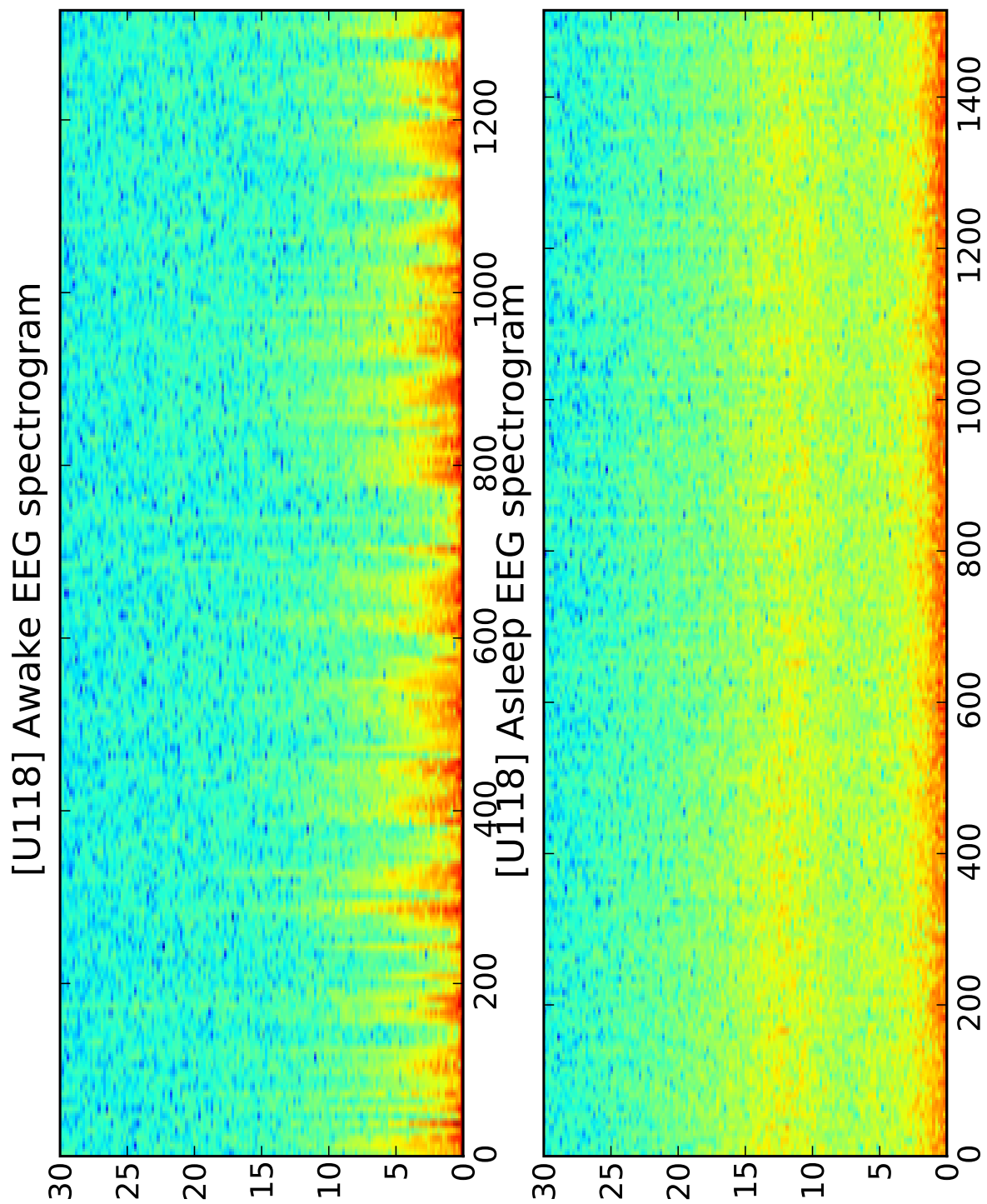


Figure 146: EEG Spectrogram of patient U118

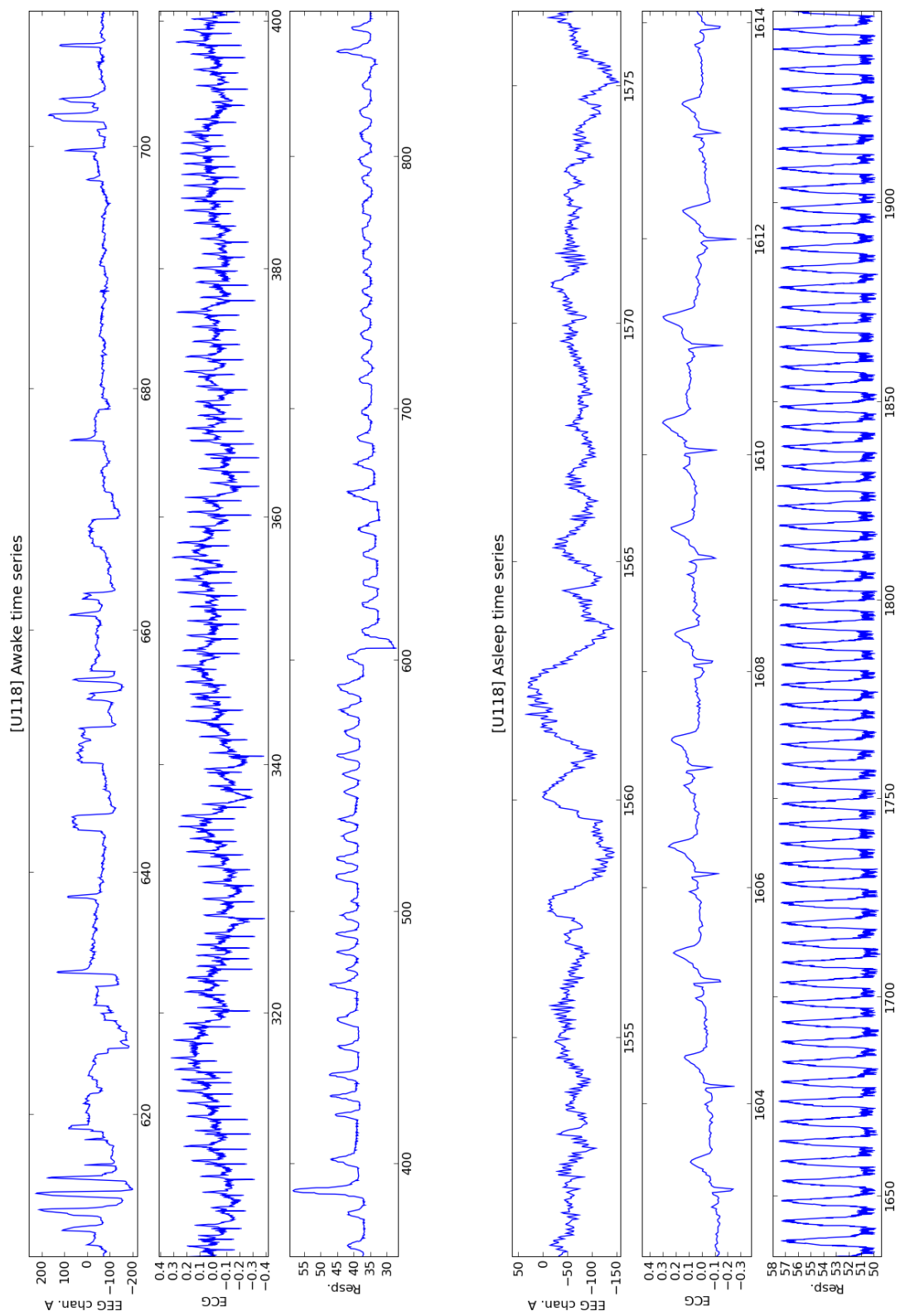


Figure 147: Time series samples of patient U118

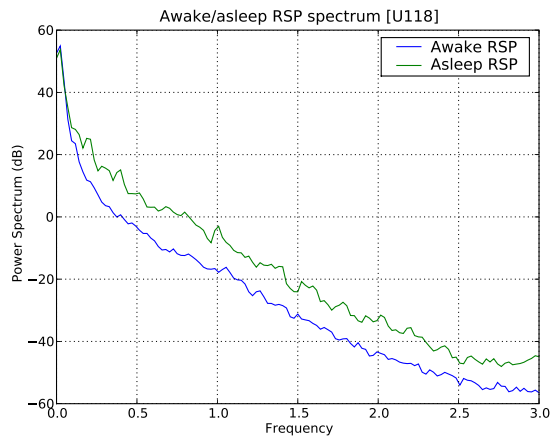
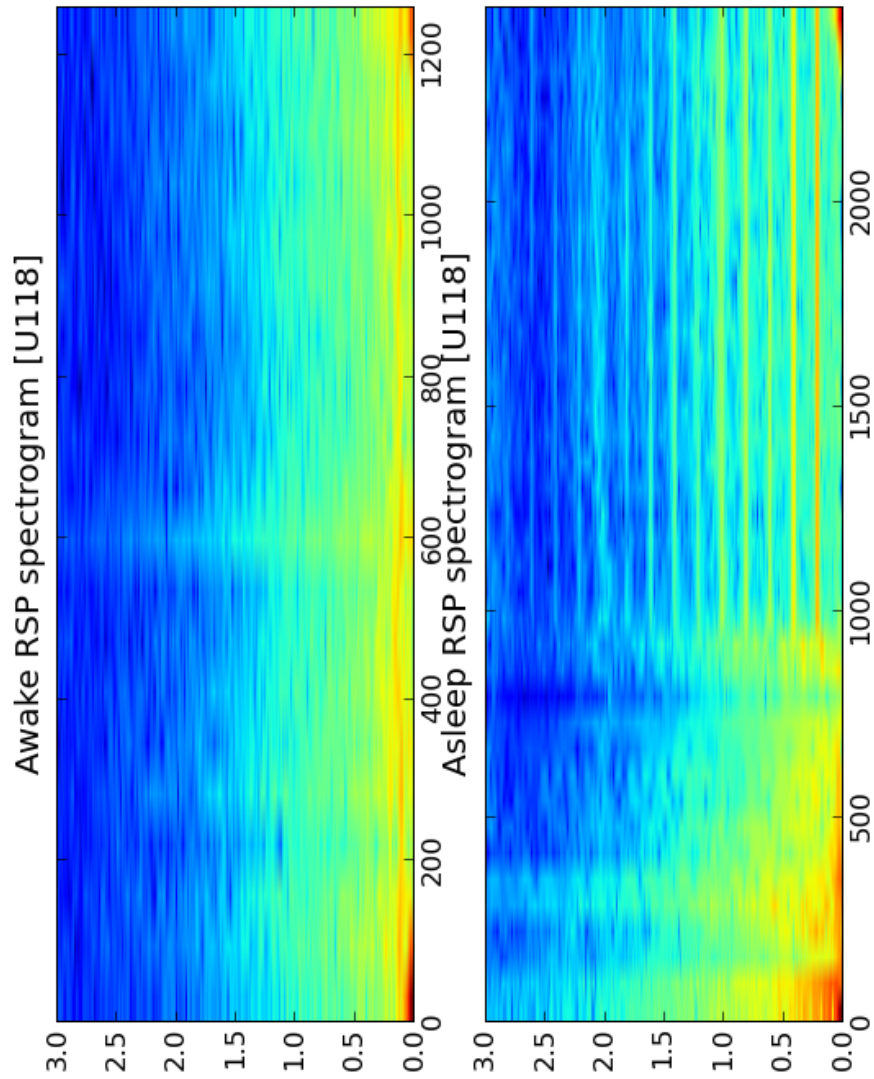


Figure 148: Time series samples of patient U118

3.38 U119

Comments

Sevoflurane was administered. Has delta activity in awake state.

Awake EEG Clear alpha band activity at 10Hz in spectrum. Three small peaks in delta band (0.9, 1.8, 2.7 Hz)

Awake ECG Unstable baseline, reverse polarity of R peaks.

Awake Respiration Mostly passable waveform, some instability at start (i 250s). Some isolated faults.

Asleep EEG Clearly defined alpha activity at 11Hz.

Asleep ECG Some contamination, reverse polarity R peaks.

Asleep Respiration Clean peaked waveform, single baseline change at 1840s.

Plots

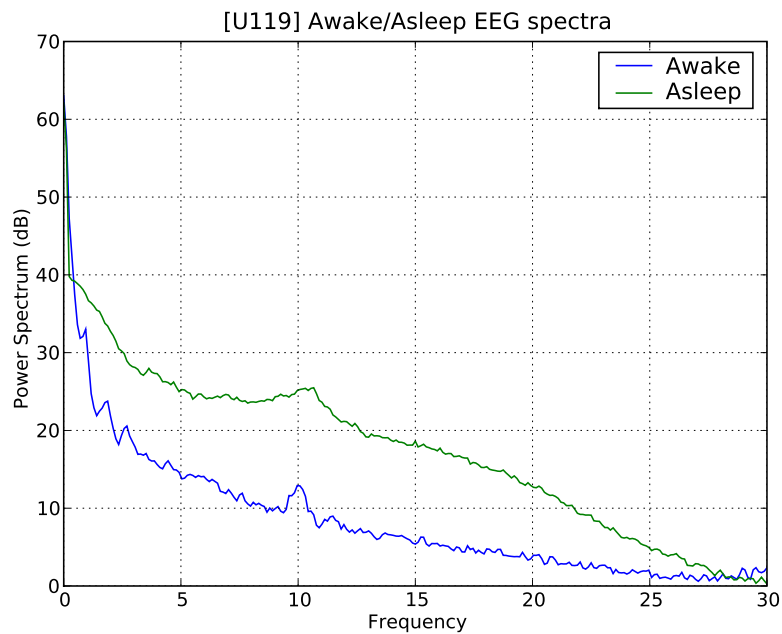


Figure 149: EEG Spectrum of patient U119

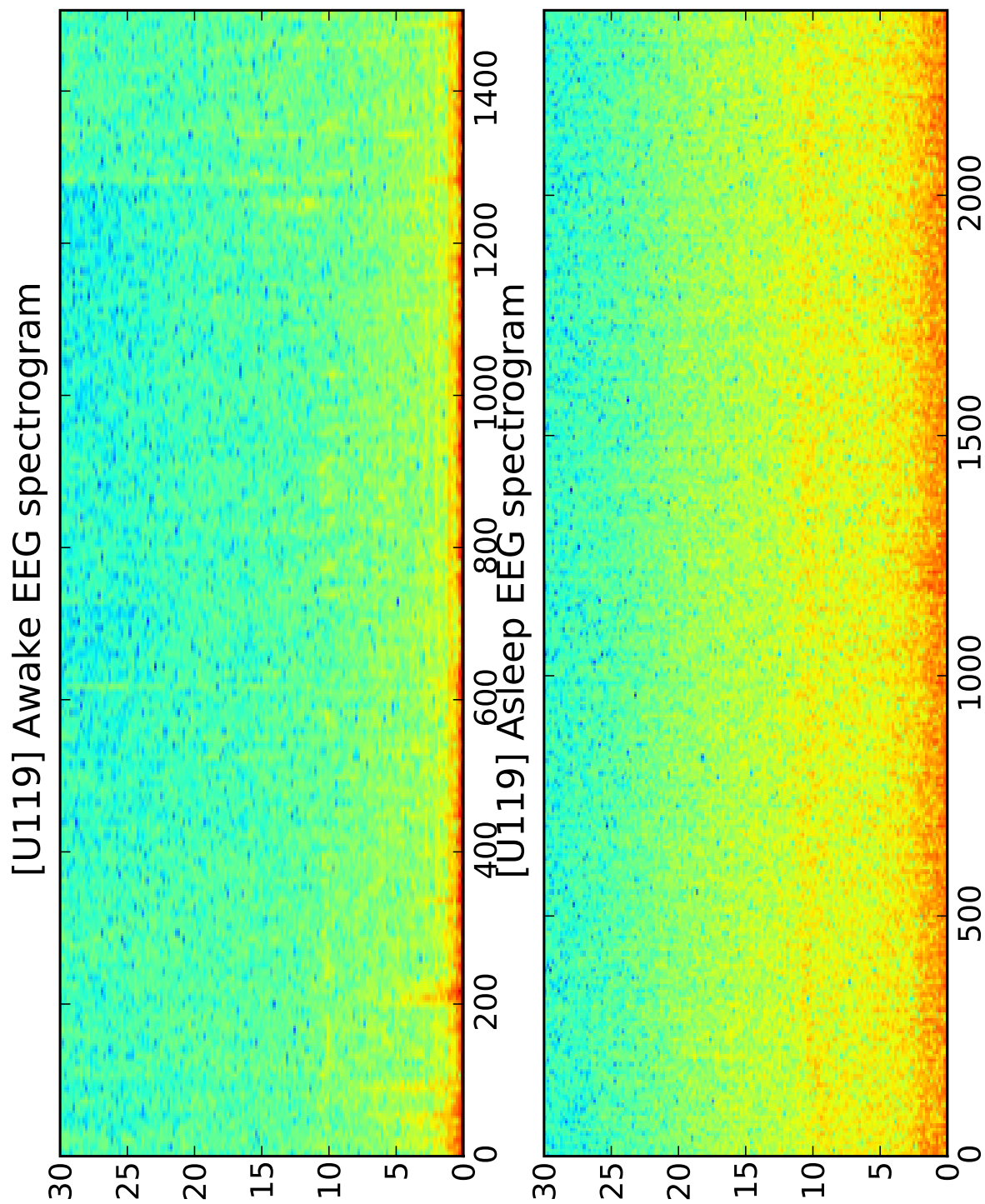


Figure 150: EEG Spectrogram of patient U119

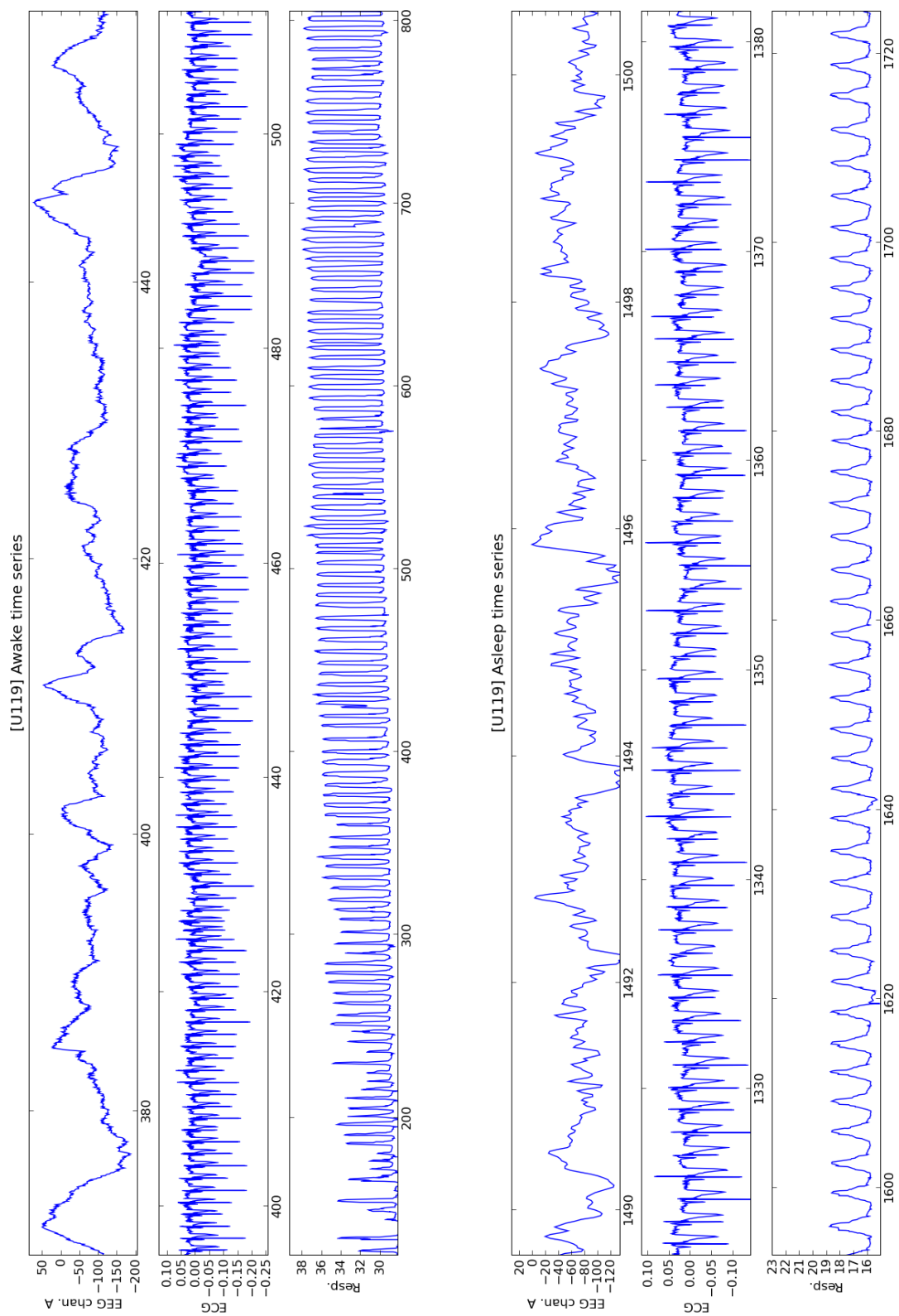


Figure 151: Time series samples of patient U119

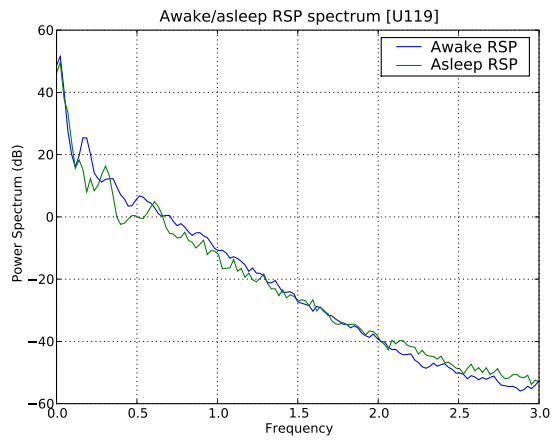
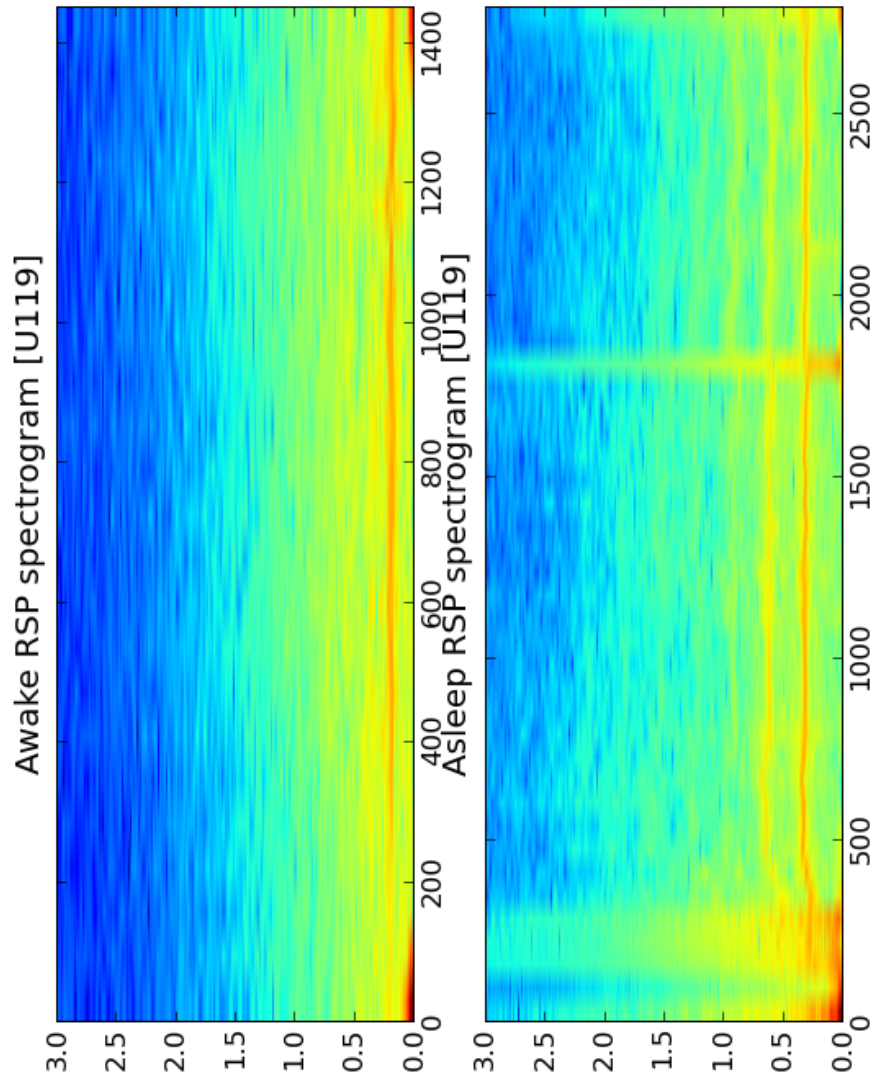


Figure 152: Time series samples of patient U119

3.39 U120

Comments

Sevoflurane was administered. Awake respiration may be unusable. Asleep measurements very clear.

Awake EEG Low power theta band 7Hz activity.

Awake ECG Clean signal, minor baseline instability.

Awake Respiration Four high amplitude spikes. Large amplitude fluctuations, some signal losses (590s, 820s, ...). Bad signal quality. Some lost peaks.

Asleep EEG Nice waveform, good signal. Clear 8Hz activity in alpha/theta band.

Asleep ECG Clean signal, baseline instability.

Asleep Respiration Unsymmetric waveform, clear peaks.

Plots

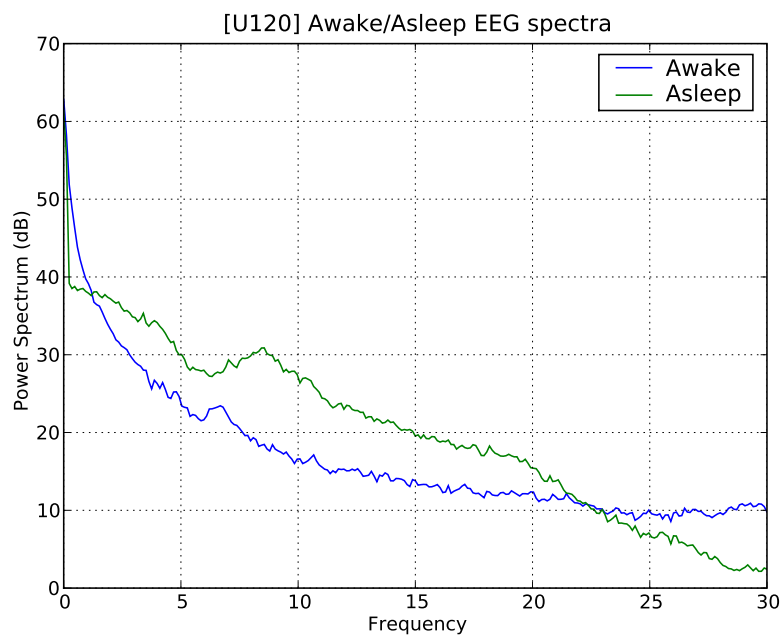


Figure 153: EEG Spectrum of patient U120

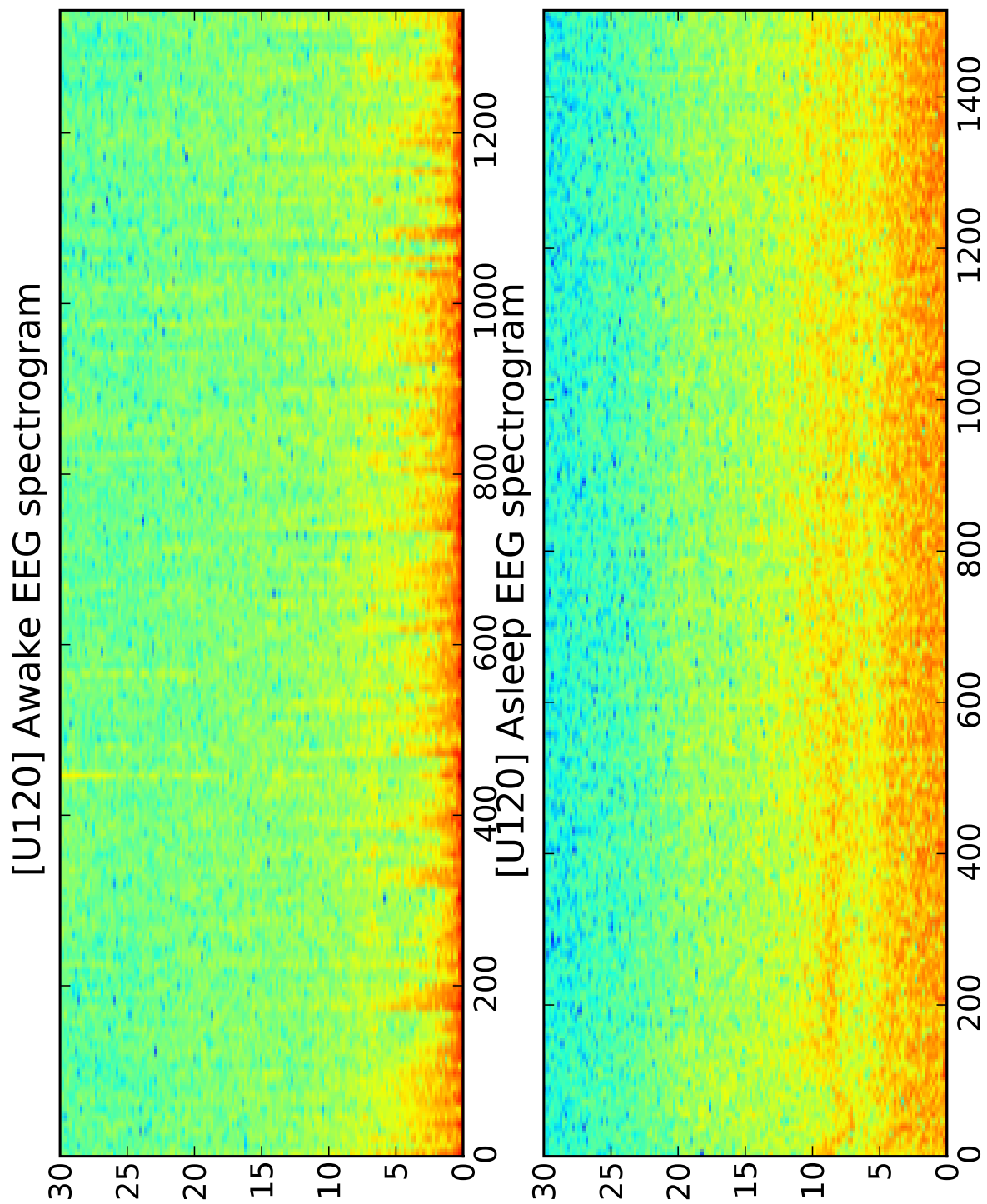


Figure 154: EEG Spectrogram of patient U120

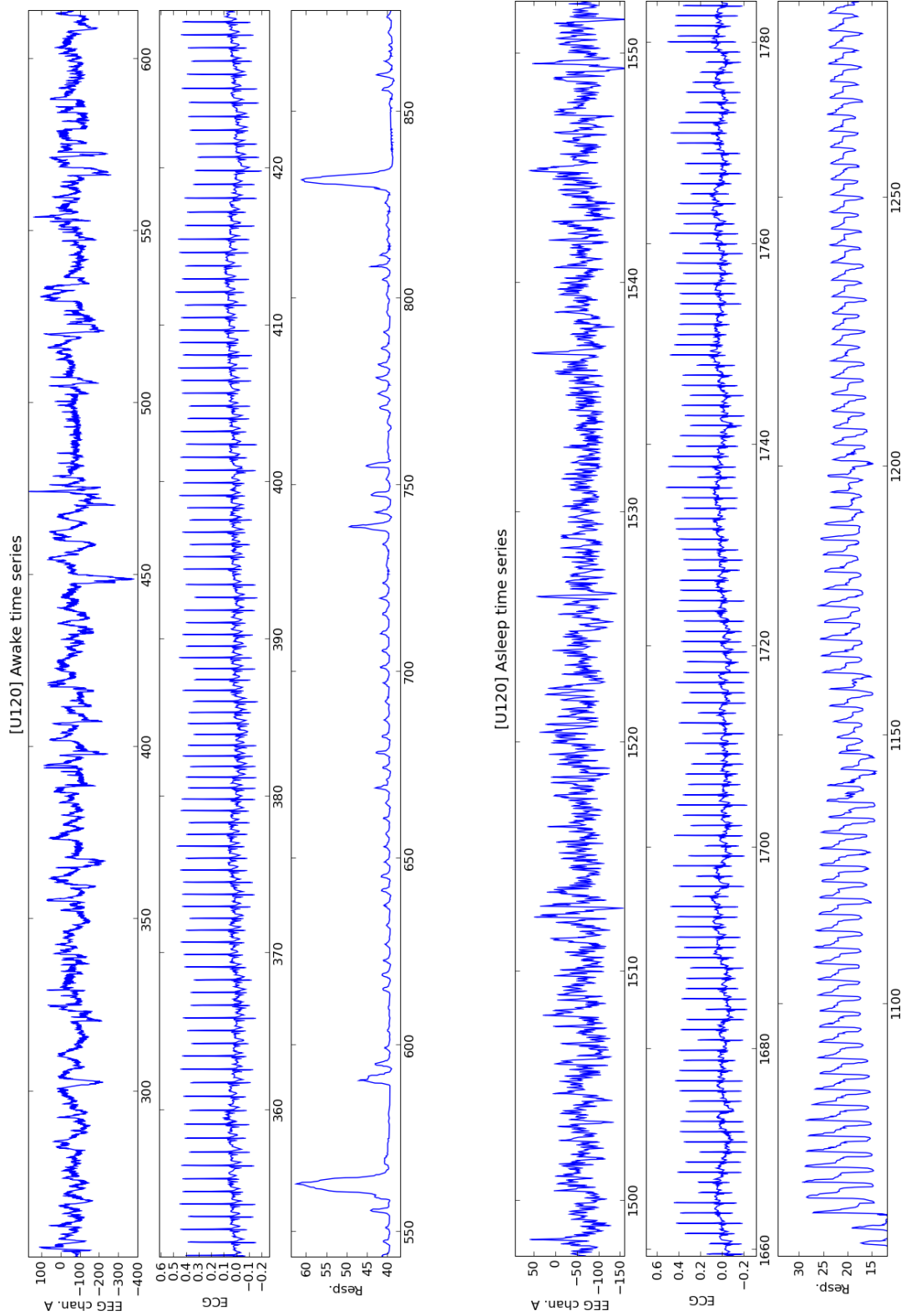


Figure 155: Time series samples of patient U120

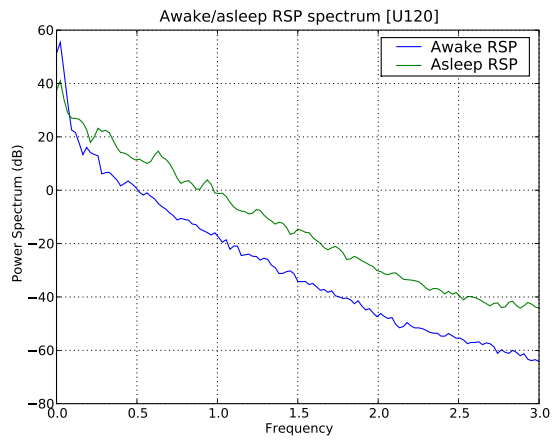
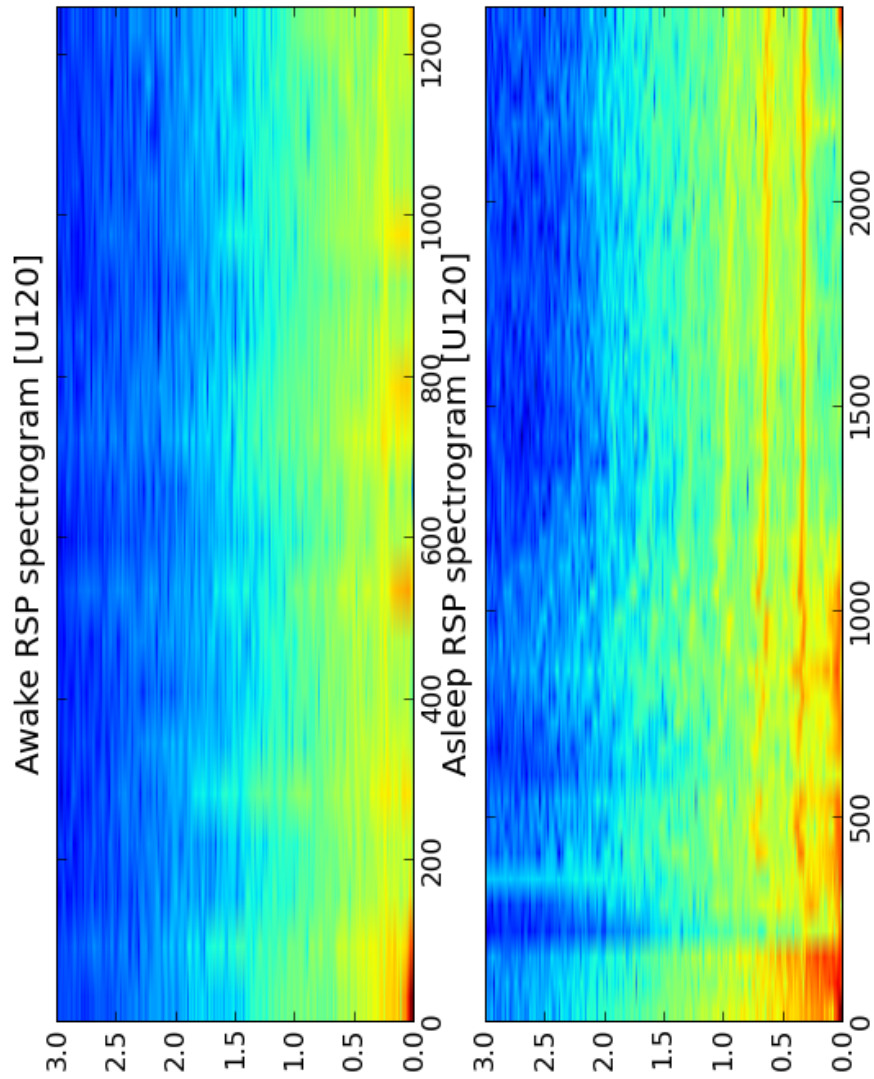


Figure 156: Time series samples of patient U120

3.40 U122

Comments

Propofol was administered. Patient has very good EEG measurements in both states.

Awake EEG Strong activity in awake state: 6Hz theta band, 10Hz alpha band. Delta band activity at (0.9Hz, 1.8Hz, 2.7Hz). Third peak is not clear.

Awake ECG Clear bipolar R peaks.

Awake Respiration Flat peaks, some noise contamination. Asymmetric waveform. Passable.

Asleep EEG Clear 9Hz alpha band activity and 0.3Hz delta band activity. Good waveform.

Asleep ECG Clean waveform, bipolar R peaks.

Asleep Respiration Two spikes. Clear sharp peaked waveform. Some irregular breathing.

Plots

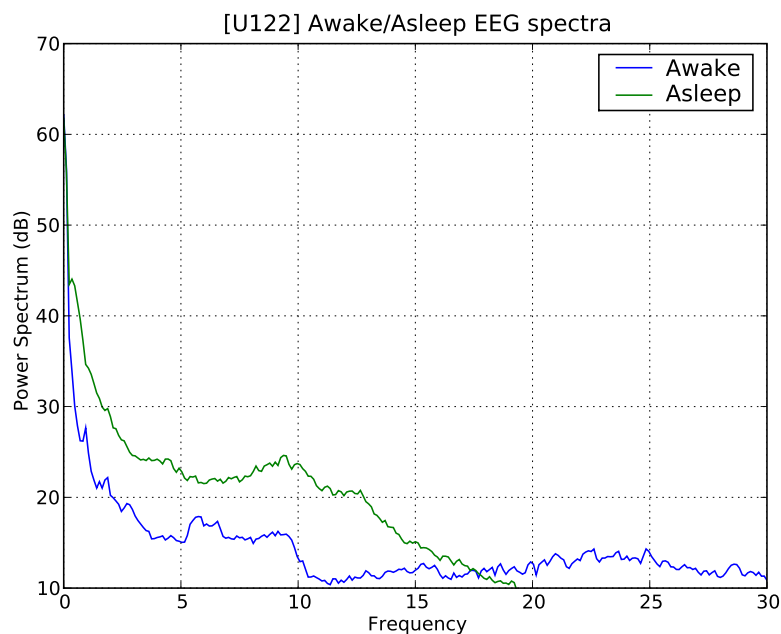


Figure 157: EEG Spectrum of patient U122

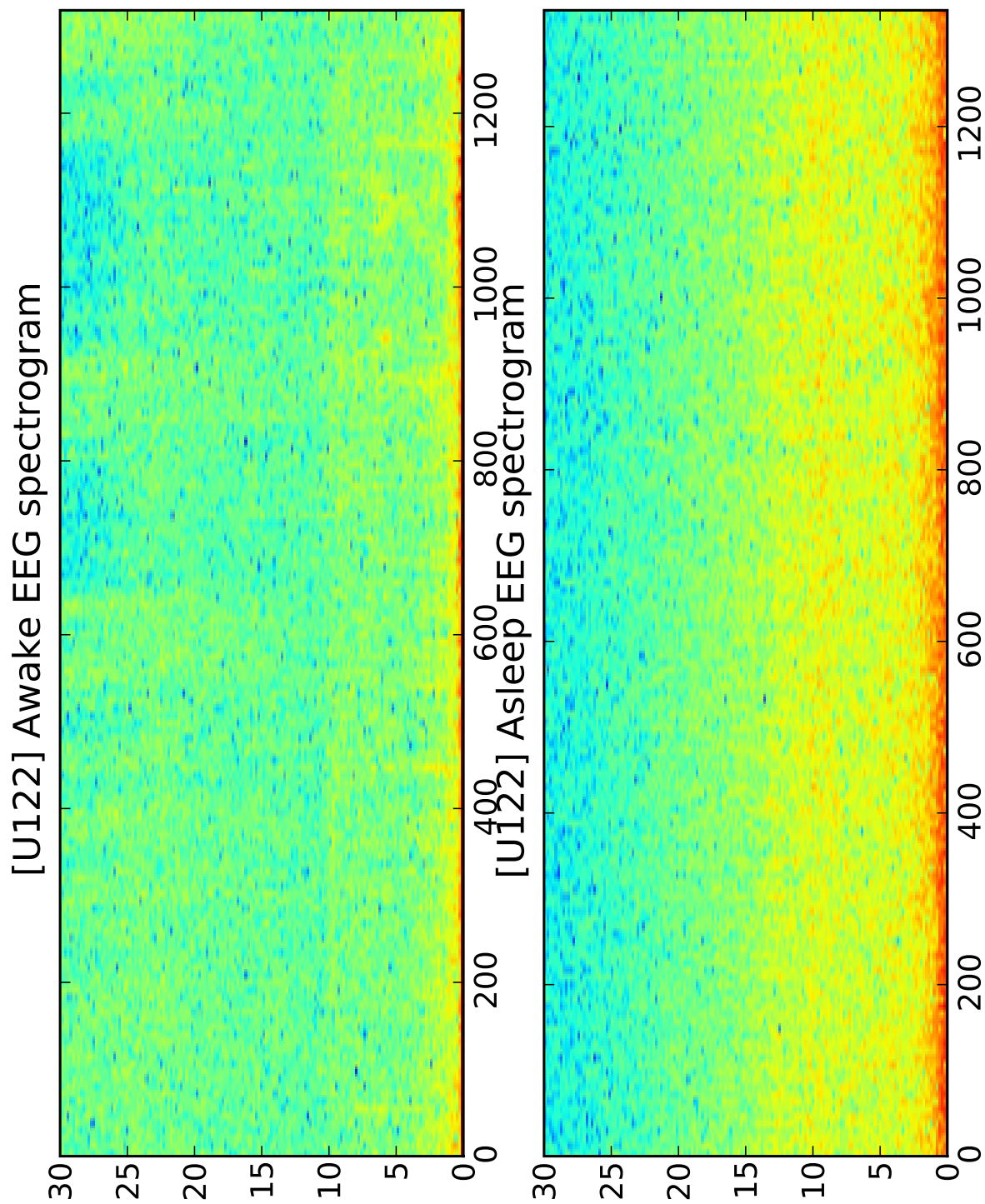


Figure 158: EEG Spectrogram of patient U122

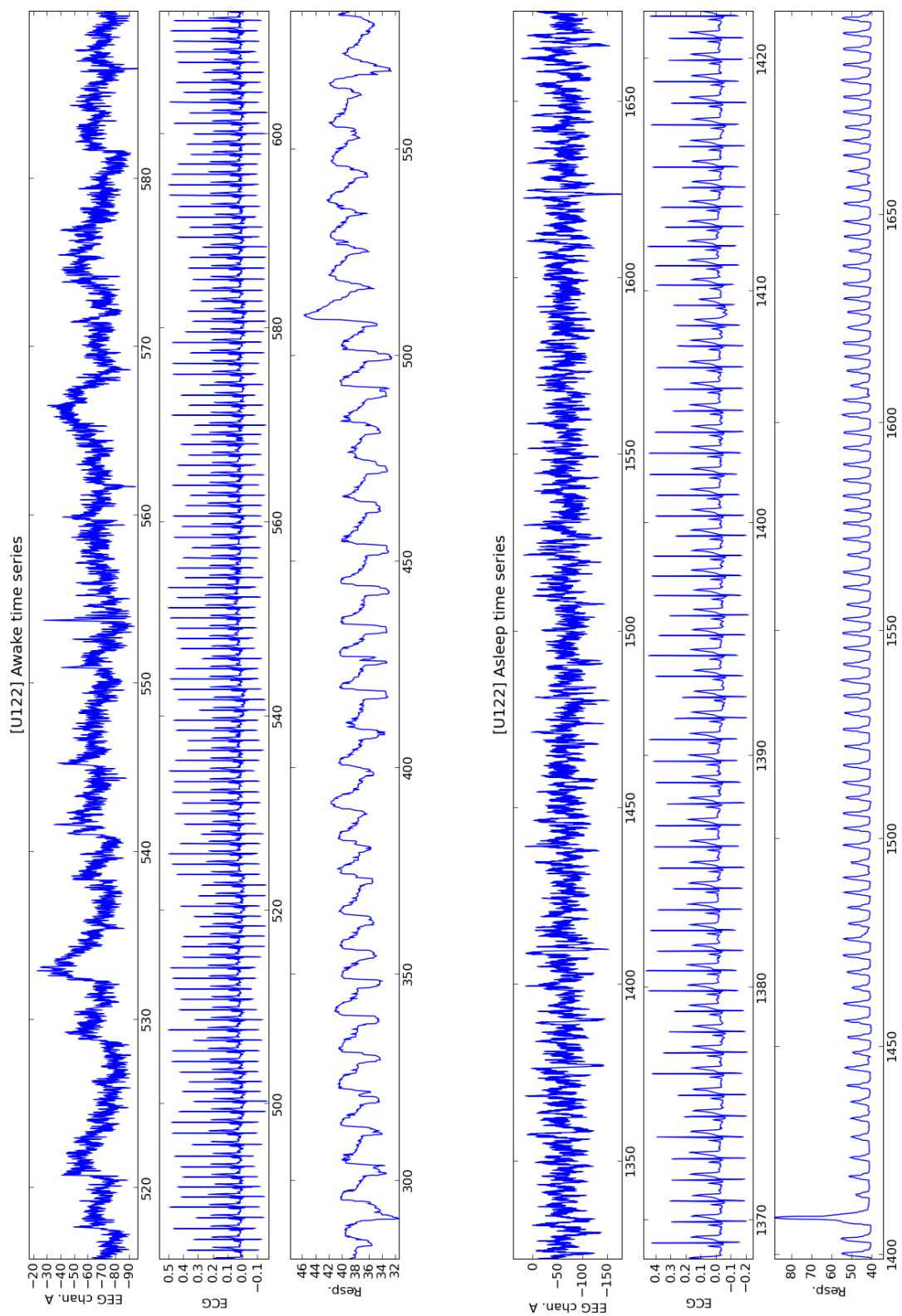


Figure 159: Time series samples of patient U122

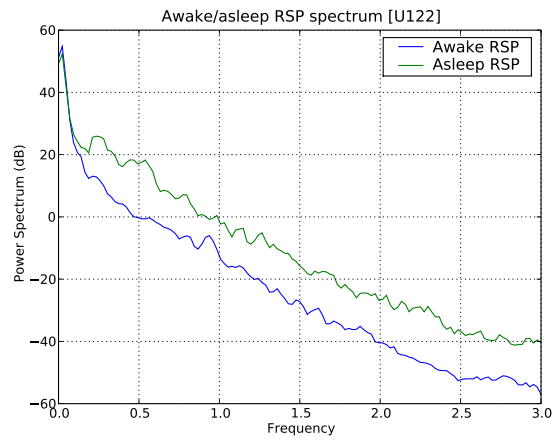
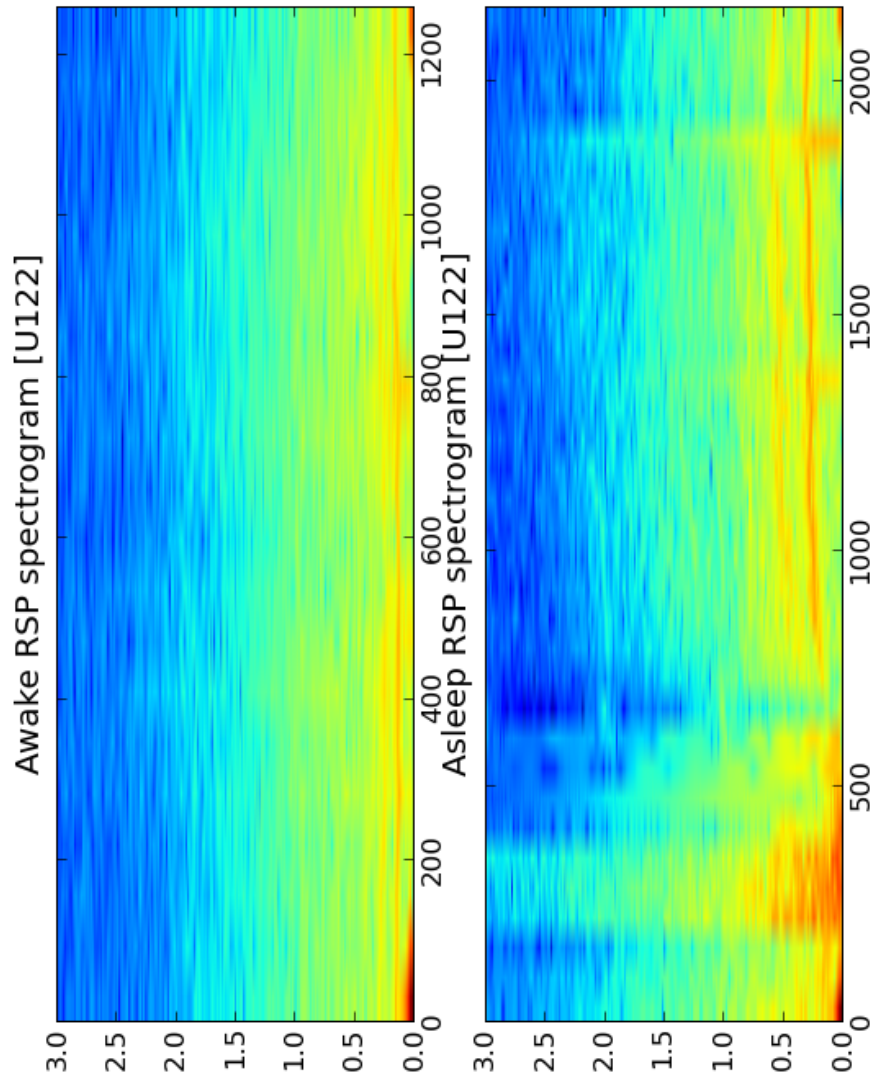


Figure 160: Time series samples of patient U122

3.41 U123

Comments

Sevoflurane with curare was administered. Awake EEG shows beta band and delta band activity.

Awake EEG Suspect delta band low power 2.2Hz activity. Signal has low amplitude clear beta band activity, diffuse around 22Hz.

Awake ECG Clear bipolar R peaks.

Awake Respiration Multiple baseline shifts, asymmetric waveform, slight contamination. Some isolated faults. Passable.

Asleep EEG Clear alpha band 9Hz activity. Some low power delta band 0.3Hz activity.

Asleep ECG Clean signal mostly, some baseline instability.

Asleep Respiration Very clean peaked symmetric waveform.

Plots

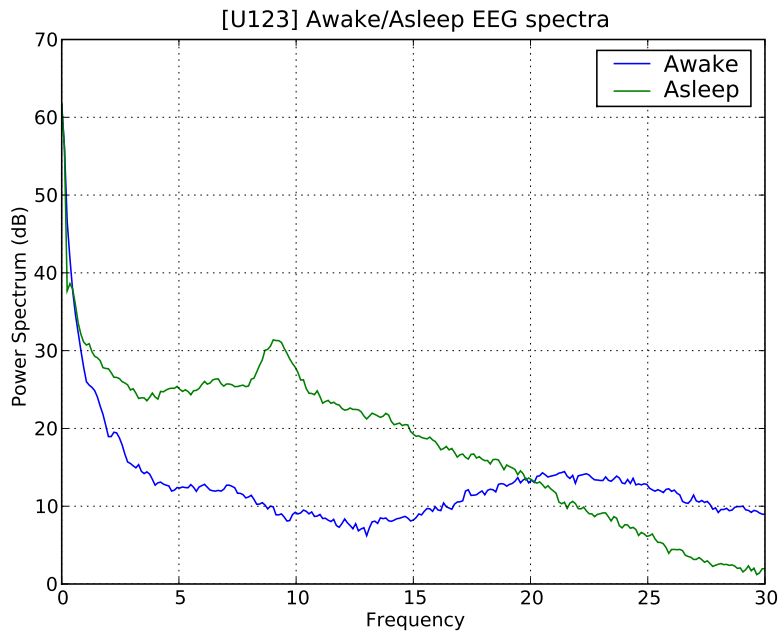


Figure 161: EEG Spectrum of patient U123

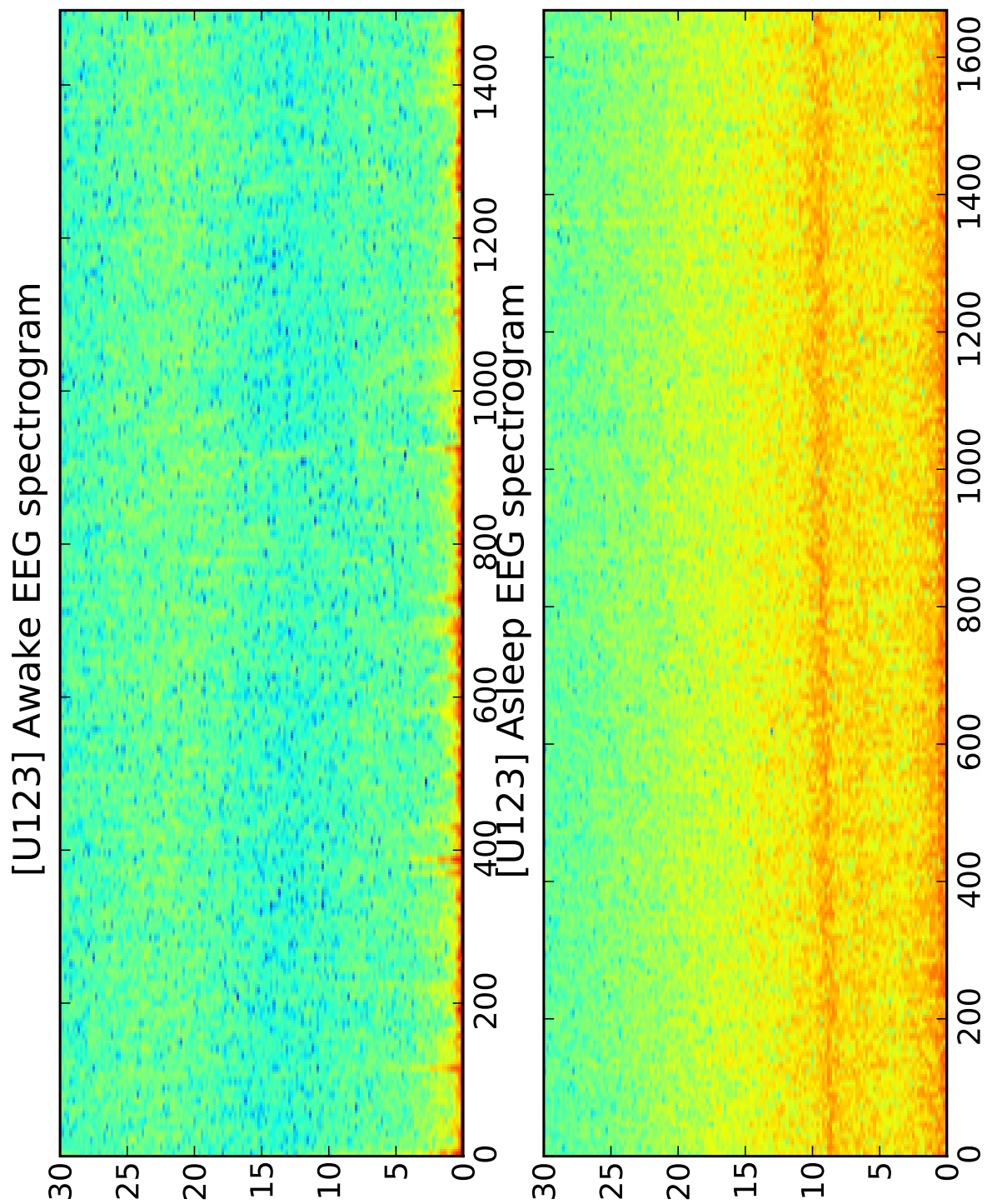


Figure 162: EEG Spectrogram of patient U123

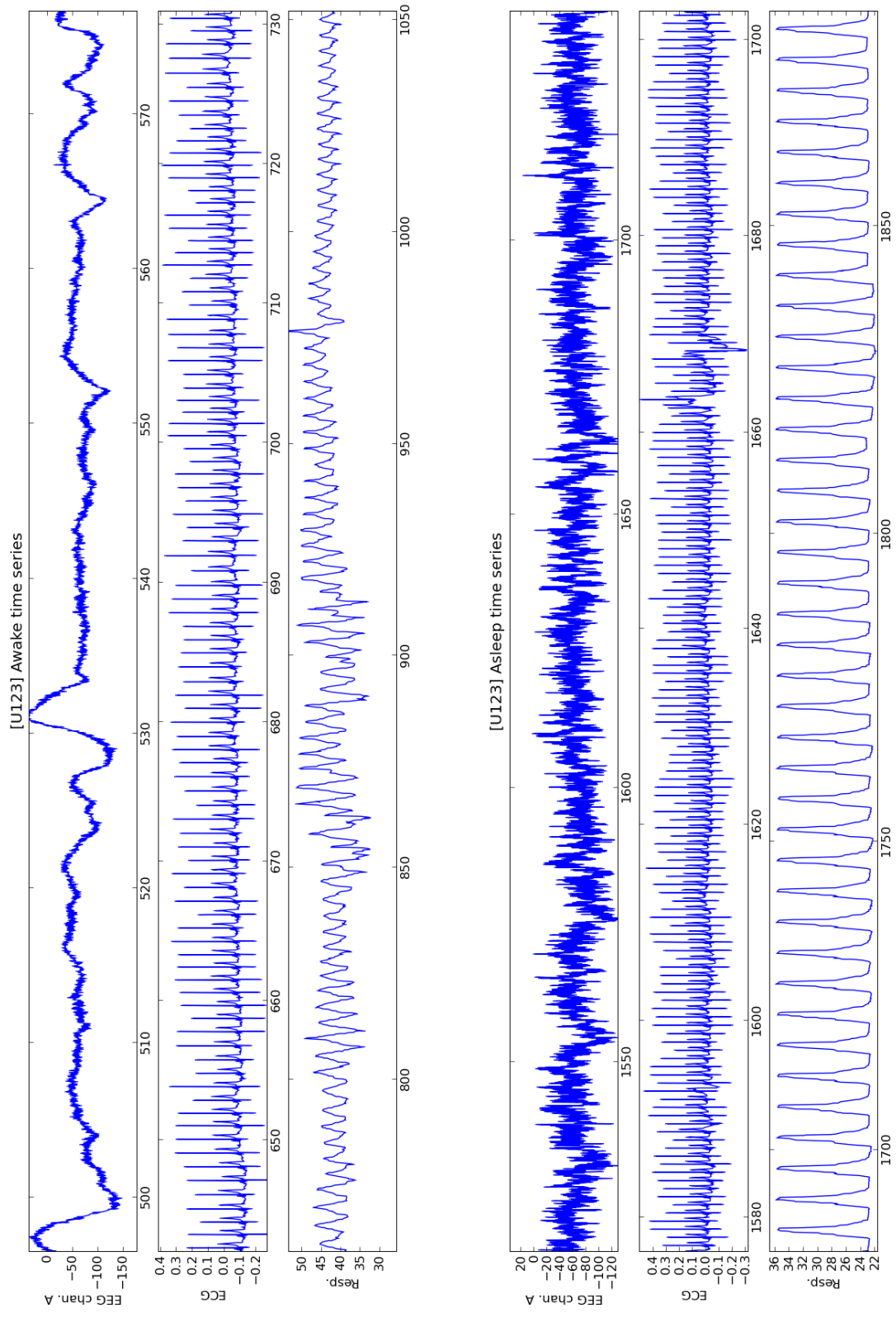


Figure 163: Time series samples of patient U123

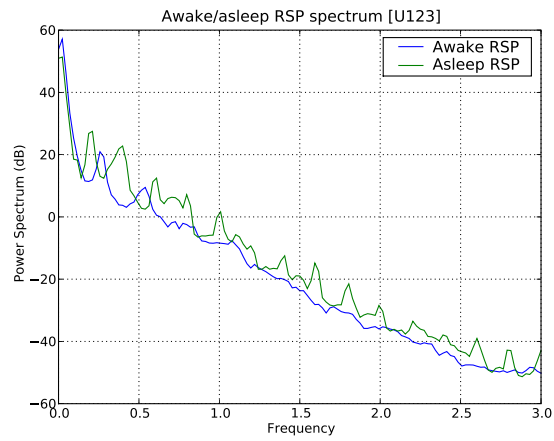
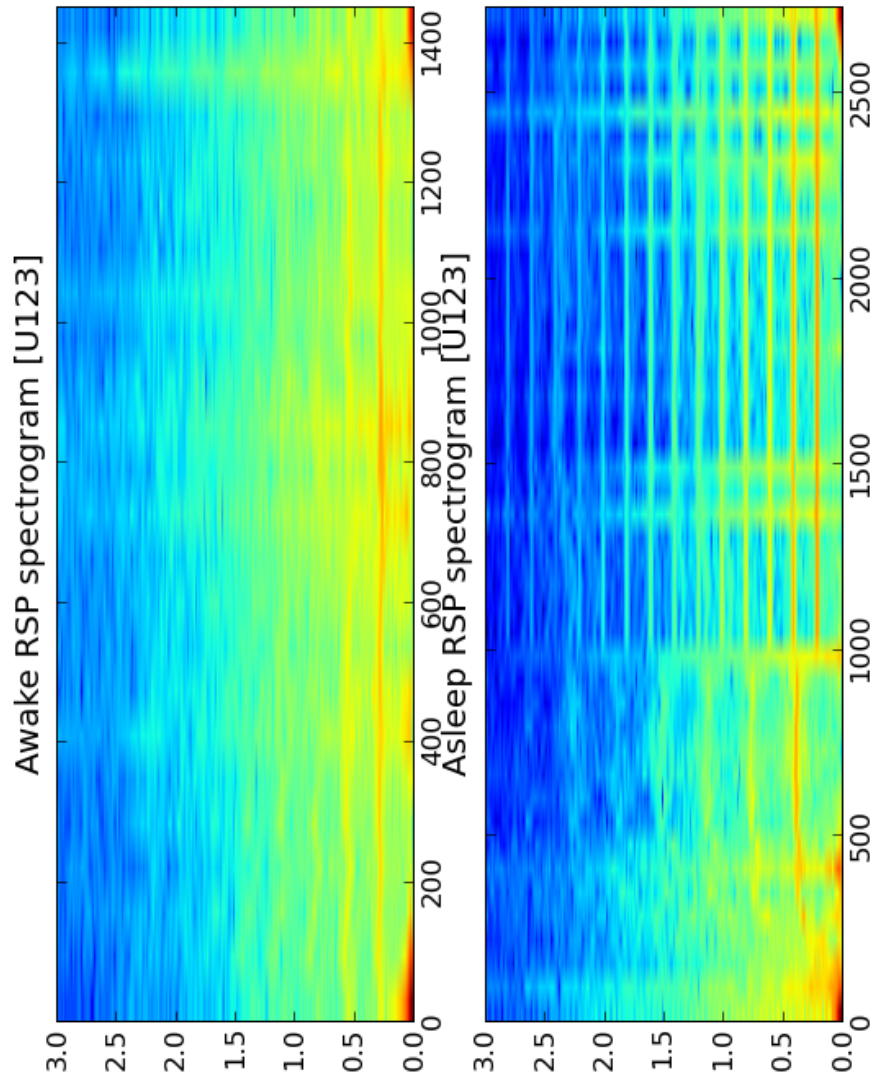


Figure 164: Time series samples of patient U123

3.42 U124

Comments

Propofol was administered. Awake EEG may be devoid of information.

Awake EEG High amplitude contamination (spectrogram). No clear frequency.

Awake ECG Unstable base with clear signal.

Awake Respiration Unusable. Intermittent signal losses.

Asleep EEG Clear 10Hz alpha band activity. Some delta band 0.5Hz activity.

Asleep ECG Unstable baseline, good signal with high amplitude S wave.

Asleep Respiration Two spikes (1300s, 1650s) with baseline shifts, sharp peaked waveform, valley contamination. Passable.

Plots

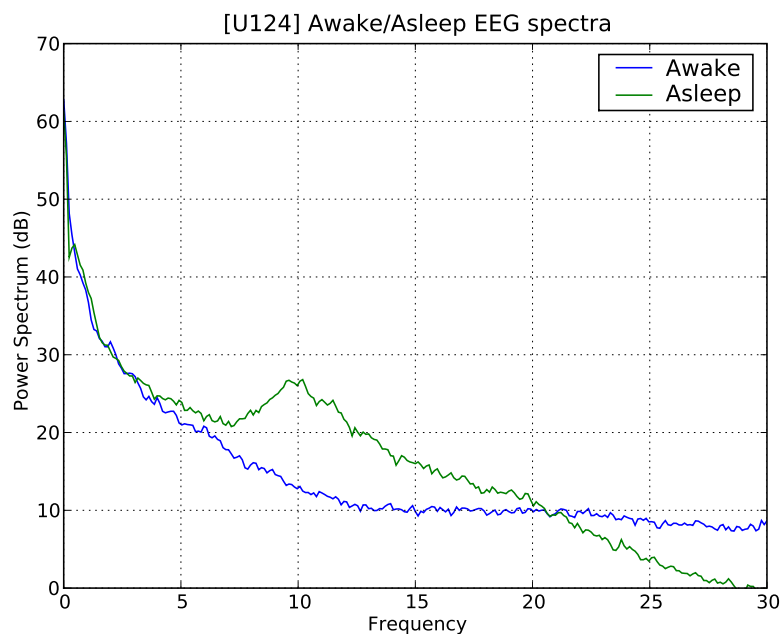


Figure 165: EEG Spectrum of patient U124

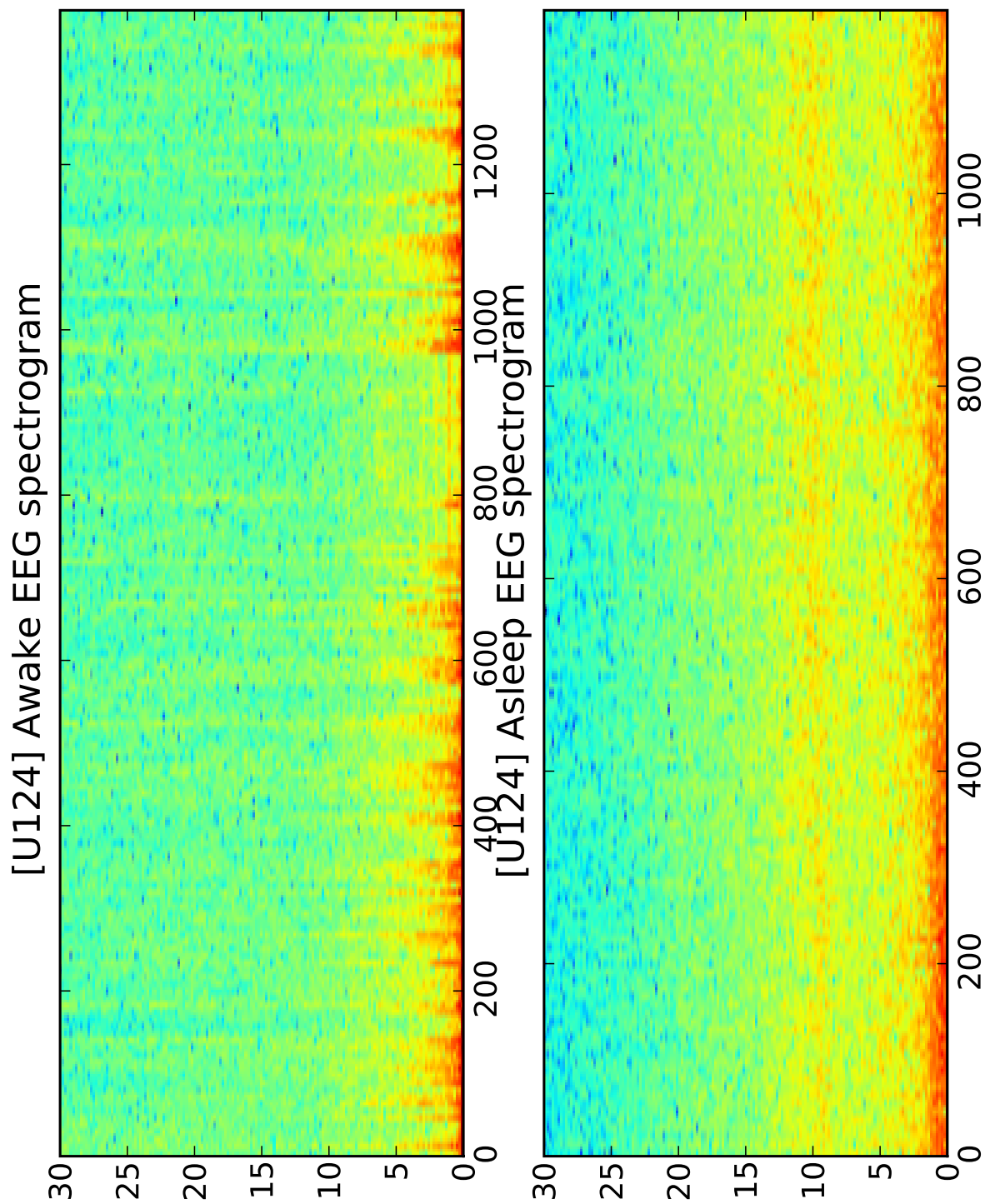


Figure 166: EEG Spectrogram of patient U124

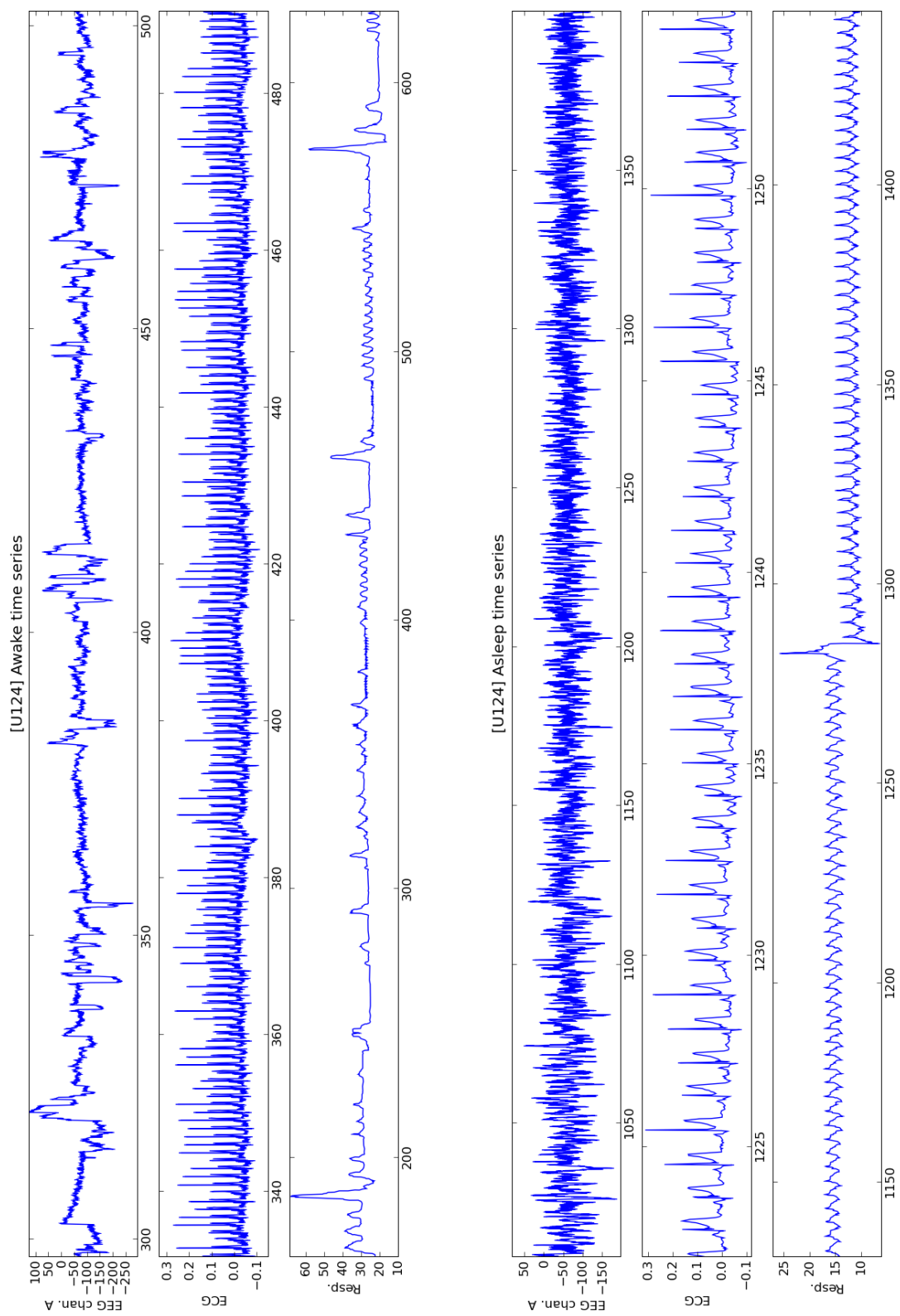


Figure 167: Time series samples of patient U124

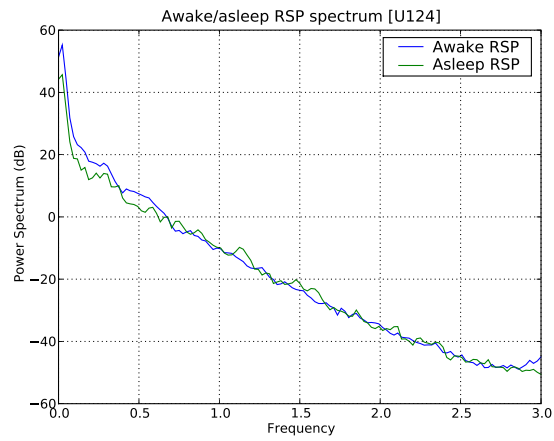
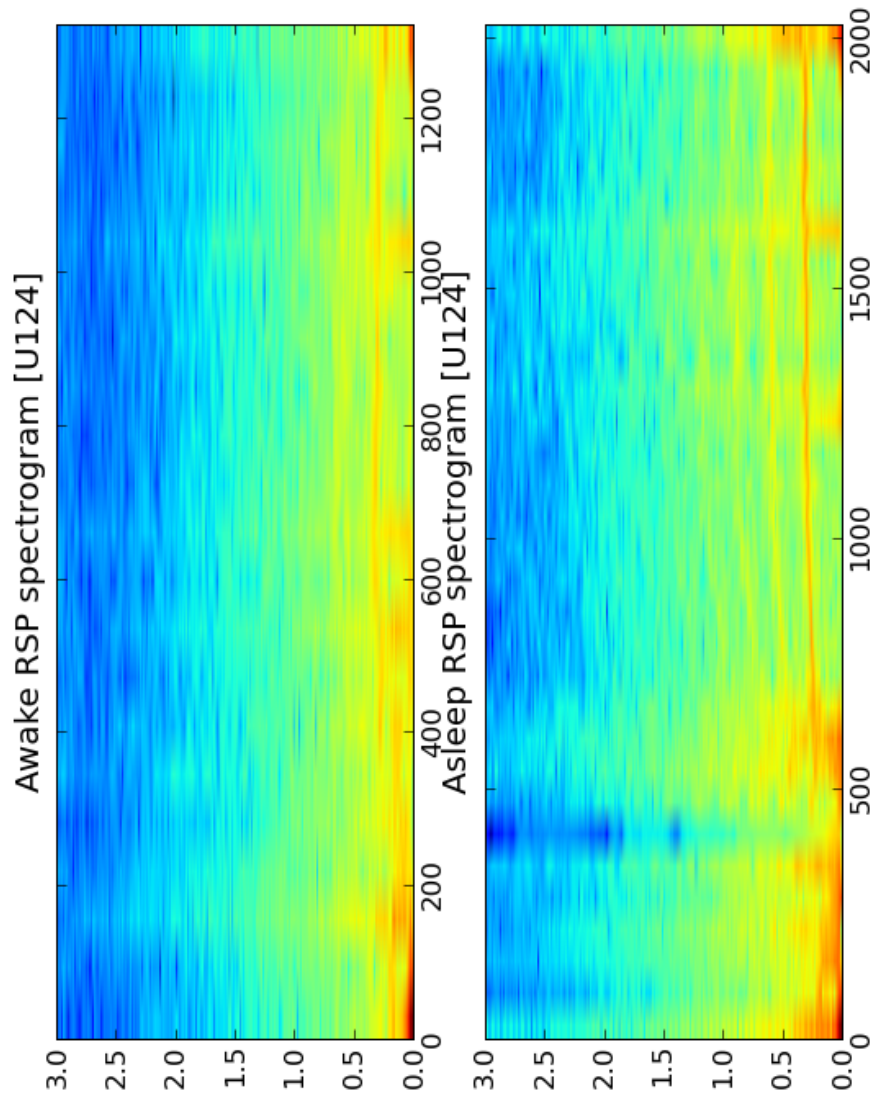


Figure 168: Time series samples of patient U124

3.43 U125

Comments

Sevoflurane with curare was administered. Huge spike in awake measurements at 1000s in all time series. Three spikes in asleep measurements. Same time in all cases. Awake EEG may not be usable.

Awake EEG EEG has nonstandard waveform. Spectrum shows low power theta band 5Hz activity, not visible in spectrogram.

Awake ECG Fluctuating baseline, clean signal.

Awake Respiration Clean signal, nice waveform.

Asleep EEG Clear alpha band activity at 9Hz, delta band activity at 0.5-0.6Hz. Good waveform.

Asleep ECG Clean signal with bipolar R peaks, fluctuating baseline.

Asleep Respiration Very clear symmetric peaks.

Plots

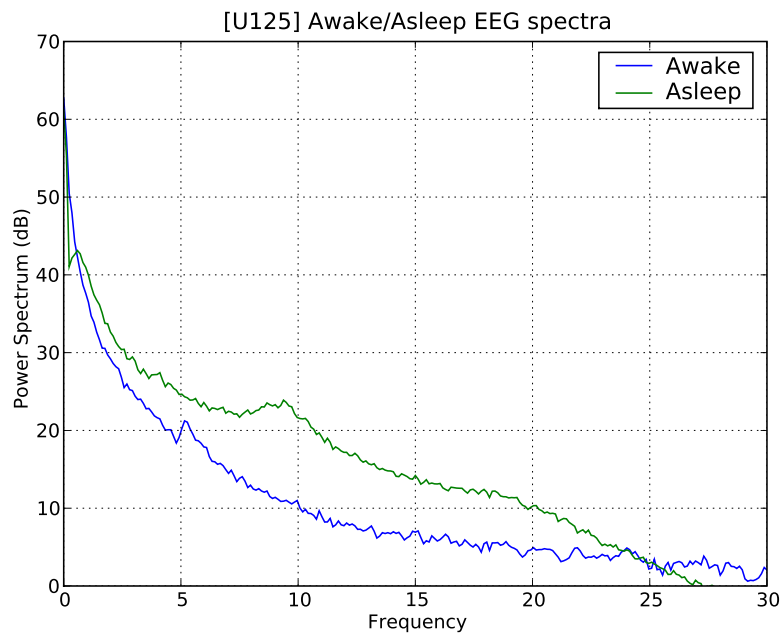


Figure 169: EEG Spectrum of patient U125

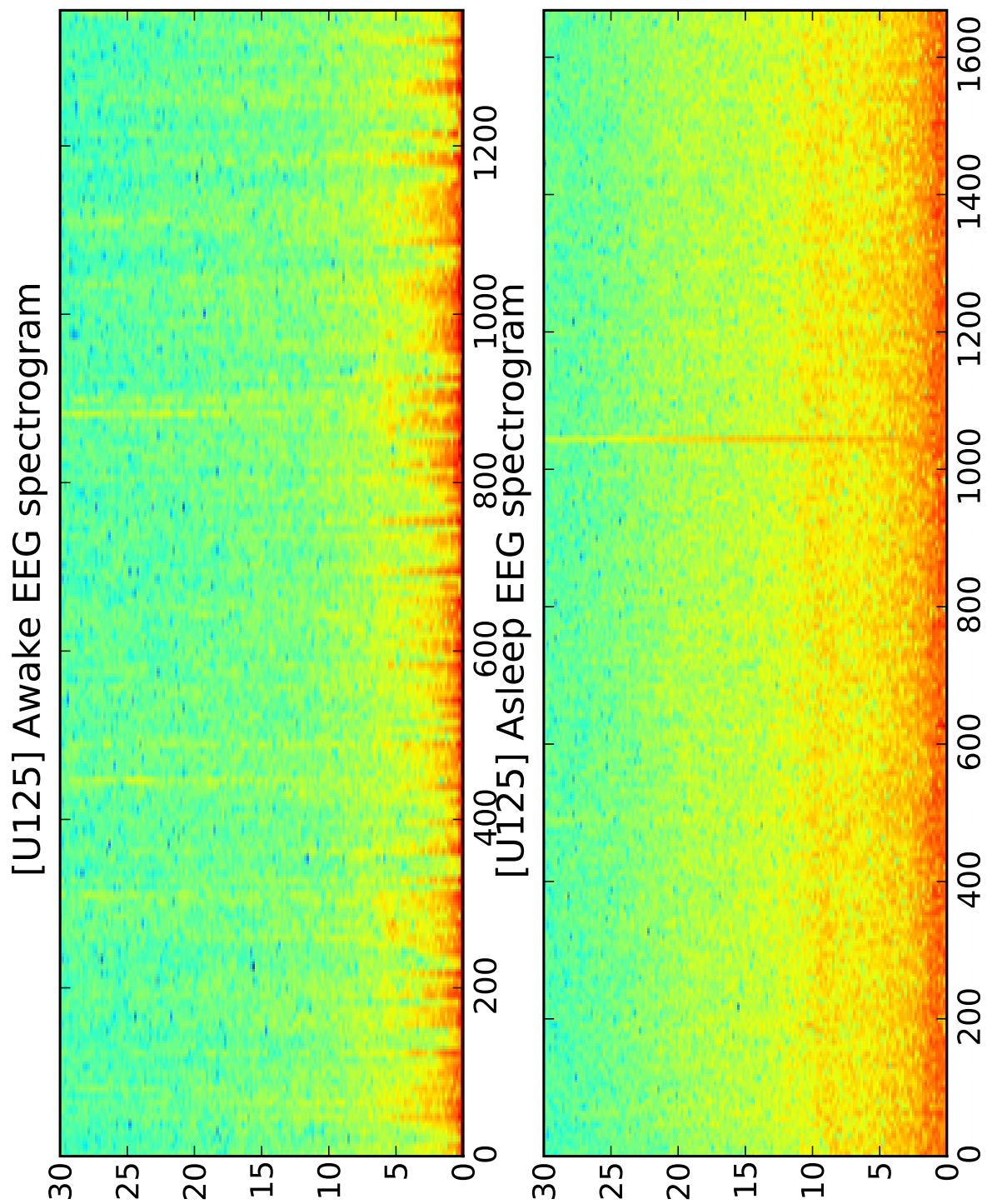


Figure 170: EEG Spectrogram of patient U125

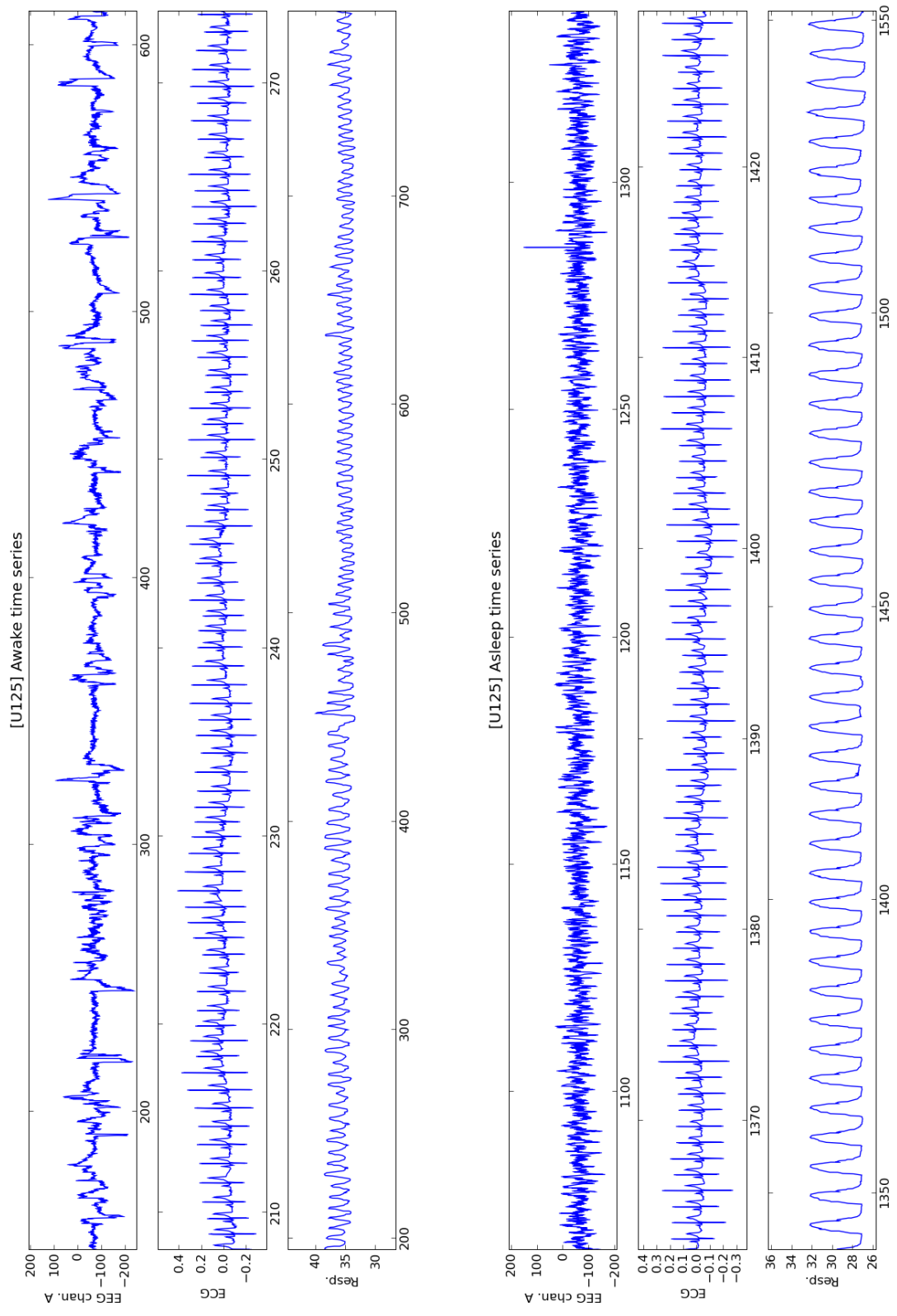


Figure 171: Time series samples of patient U125

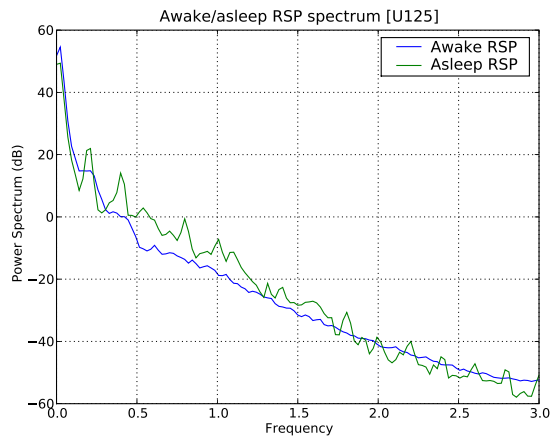
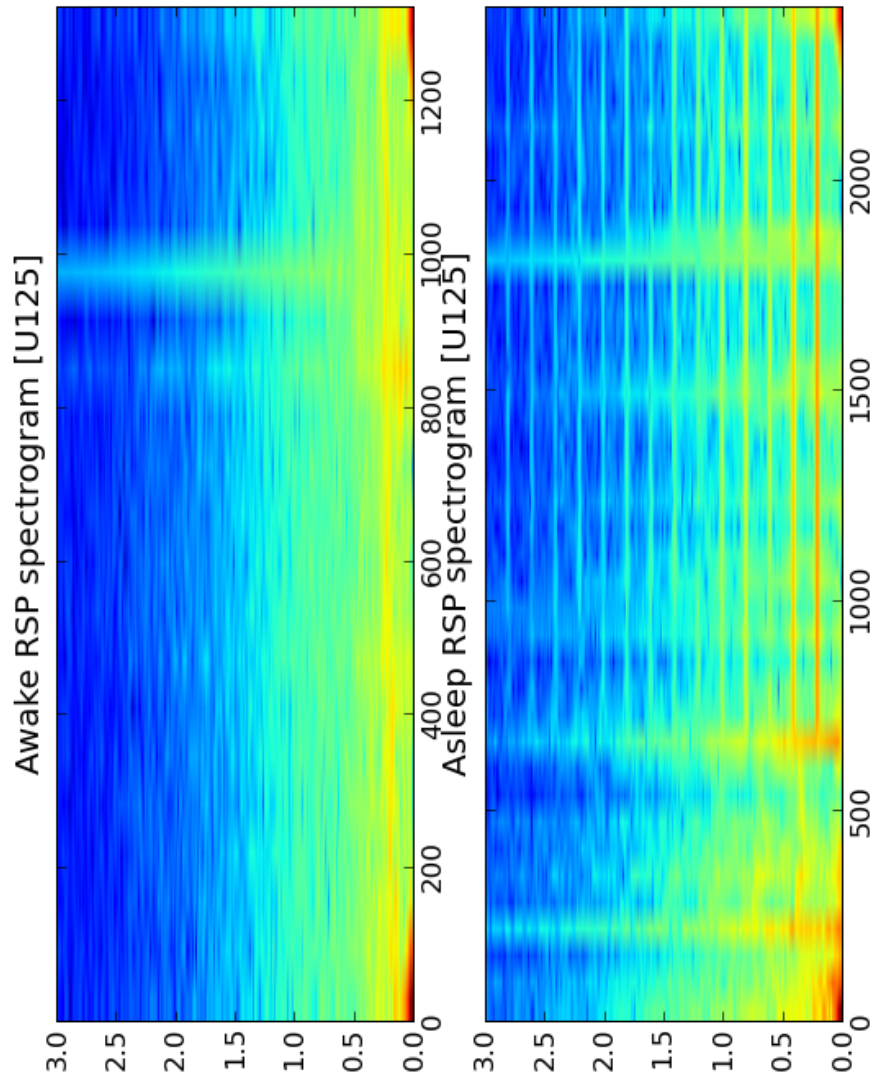


Figure 172: Time series samples of patient U125

3.44 U126

Comments

Propofol with curare was administered.

Awake EEG No clear activity. Some high amplitude contamination with low frequency waves.

Awake ECG Baseline fluctuations with clean signal.

Awake Respiration Bad waveform, contaminated peaks. Peaks may be shifted.

Asleep EEG Clear 10-11Hz alpha band activity. Peak in the delta band at 0.5Hz.

Asleep ECG Very clear signal, high amp. sharp peak S wave, small baseline fluctuations.

Asleep Respiration Clear sharp peaked symmetric waveform.

Plots

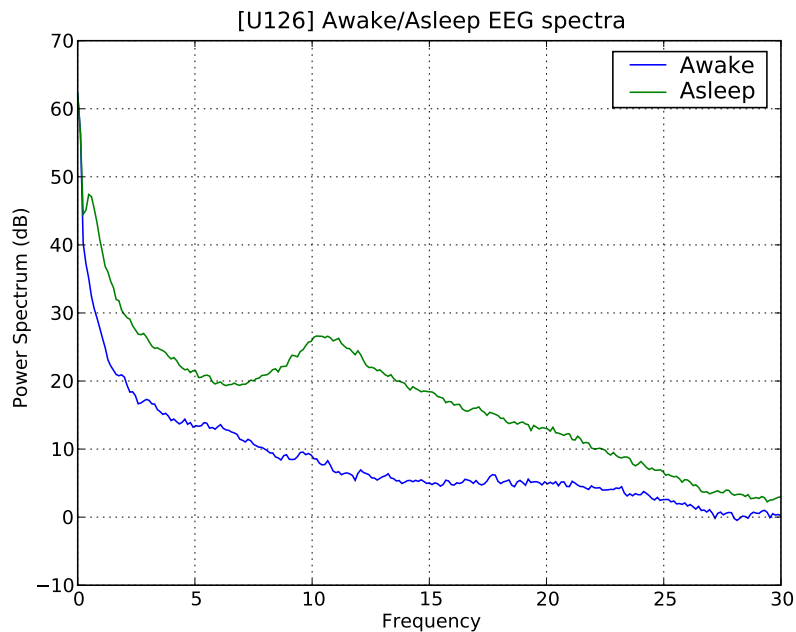


Figure 173: EEG Spectrum of patient U126

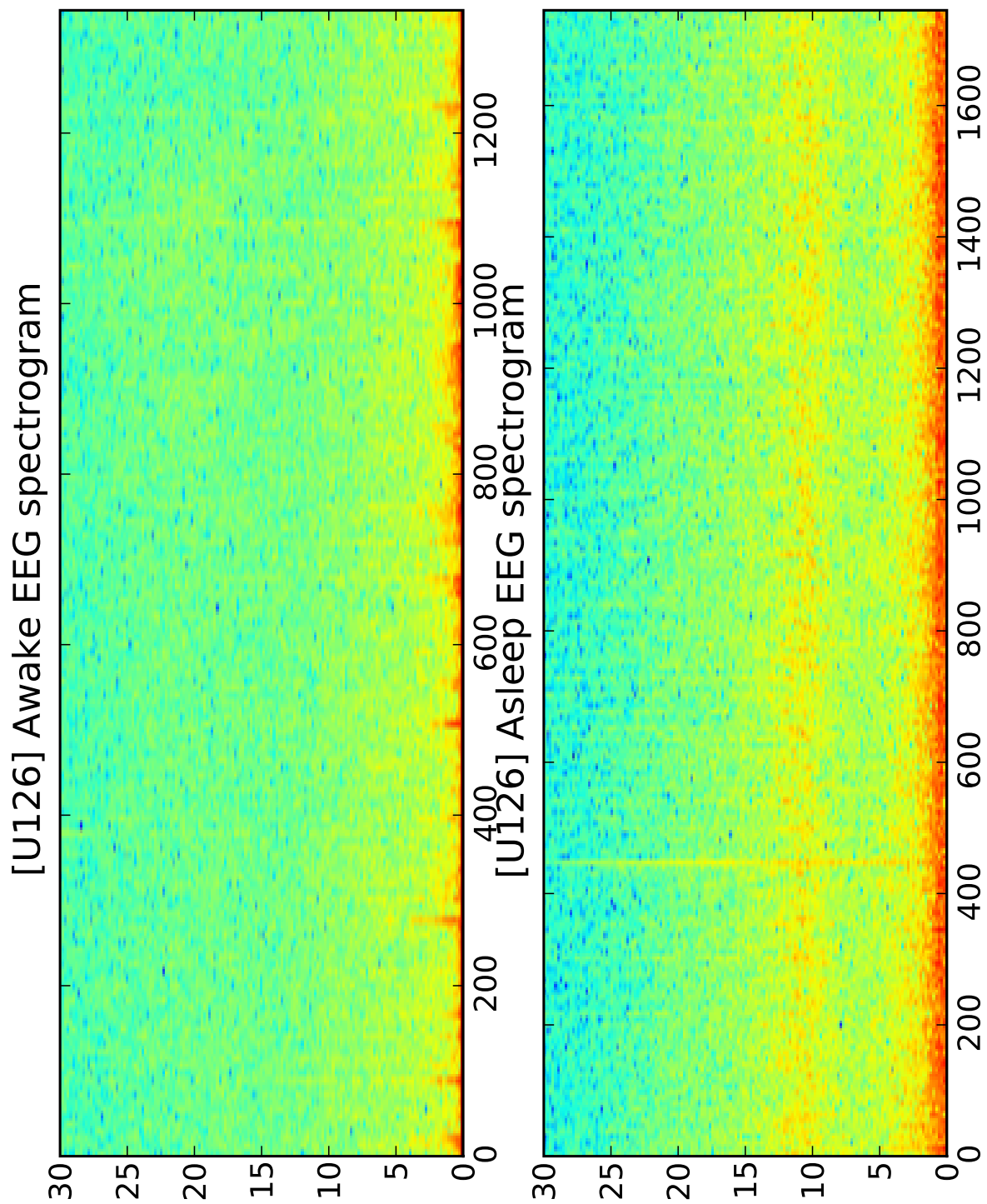


Figure 174: EEG Spectrogram of patient U126

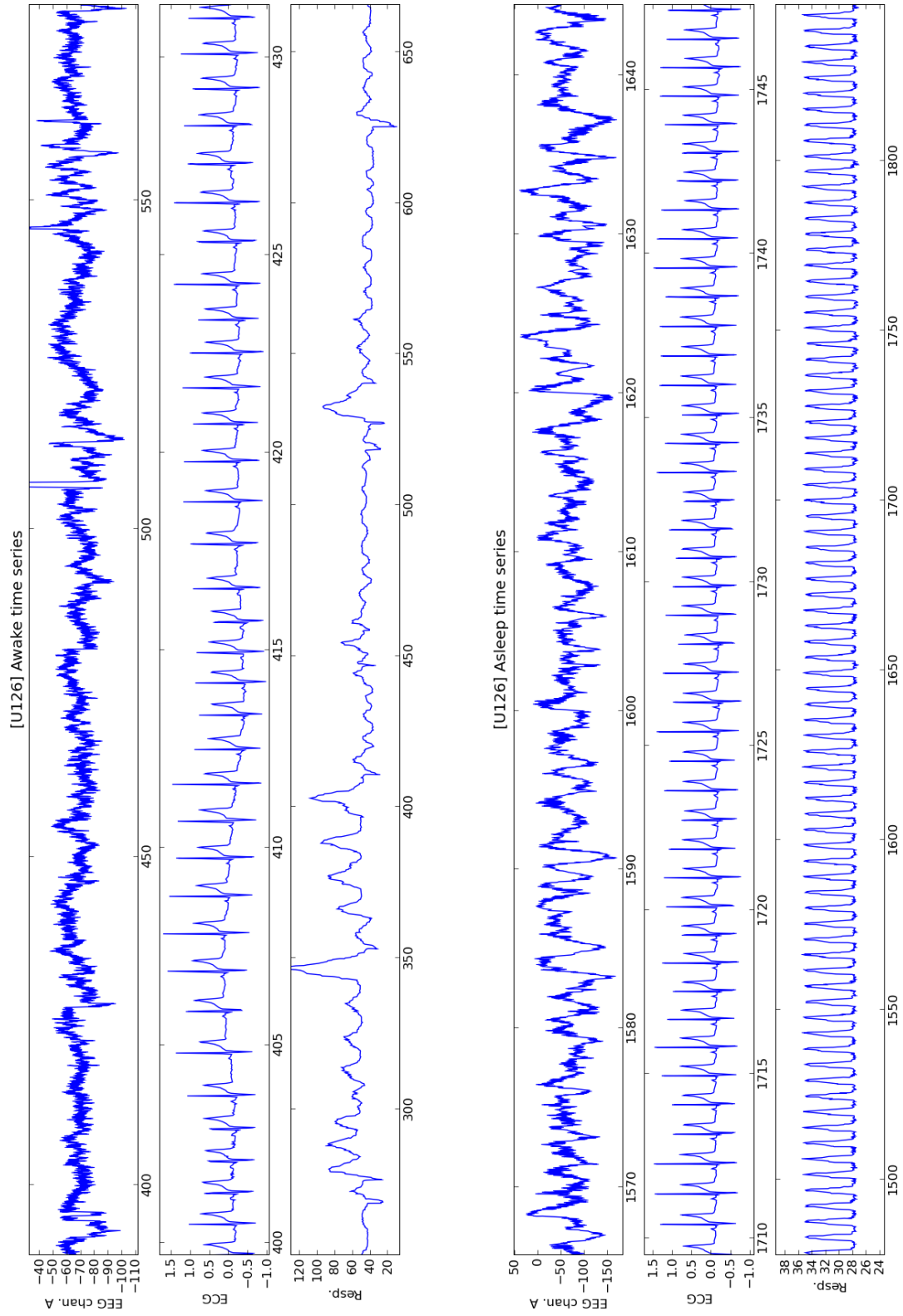


Figure 175: Time series samples of patient U126

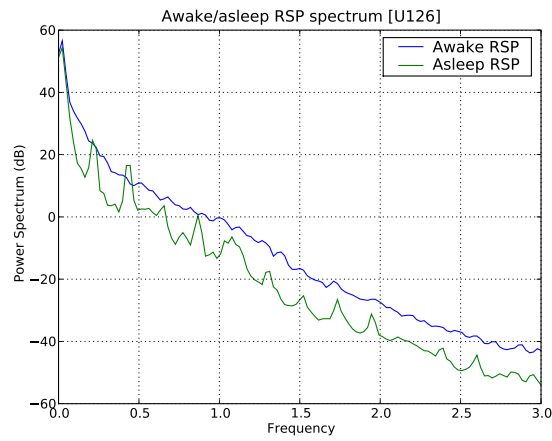
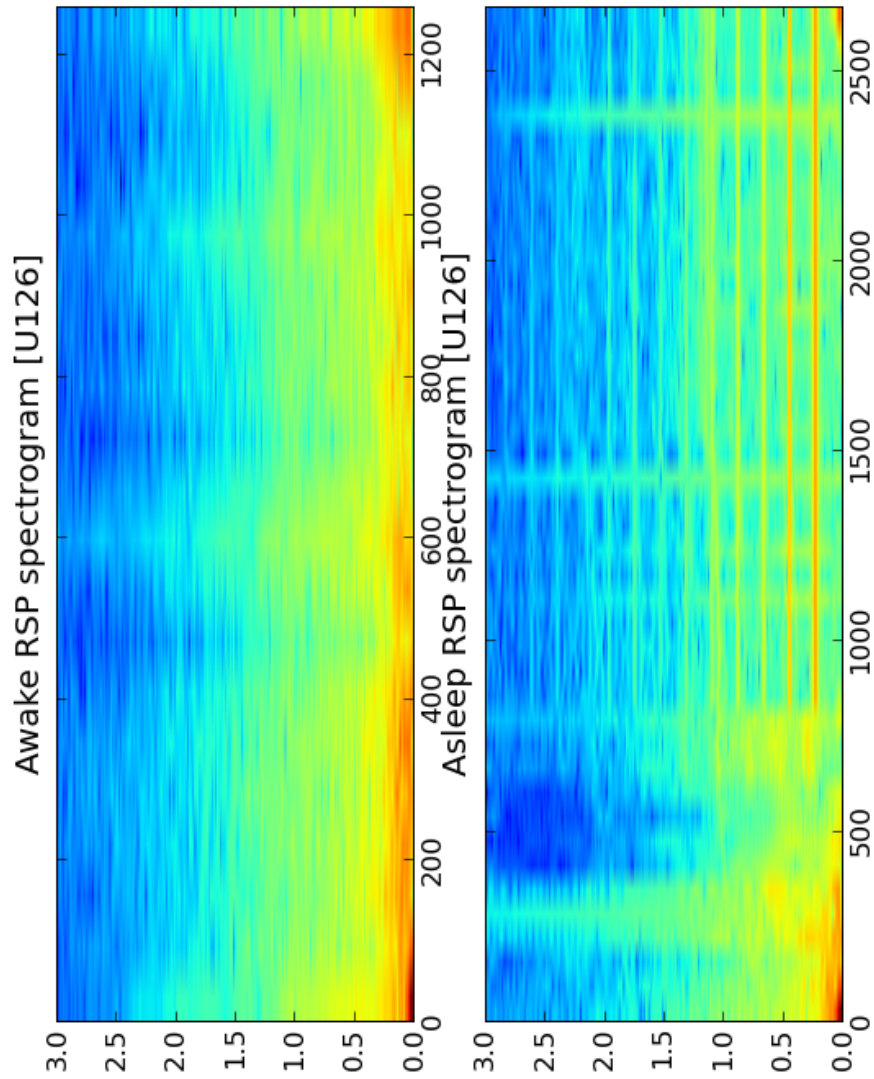


Figure 176: Time series samples of patient U126

3.45 U127

Comments

Sevoflurane was administered, curare usage unknown. Respiration in asleep state has flat tops, unclear time of peak. Awake EEG may be unusable.

Awake EEG Some high amplitude spikes (spectrogram). Very low amplitude higher frequency activity. Spectrum shows very low theta/alpha composite activity, on threshold.

Awake ECG Very clear waveform.

Awake Respiration Passable waveform mostly, contains increasing baseline trend. Stable amplitude mostly.

Asleep EEG Clear alpha band activity at 9-10Hz and low power delta band activity 0.8Hz.

Asleep ECG Clear signal, some amplitude variations.

Asleep Respiration Very stable, symmetric waveform. Peak contamination with noise, may shift peaks when extracting.

Plots

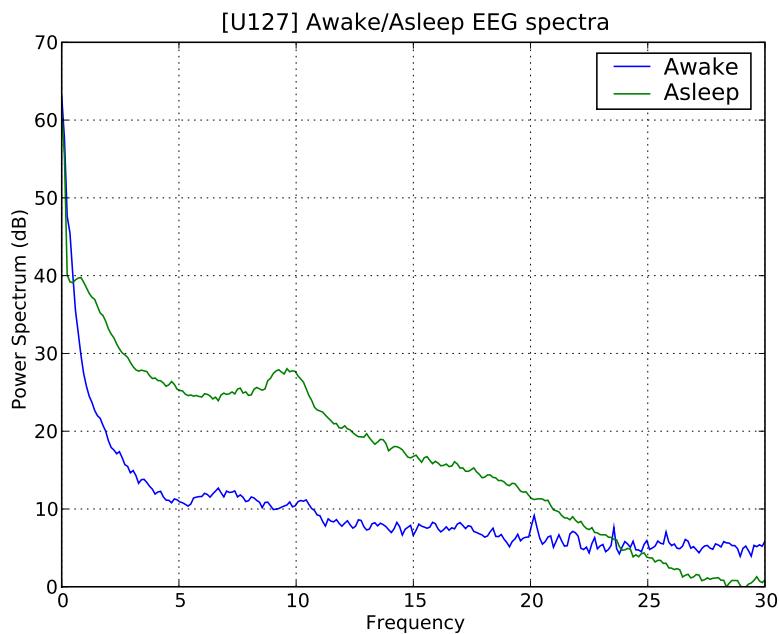


Figure 177: EEG Spectrum of patient U127

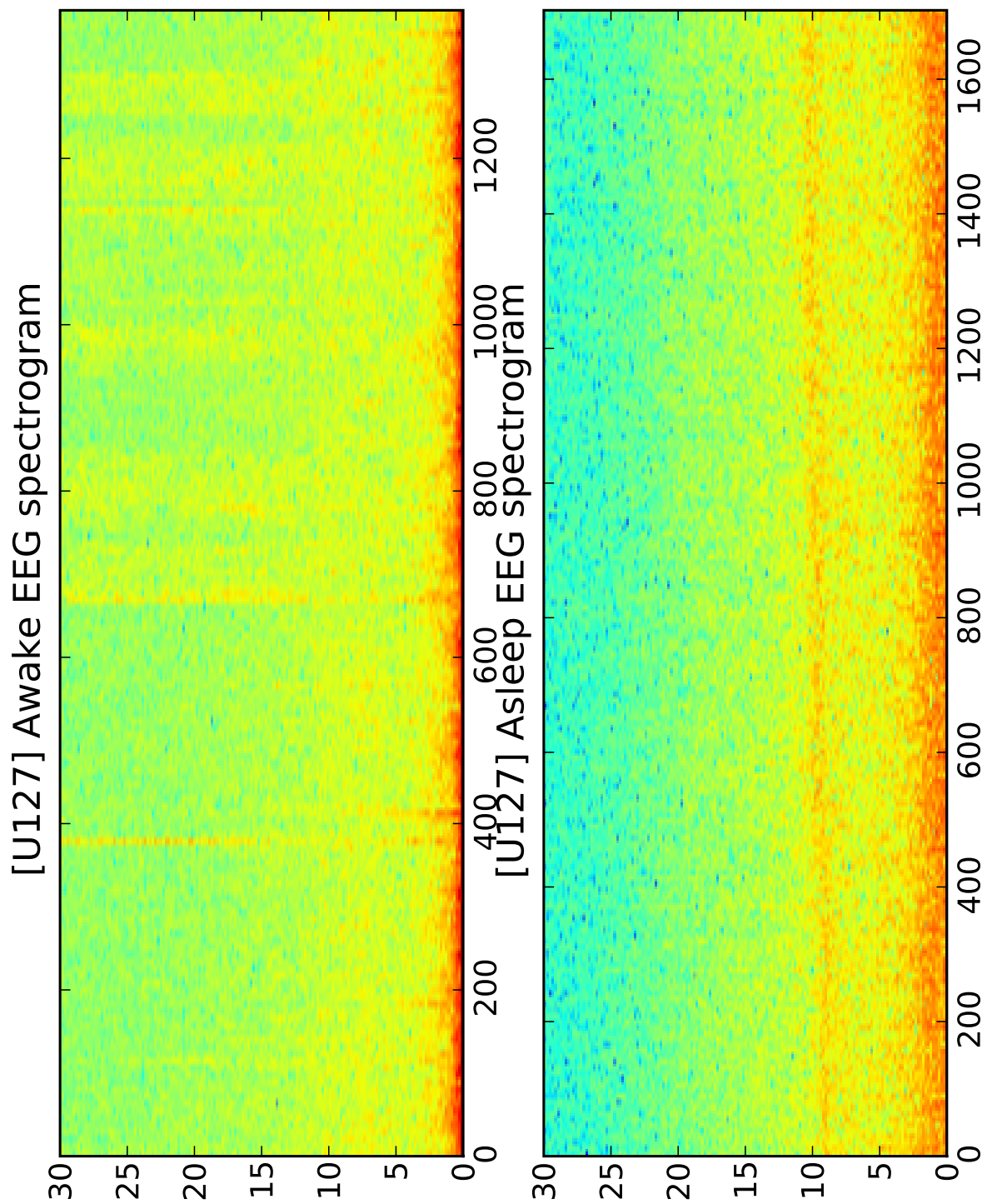


Figure 178: EEG Spectrogram of patient U127

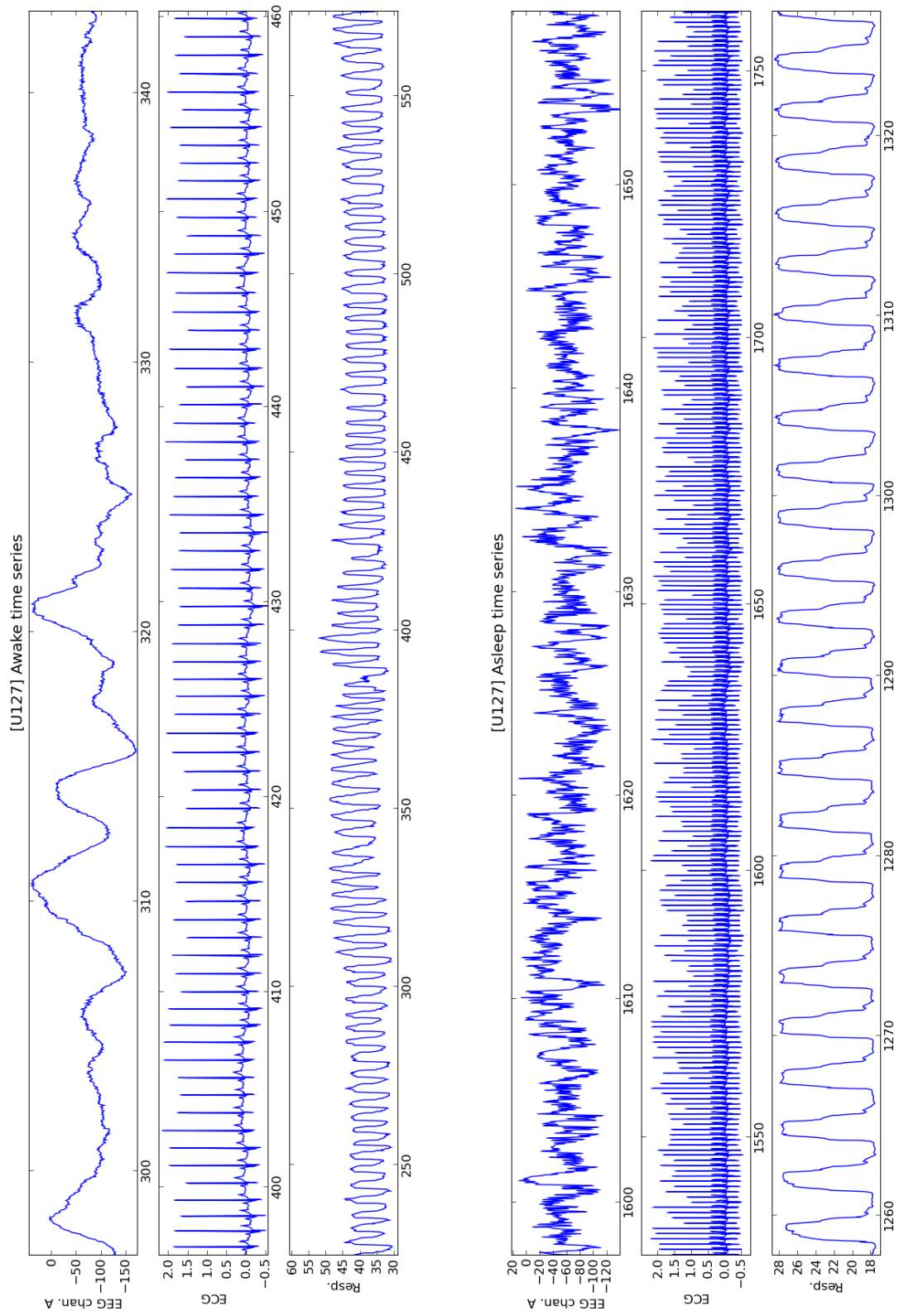


Figure 179: Time series samples of patient U127

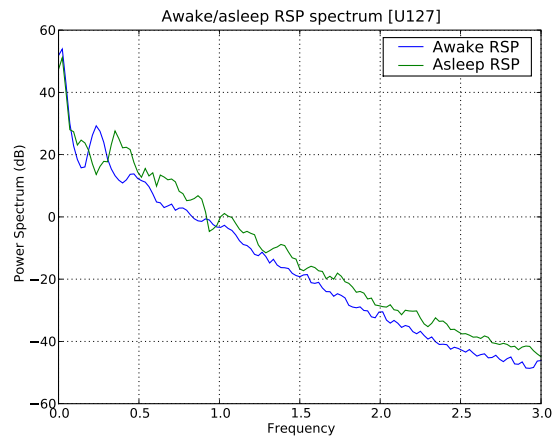
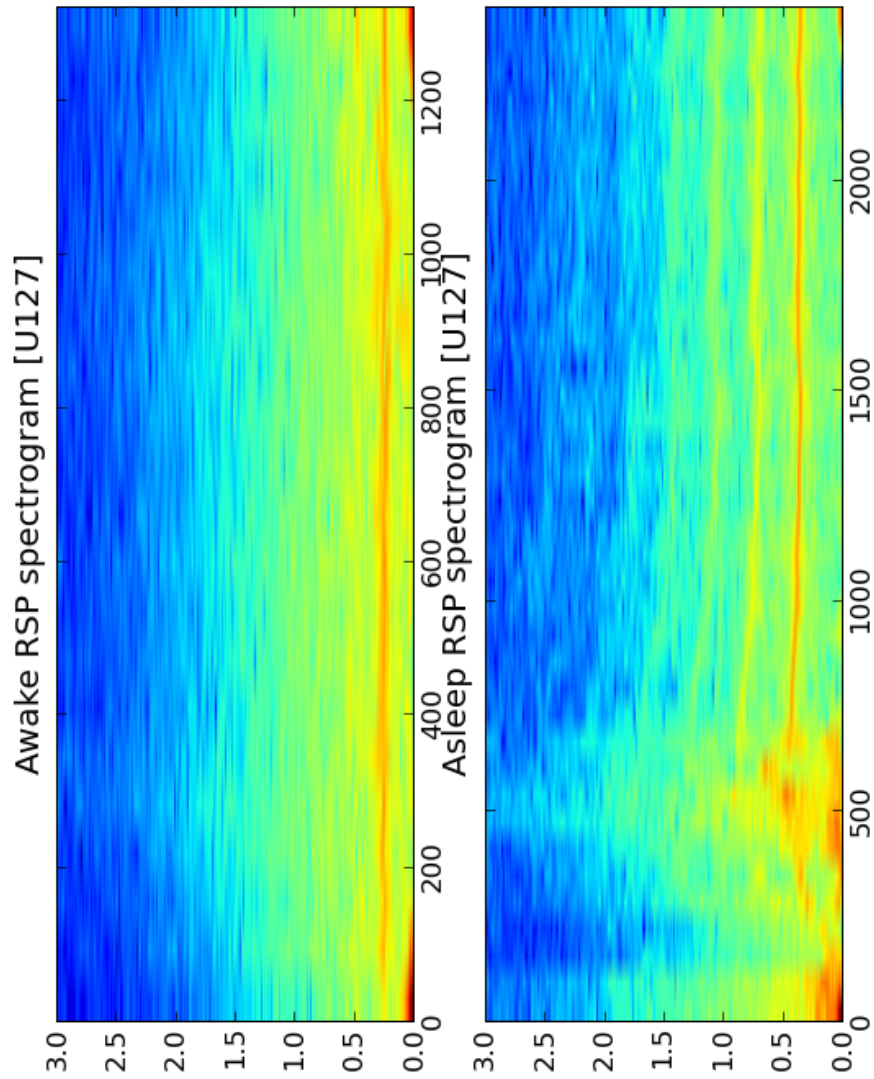


Figure 180: Time series samples of patient U127

3.46 U128

Comments

Propofol with curare was administered. Inverse EEG activity.

Awake EEG Spectrogram shows alpha band 8Hz activity. Some delta band peaks (suspect 0.9, 1.8, 2.7Hz, middle peak very low).

Awake ECG Clear waveform.

Awake Respiration Asymmetric waveform, some irregular breathing. Passable signal. Some signal losses.

Asleep EEG Very unclear diffuse low power alpha band activity 8-13Hz.

Asleep ECG Clear waveform.

Asleep Respiration Sharp peaks, clear waveform, symmetric. Valleys contaminated.

Plots

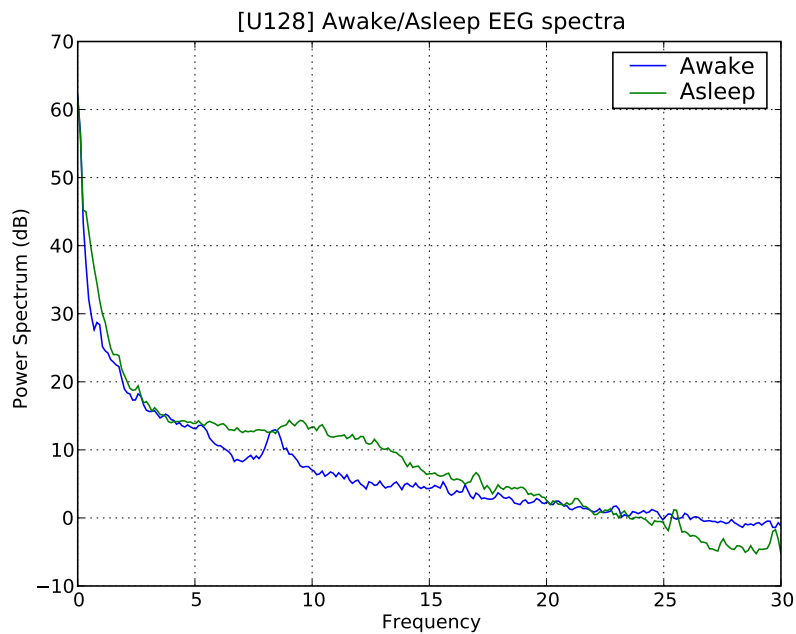


Figure 181: EEG Spectrum of patient U128

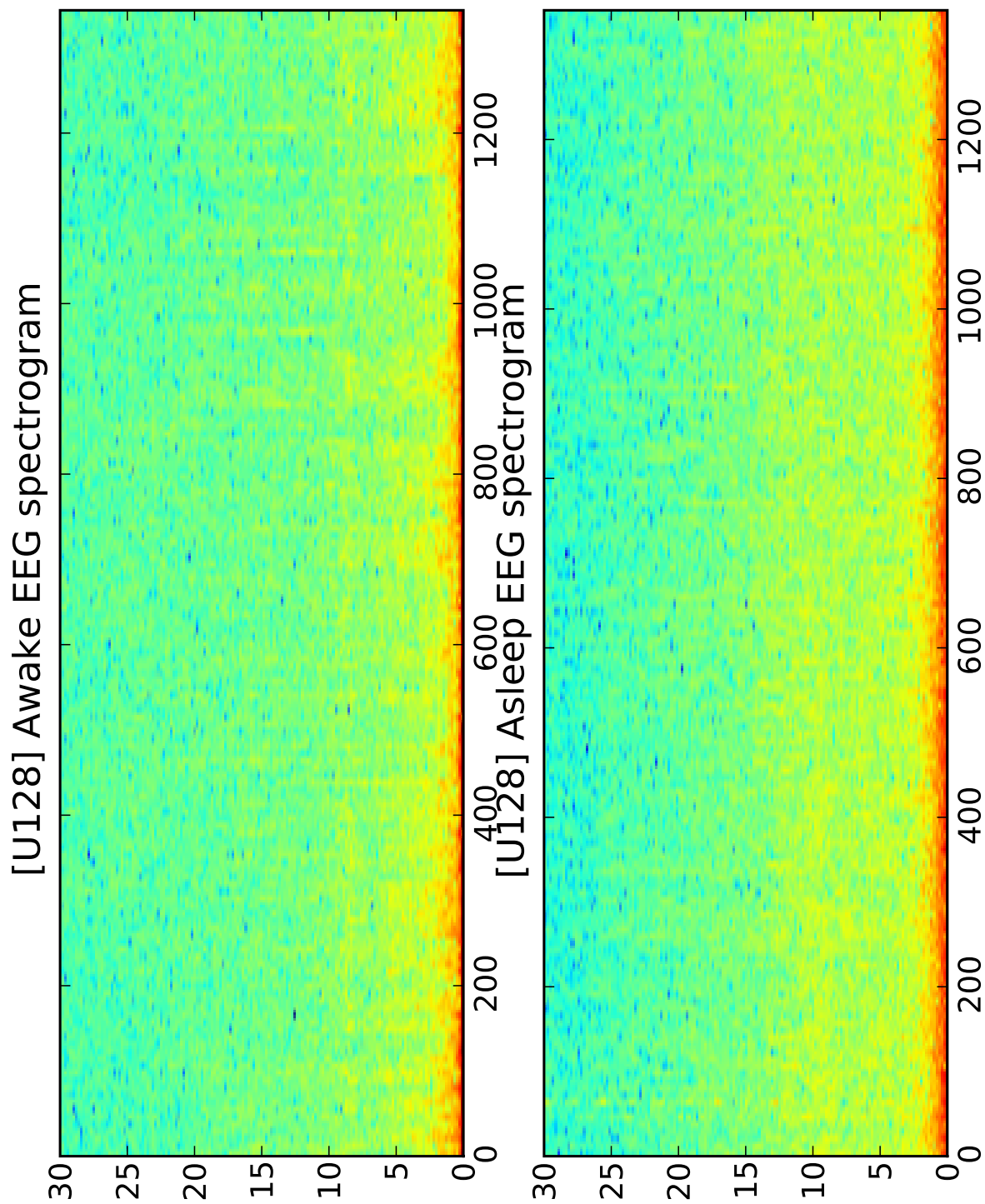


Figure 182: EEG Spectrogram of patient U128

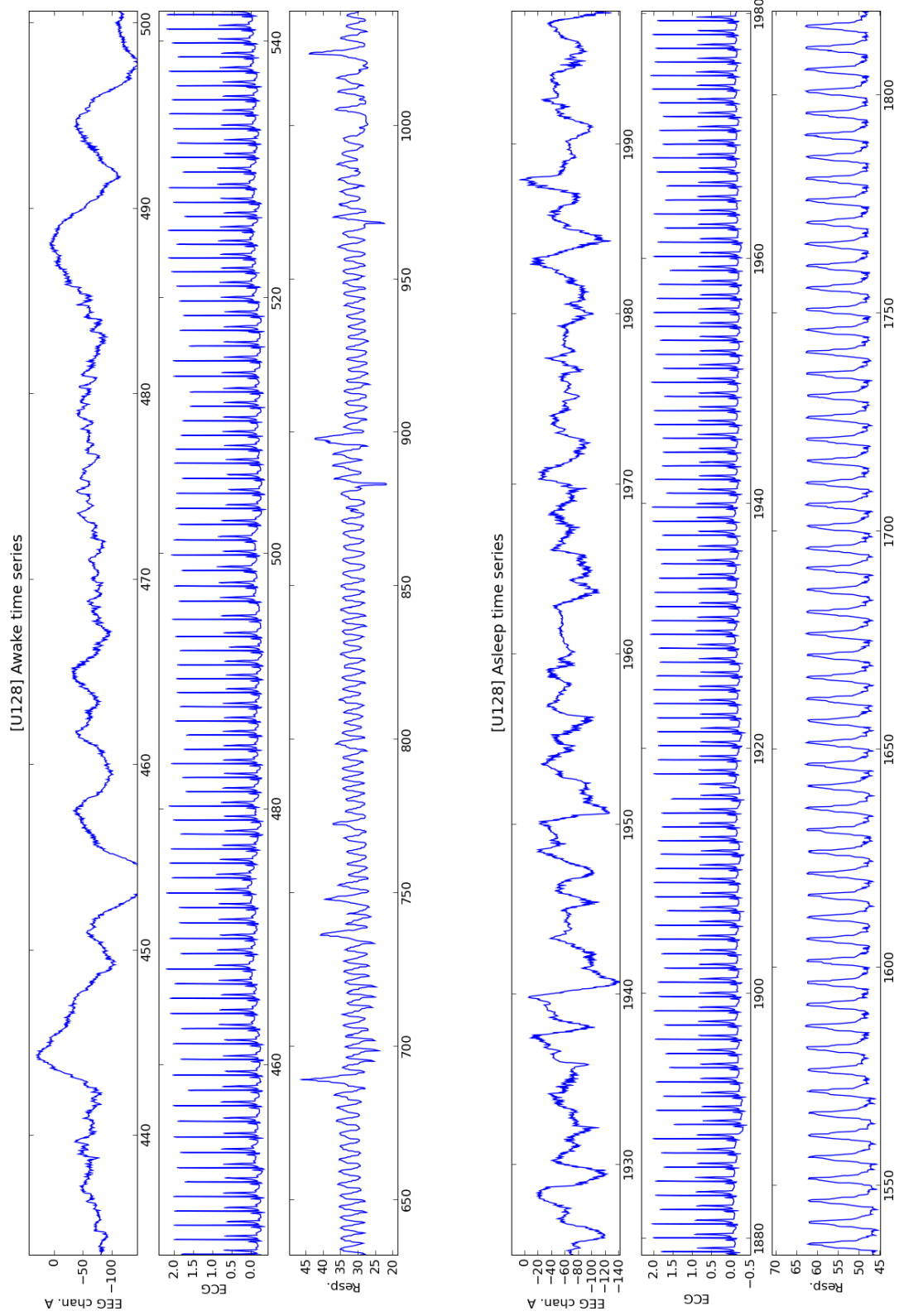


Figure 183: Time series samples of patient U128

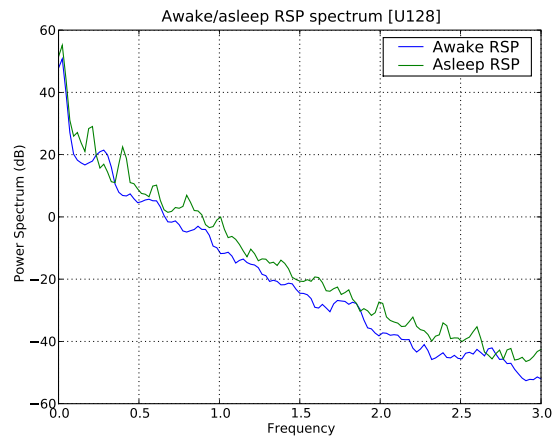
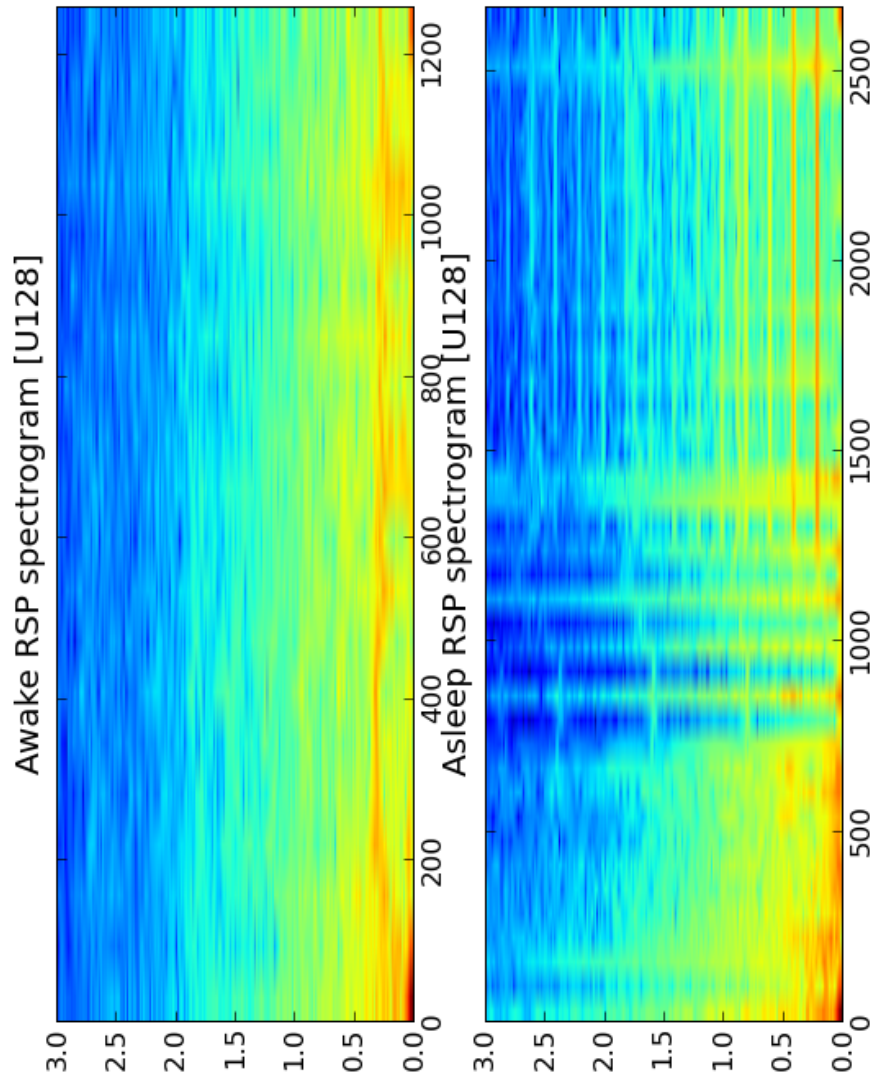


Figure 184: Time series samples of patient U128

3.47 U129

Comments

Propofol was administered. Strong spike at 450s in awake measurements. EEG measurements may be used for case study (delta band mode extraction).

Awake EEG Spectrogram shows 8Hz activity in alpha band.

Awake ECG Stable nice waveform.

Awake Respiration Contaminated waveform, peaks may be shifted. Some amplitude instability.

Asleep EEG Clear 12Hz alpha band activity. Some low power delta band 3.3Hz activity.

Asleep ECG Stable baseline, some amplitude variation, clean waveform.

Asleep Respiration Two sharp spikes, 1800s and 2500s.

Plots

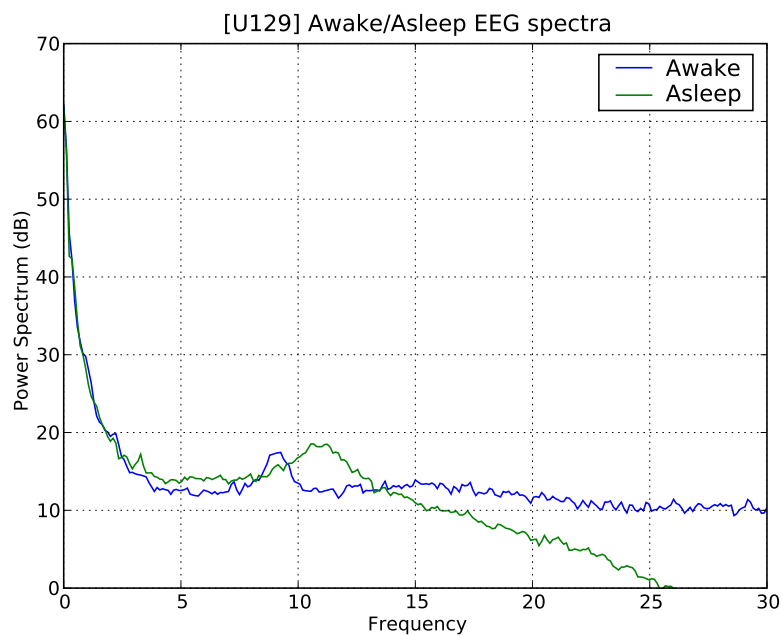


Figure 185: EEG Spectrum of patient U129

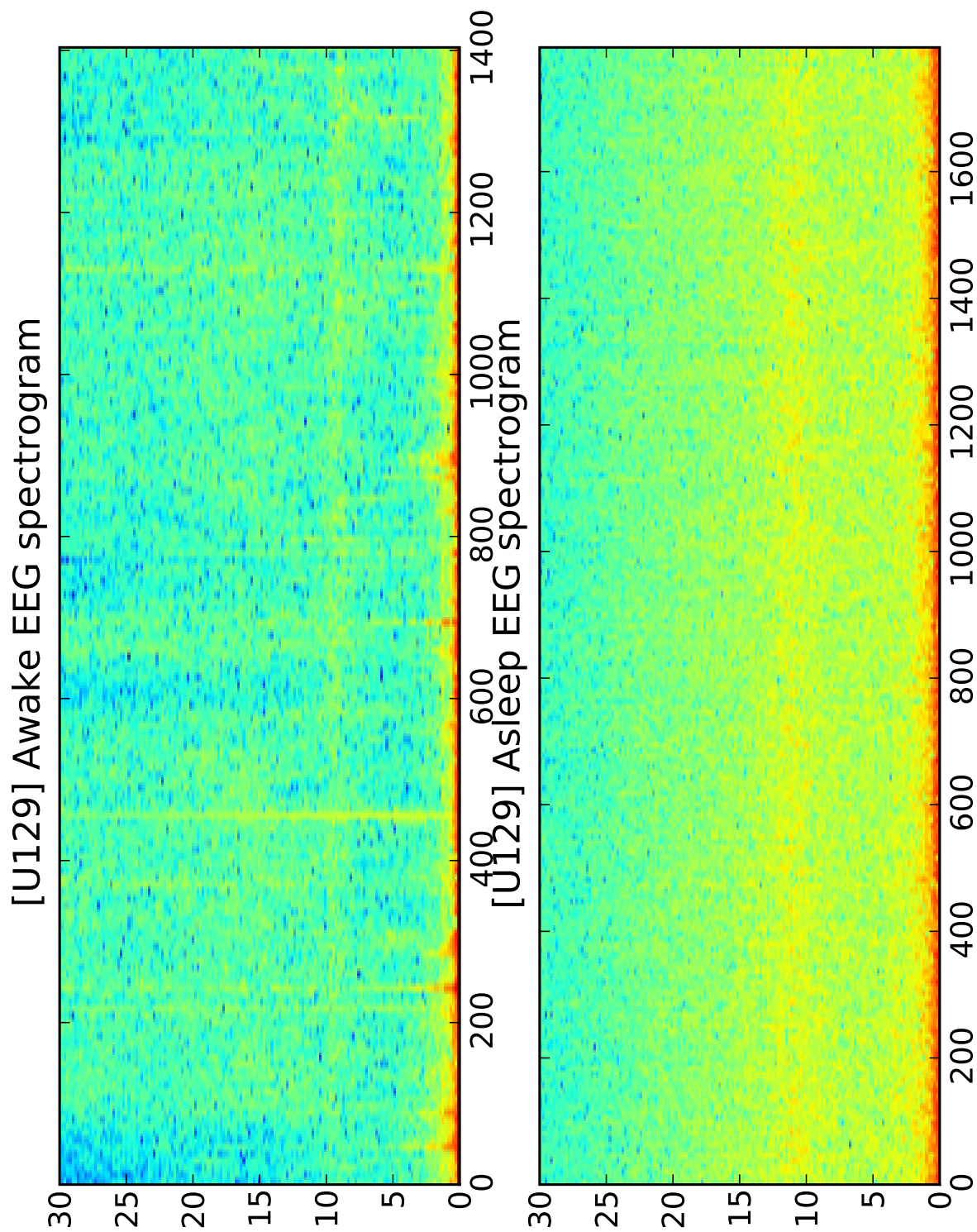


Figure 186: EEG Spectrogram of patient U129

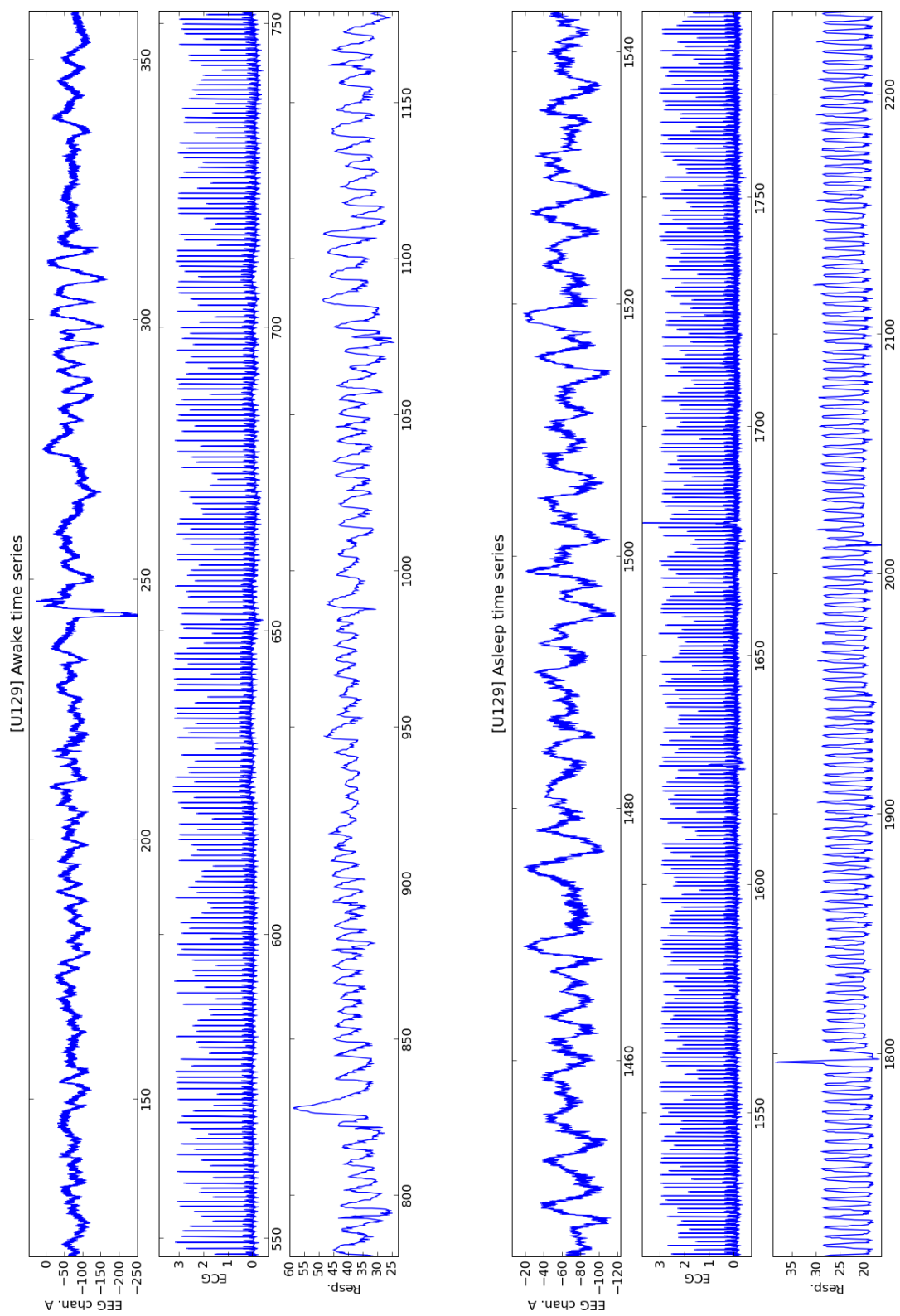


Figure 187: Time series samples of patient U129

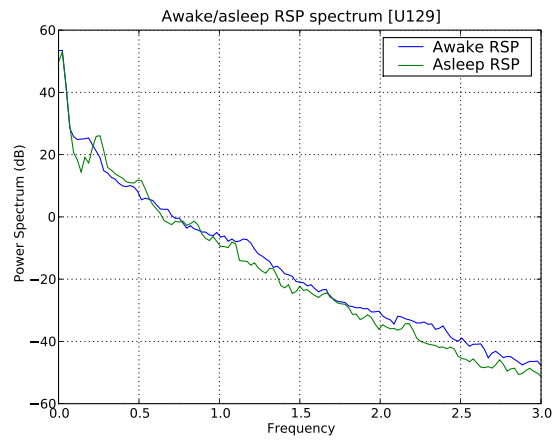
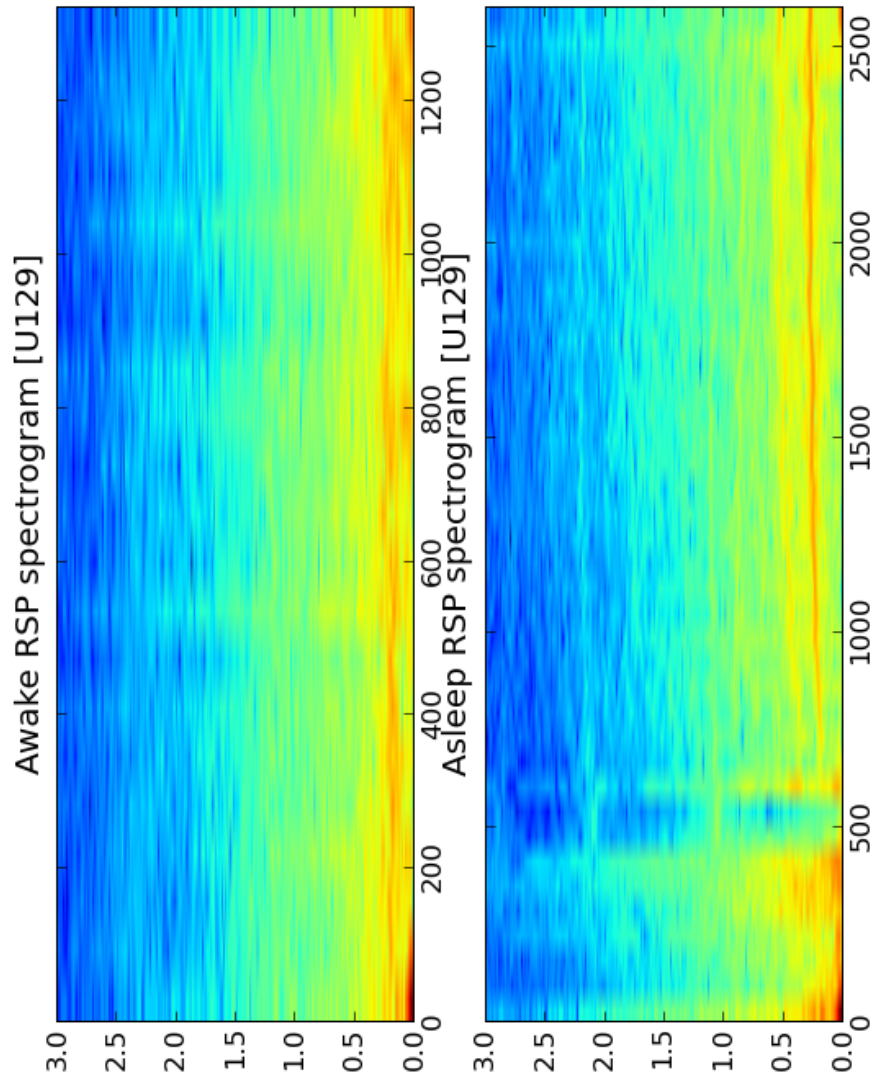


Figure 188: Time series samples of patient U129

3.48 U131

Comments

Sevoflurane with curare was administered. Awake EEG may be useful for oscillation extraction, case study.

Awake EEG Strong spike at 550s. Nonstandard waveform. Spectrum shows 12Hz activity. Some very low power (on threshold) delta band 3.6Hz activity.

Awake ECG Unstable baseline, clean waveform.

Awake Respiration Passable waveform. Some signal faults.

Asleep EEG Clear alpha band 10Hz activity, low power delta activity at 0.8Hz.

Asleep ECG Clean signal, stable baseline.

Asleep Respiration Sharp peaks, valley contamination.

Plots

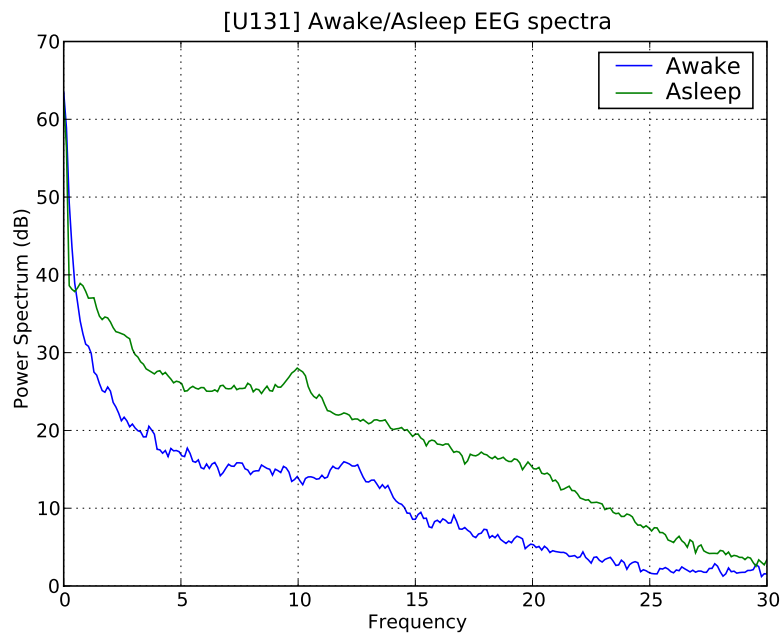


Figure 189: EEG Spectrum of patient U131

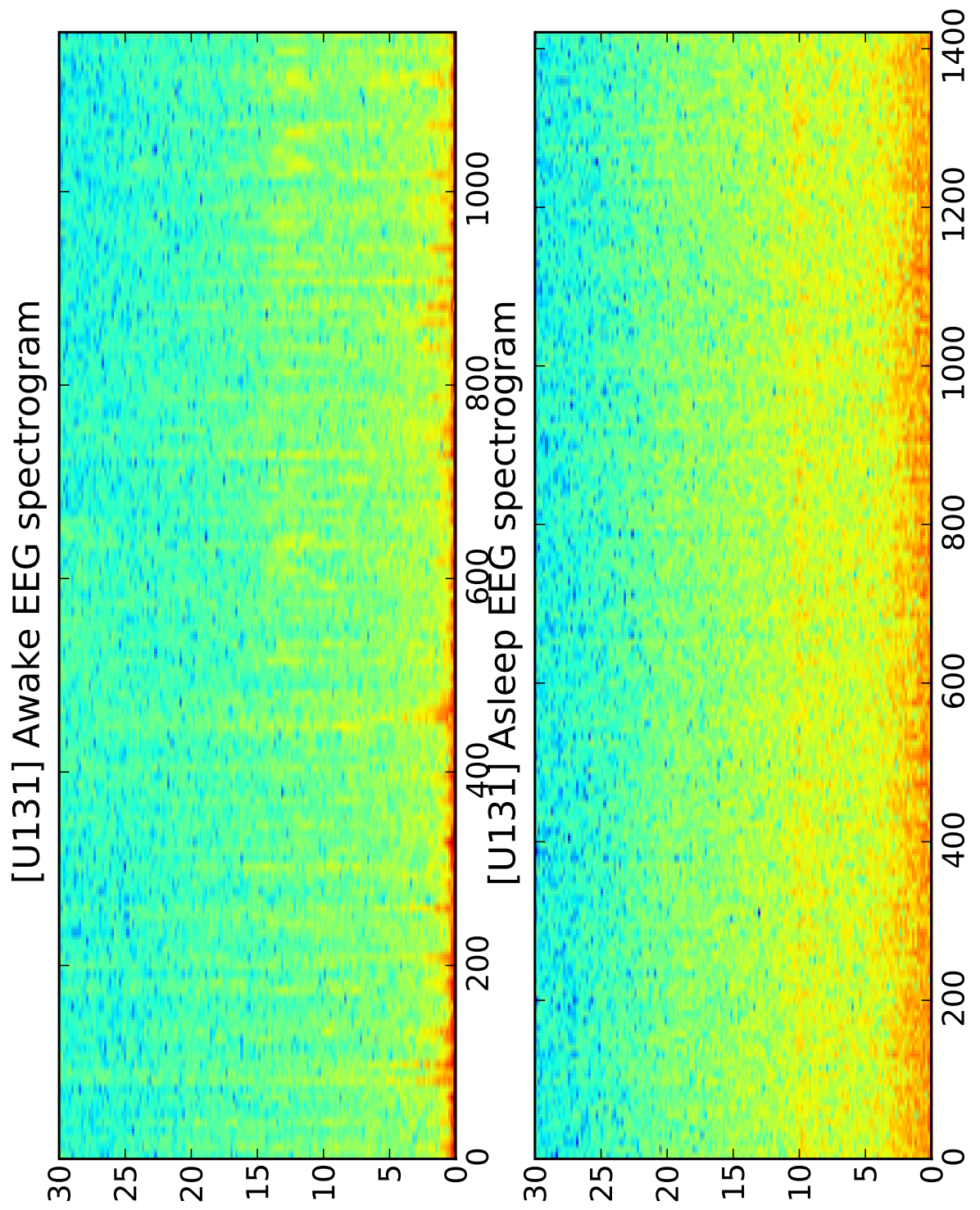


Figure 190: EEG Spectrogram of patient U131

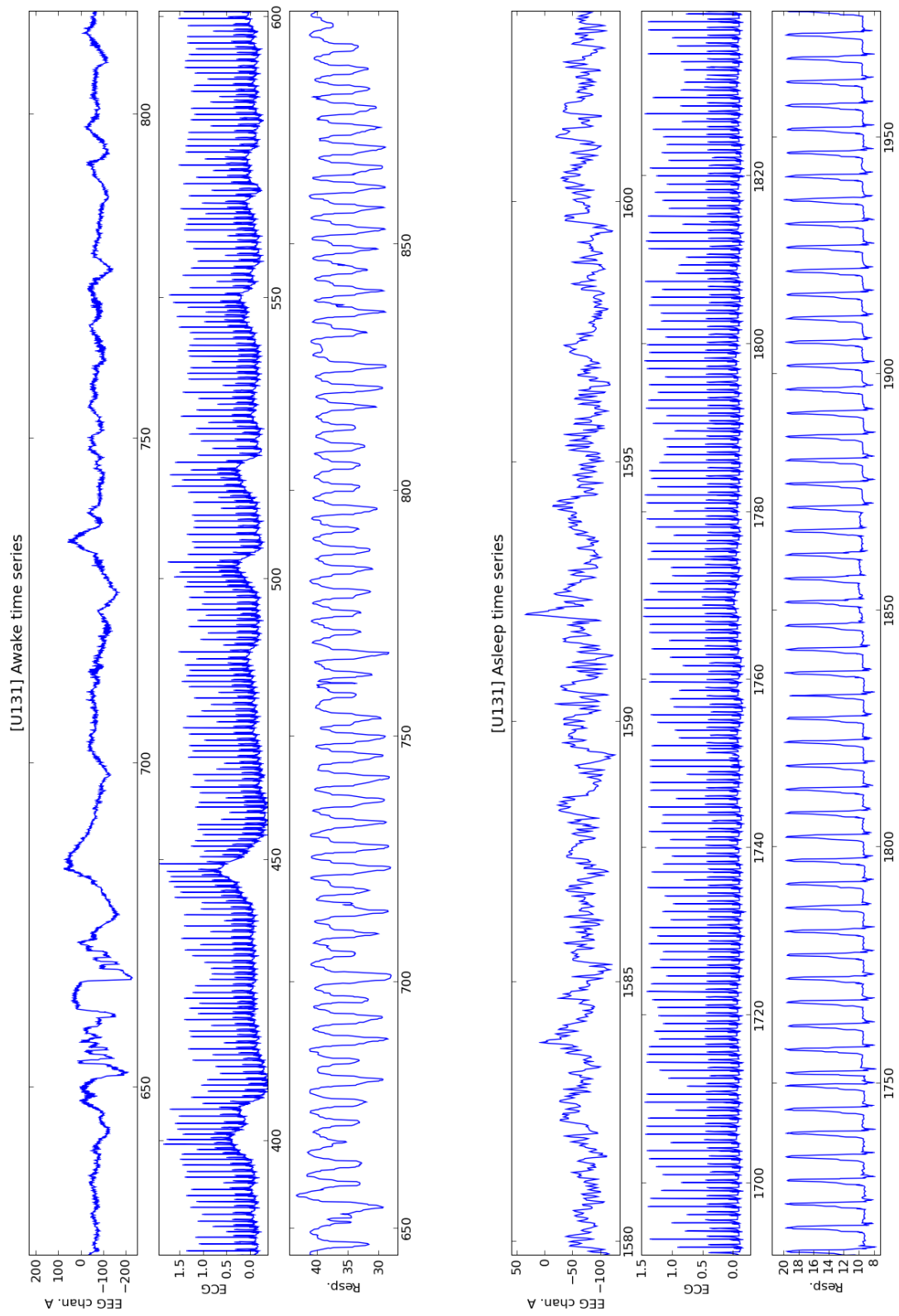


Figure 191: Time series samples of patient U131

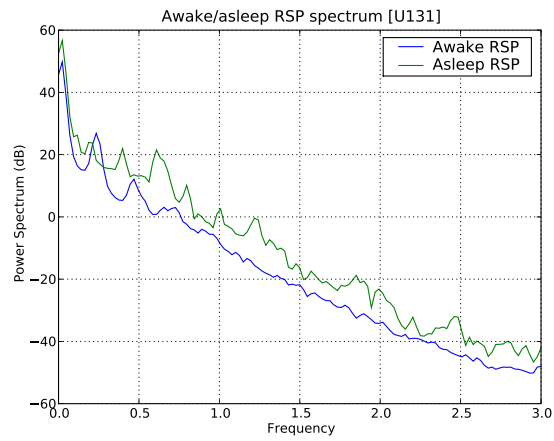
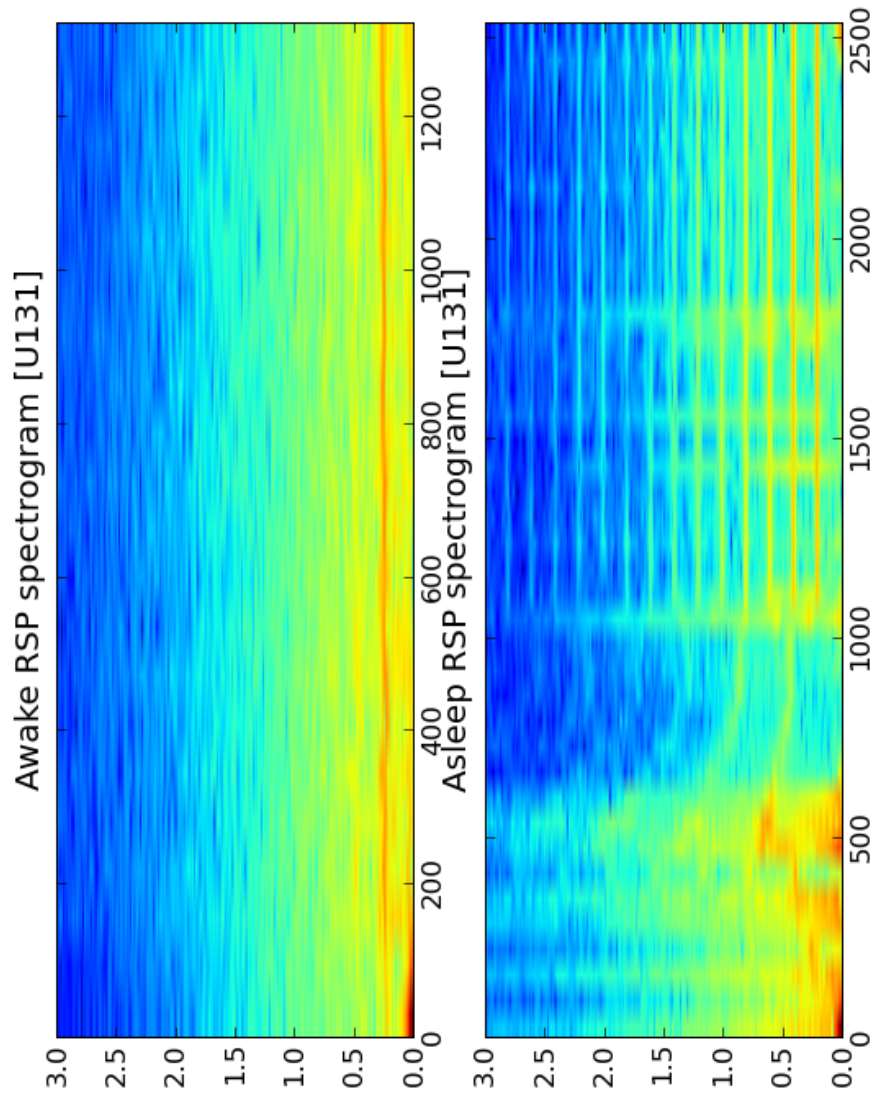


Figure 192: Time series samples of patient U131

3.49 U132

Comments

Sevoflurane was administered.

Awake EEG Reasonable waveform. No clear activity.

Awake ECG Stable baseline, clean signal.

Awake Respiration Some amplitude variations, some signal losses. May not be useable. On threshold.

Asleep EEG Clear 11Hz alpha band activity.

Asleep ECG Stable clean waveform.

Asleep Respiration Asymmetric waveform, contamination in lower parts. Passable quality.

Plots

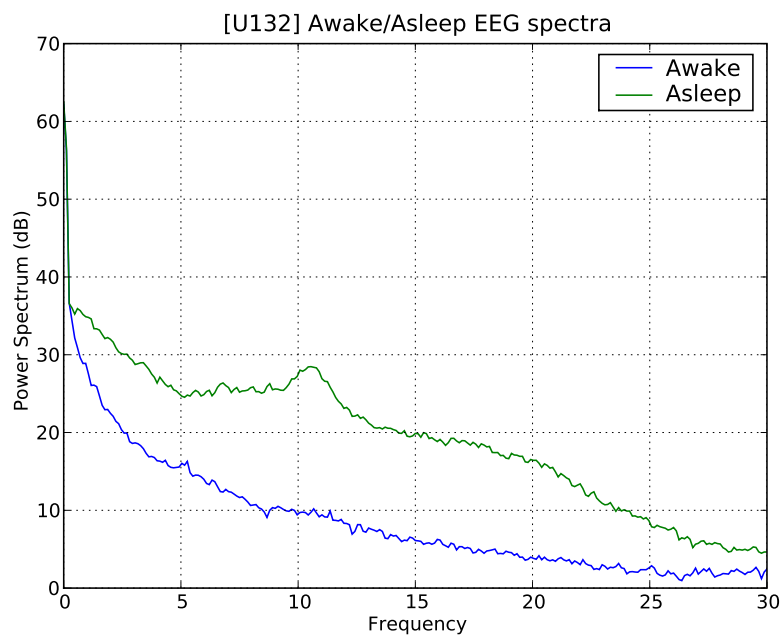


Figure 193: EEG Spectrum of patient U132

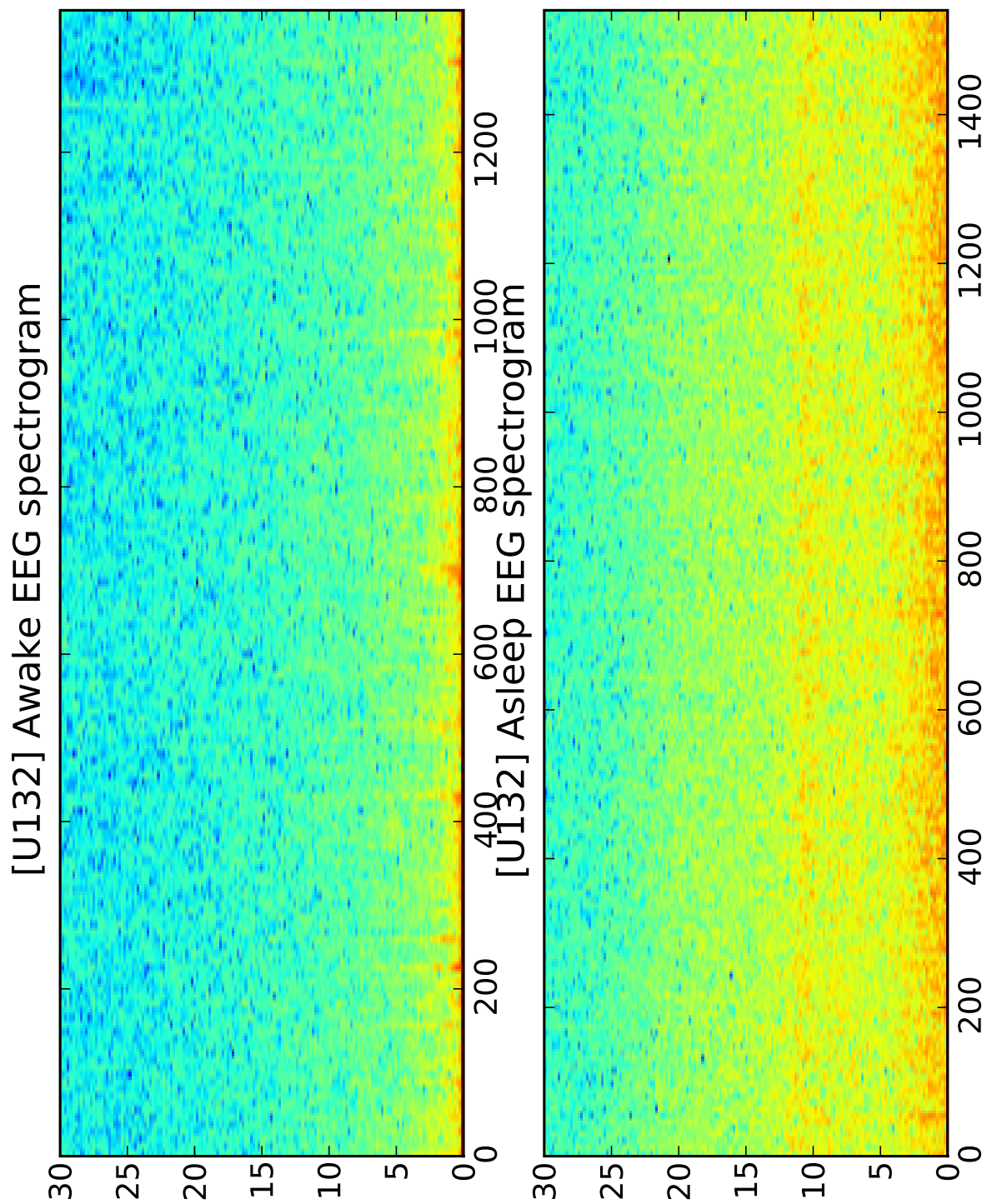


Figure 194: EEG Spectrogram of patient U132

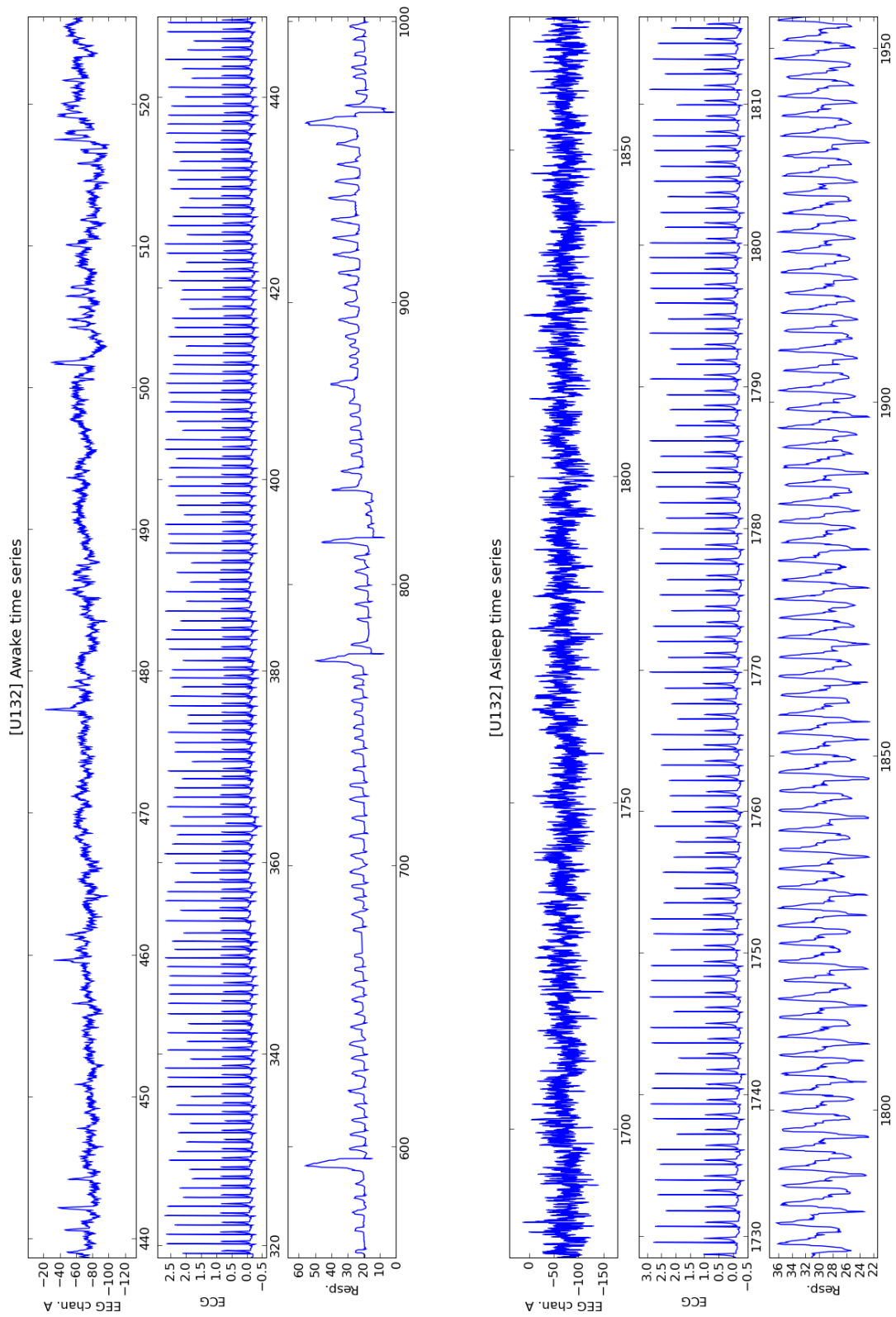


Figure 195: Time series samples of patient U132

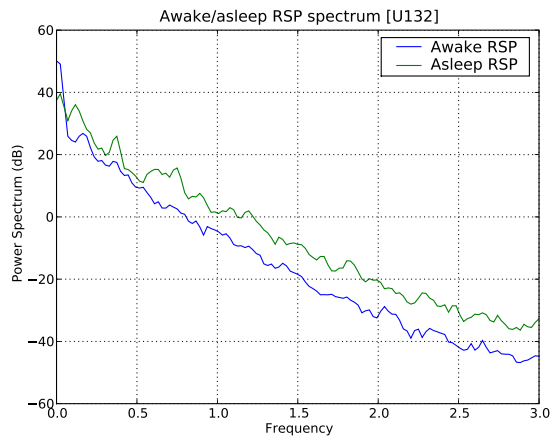
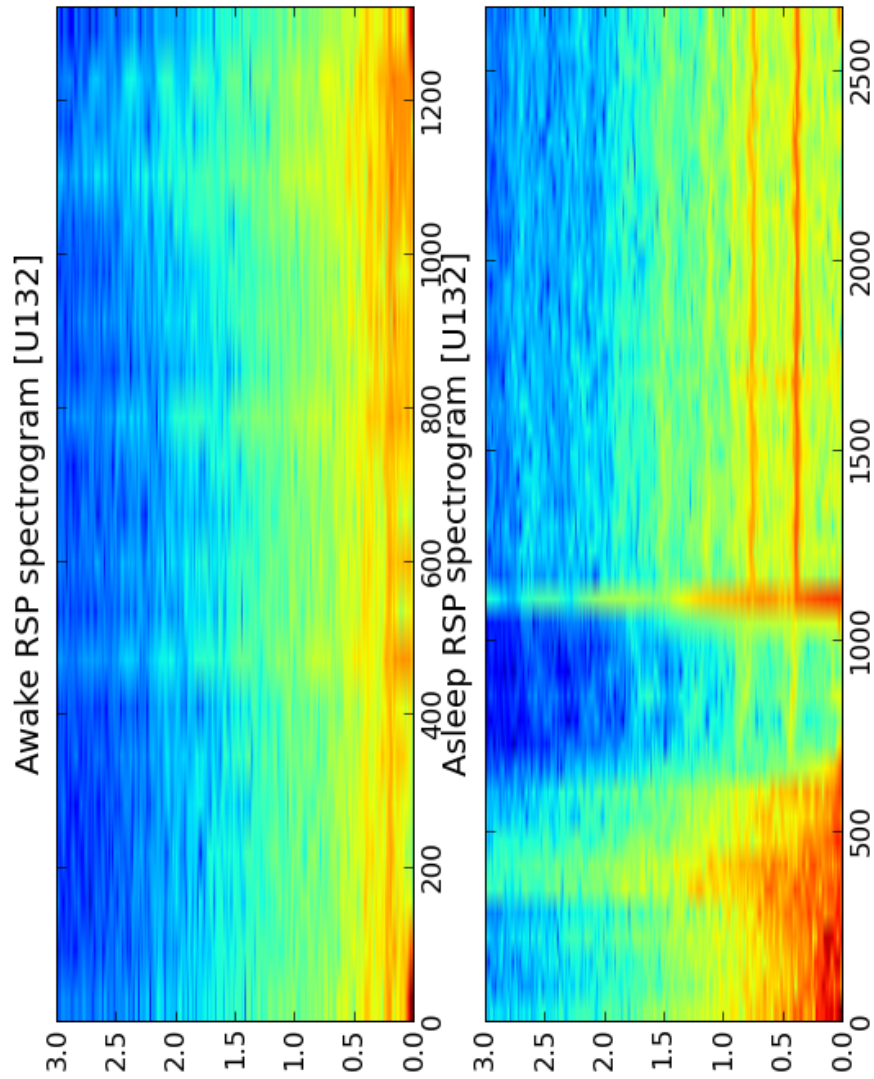


Figure 196: Time series samples of patient U132