

The Relationships Between Quantitative MR Parameters in Hippocampus in Healthy Subjects and Patients With Temporal Lobe Epilepsy

D. WAGNEROVÁ¹, V. HERYNEK¹, M. DEZORTOVÁ¹, P. MARUSIČ², P. KRŠEK³, J. ZÁMEČNÍK⁴, F. JÍRŮ¹, A. ŠKOCH¹, M. HÁJEK¹

¹Department of Diagnostic and Interventional Radiology, Institute for Clinical and Experimental Medicine, Prague, Czech Republic, ²Department of Neurology, Charles University in Prague, Second Faculty of Medicine, Motol University Hospital, Prague, Czech Republic, ³Department of Pediatric Neurology, Charles University in Prague, Second Faculty of Medicine, Motol University Hospital, Prague, Czech Republic, ⁴Department of Pathology and Molecular Medicine, Charles University in Prague, Second Faculty of Medicine, Motol University Hospital, Prague, Czech Republic

Received June 11, 2014

Accepted November 21, 2014

On-line December 22, 2014

Summary

We introduce a new magnetic resonance (MR) method based on a pixel-by-pixel image processing to examine relationships between metabolic and structural processes in the pathologic hippocampus. The method was tested for lateralization of the epileptogenic zone in patients with temporal lobe epilepsy (TLE). Twenty patients with drug-resistant TLE and fifteen healthy controls were examined at 3T. The measurement protocol contained T2-weighted MR images, spectroscopic imaging, diffusion tensor imaging and T2 relaxometry. Correlations between quantitative MR parameters were calculated on a pixel-by-pixel basis using the CORIMA program which enables automated pixel identification in the normal tissue according to control data. All MR parameters changed in the anteroposterior direction in the hippocampus and correlation patterns and their slopes differed between patients and controls. Combinations of T2 relaxation times with metabolite values represent the best biomarkers of the epileptogenic zone. Correlations with mean diffusivity did not provide sufficiently accurate results due to diffusion image distortions. Quantitative MR analysis non-invasively provides a detailed description of hippocampal pathology and may represent complementary tool to the standard clinical protocol. However, the automated processing

should be carefully monitored in order to avoid possible errors caused by MR artifacts.

Key words

Temporal lobe epilepsy • 1H-MR spectroscopy • MR diffusometry • T2 relaxometry • Correlations

Corresponding author

D. Wagnerová, Institute for Clinical and Experimental Medicine, Vídeňská 1958/9, 14021 Prague, Czech Republic. Fax: +420241728224. E-mail: diwa@medicon.cz

Introduction

Magnetic resonance (MR) techniques enable to study different biochemical and biophysical parameters of the brain tissue *in vivo*. MR images based on T1 and T2 relaxation times (T1, T2 resp.), diffusion maps or metabolite concentration maps are broadly used in clinical practice for localizing the pathology. Nevertheless, standard MRI provides only morphological information and the routinely used visual paradigm often fails in non-lesional diseases. Temporal lobe epilepsy (TLE) represents a typical epileptic syndrome where

more detailed data analysis provides additional information about the disease and can help in better comprehension of pathogenic mechanisms.

TLE is potentially surgically-remediable focal epilepsy. Symptomatic TLE is etiologically divided into the syndrome of mesial temporal lobe epilepsy (MTLE) associated with hippocampal sclerosis (HS), lesional TLE caused by different structural lesions, and cryptogenic TLE (Engel 1996). HS is characterized by hippocampal and extrahippocampal atrophy with neuronal loss and astrogliosis in the hippocampus (HC) and in the surrounding regions (Margerison and Corsellis 1966, Bonilha *et al.* 2010).

Sclerotic HC exhibits significantly increased mean diffusivity (MD) ipsilaterally to the epileptogenic focus (Duzel *et al.* 2004, Concha *et al.* 2009) or bilaterally (Keller and Roberts 2008, Knake *et al.* 2009, Bonilha *et al.* 2010). An increase of T2 ipsilaterally (Jack 1996) was attributed to the increased number of glial cells (Pereira *et al.* 2006). Higher T2 relaxation times in the anterior rather than posterior HC were also reported (von Oertzen *et al.* 2002, Bartlett *et al.* 2007).

Proton magnetic resonance spectroscopy (1H-MRS) assessing concentrations of selected metabolites reveals neuronal dysfunction characterized by N-acetylaspartate + N-acetylaspartylglutamate (NAA) decrease, reactive astrogliosis accompanied by creatine (Cr) increase or a dysplastic cortical lesion characterized by choline-containing compounds (Cho) increase. Abnormal NAA/(Cho+Cr) ratios were found in the ipsilateral and sometimes in the contralateral temporal lobe in the TLE patients (Kuzniecky *et al.* 2001, Hajek *et al.* 2008).

Several studies concluded that pathologic extent and lateralization of the epileptogenic zone (EZ) in ambiguous cases may be better resolved by a combination of different diagnostic methods and correlations between different parameters. Negative correlations were found between NAA/(Cho+Cr) and apparent diffusion coefficient (ADC) or the T2 values in the sclerotic HC (Namer *et al.* 1999, Kantarci *et al.* 2002, Pereira *et al.* 2006). Significant correlations between ADC and T2 were observed in the temporal lobe in the patients as well as in the control subjects (Duzel *et al.* 2004).

The aim of this work was to verify the ability of a new MR method based on a pixel-by-pixel image processing to study the relationship between individual biochemical or biophysical parameters and to use their

combination for an examination of the hippocampi in healthy controls and in patients with TLE. The findings based on correlations between 1H-MRS, T2 relaxometry and diffusometry were compared with EZ lateralization using standard pre-surgical evaluations and histopathological data available after epilepsy surgery.

Methods

Subjects

Twenty TLE patients (mean age 29.6±12.4 years) evaluated before planned resective surgery for intractable epilepsy in Motol Epilepsy Center were involved in the study. Demographic and clinical data are summarised in Table 1. Fifteen patients had abnormal radiological findings in the hippocampus classified as lesional epilepsy while the remaining five patients were regarded non-lesional. The surgical side was determined according to the electro-clinical correlation and the results of all pre-operative investigations. Fifteen patients underwent temporal lobe resection and, accordingly, their histopathological findings were available (Table 1).

Fifteen healthy subjects (mean age 24.0±2.2 years), carefully interviewed to exclude any diseases affecting the obtained data, were included in this study as controls.

All subjects provided their informed consent approved by the local ethical committee. Clinical protocols are certified according to the ISO 9001:2008 norm.

MR measurements

The patients underwent a standard clinical MRI at 1.5T used for radiological evaluation. Consequently, the patients underwent a supplementary examination on a 3T tomograph (Siemens Medical Systems, Erlangen, Germany) equipped with a transmit-receive head coil aimed on DTI, spectroscopic imaging (SI) and T2 relaxometry. The images were positioned in parallel to the long hippocampal axis and special attention was paid to the symmetric positioning over both HC.

1H-MR spectroscopy: The SI data were obtained using a 2D Point Resolved Spectroscopy (PRESS-CSI) sequence with echo time (TE)/repetition time (TR)/number of acquisitions (NA) = 135 ms/1510 ms/4, field of view (FOV) 160×160×15 mm³, a 16×16 phase encoding matrix, nominal voxel volume 1.5 ml, with and without water suppression.

T2 relaxometry: A modified 32-echo Carr-

Purcell-Meiboom-Gill (CPMG) sequence was used with the following parameters: TR=3000 ms, echospacing $\Delta TE=13.2$ ms, NA=1, slice thickness (ST)=5 mm. FOV was adjusted according to the patient's head size with a constant in-plane pixel size 0.78×0.78 mm².

Diffusion tensor imaging: DTI data were acquired using an echo planar imaging spin echo diffusion tensor pulse sequence (TR/TE/NA=7100 ms/98 ms/3, 20 directions, 44 slices, ST=2.5 mm without a slice gap, FOV adjusted according to the patient's head size with a constant in-plane pixel size 2.0×2.0 mm², b=0; 1000 s/mm²).

The entire protocol was performed in twelve patients, T2 relaxometry was omitted in four patients, and DTI also in four patients. In two patients, the MRS data were available only from one HC due to technical reasons.

Data processing

SI data were analyzed using a jSIPRO program (Jiru *et al.* 2013) with LCModel (Provencher 1993). The data processing included Hamming k-space filtering and the zero filling to a 32×32 matrix size. A water signal was used as an internal calibration for the calculation of the metabolic concentration in the laboratory units. The data were corrected neither for the relaxation times nor for the content of cerebrospinal fluid as it was unnecessary for the proposed method and the exact absolute concentrations were not the stated aim of the study.

DTI data were processed with FSL 4.1.5 (<http://www.fmrib.ox.ac.uk/fsl/>). Eddy current, motion artifact corrections and averaging of the individual data acquisitions was performed. Brain extraction with a fractional intensity threshold equal 0.3 was undertaken. Mean diffusivity was calculated in each voxel from the brain-extracted data using the FSL DTIfit tool.

T2 relaxation maps were calculated using the ViDi program (Herynek *et al.* 2012). Image pre-processing included the image matrix reduction (to in-plane resolution 1.56×1.56 mm² to adapt it to the spectroscopic resolution and to increase the signal-to-noise ratio (SNR)), and exclusion of points with a low SNR prior to the fitting.

The conventional MR images were visually assessed by experienced neuroradiologists and epileptologists.

Correlation analysis

Correlations between metabolic images and

diffusion or T2 relaxation maps were calculated using the CORIMA program (Wagnerova *et al.* 2009). The correlations were based on a pixel-by-pixel evaluation of two different MR methods which allows studying mutual dependences of MR parameters. The software enables a user to select a region of interest (ROI) in one map (metabolite, relaxation, or diffusion), automatically find the corresponding region in another map and consequently create the correlation plot. Each point inside the plot then corresponds to one pixel inside the selected ROI. Hippocampal ROIs were selected manually according to MRI. Both hippocampi were evaluated separately in each subject. The metabolic maps as well as maps of metabolic ratios were used. Only voxels with an error (Cramer-Rao bound) of the calculated metabolic concentrations lower than 15 % were included in the analysis (Jiru *et al.* 2006). Areas in which the relaxation times were not calculated due to low SNR or a failure of the fitting algorithm were excluded from the T2 correlations.

The program facilitates the automatic identification of pixels in the normal tissue according to the control data, highlights them on corresponding MR maps and then shows regions with parameter abnormalities and pathology extent. The minimum (MIN) and maximum (MAX) values for each MR parameter in the hippocampus were assessed as a Mean – standard deviation (SD) of the control data set, and Mean + SD, respectively. High MD values in the vicinity of the brain stem were excluded from the control data set. MIN and MAX values define the control data interval (highlighted in correlation plots by shading and bordered by blue lines) used for the semiautomatic evaluation of patients' data for each image (Wagnerova *et al.* 2009). The program automatically interpreted each pixel falling inside this interval as representing a healthy tissue, and pixels with metabolic, MD or T2 values outside this interval as pathologic (Table 1, columns MRS-MD and MRS-T2 denoting correlations between metabolites and MD, T2 resp.). Significant changes in both HC were interpreted as bilateral pathology. Bilateral changes with significant asymmetry in at least one MR parameter were interpreted as bilateral pathology with one side predominance.

A linear fit was used for the correlation analysis. Mann-Whitney U-test was used for comparison of correlation slopes between different patient groups and controls. The probability level $p < 0.05$ was considered as a statistically significant difference.

Table 1. Demographic, electro-clinical, radiological, correlation and histopathological data of all patients involved in the study.

Patient No., sex	Age/epilepsy duration (years)	Electro-clinical diagnosis	MRI finding	MRS-MD lateralization	MRS-T2 lateralization	Histopathological finding
1,m	32/14	TLE sin	normal	HC sin	HC sin	no surgery
2,f	34/19	TLE sin	normal	HC sin	NA	no surgery
3,f	35/21	TLE sin	normal	HC bilat (sin)	NA	no surgery
4,m	20/6	TLE sin	normal	NA	HC bilat (sin)	normal
5,f	19/12	MTLE dx	normal [#]	HC dx	HC dx	FCD 1B
6,m	40/14	MTLE sin	T2W increased signal in left T pole	HC bilat (sin)	HC bilat (sin)	HC non-specific gliosis, FCD 2A
7,f	41/23	MTLE sin	T2W increased signal in left PHG	NA	normal HCdx*	HC non-specific gliosis, FCD 1B
8,f	18/8	MTLE dx	HS dx	HC bilat (sin)	HC bilat (dx)	isolated HS
9,m	20/7	MTLE dx	HS dx	HC dx	HC dx	isolated HS
10,f	20/15	MTLE sin	HS sin	HC bilat (sin)	HC sin	isolated HS
11,f	18/14	MTLE sin	HS sin, T2W increased signal and atrophy in T pole	HC sin	HC bilat (sin)	HS, FCD 1A
12,m	41/9	MTLE dx	HS dx	HC bilat	HC bilat (dx)	HS, FCD 1A
13,f	15/11	MTLE sin	HS sin, T2W increased signal and atrophy in T pole	HC sin	HC sin	HS, FCD 1B
14,m	32/3	MTLE sin	HS sin	HC bilat (sin)	NA	HS, FCD 1B
15,m	18/6	MTLE sin	HS sin, T2W increased signal and atrophy in T pole	HC sin	HC sin	HS, post-inflammation gliosis
16,m	57/10	MTLE dx	HS dx	HC bilat (dx)	HC bilat	HS, post-inflammation gliosis
17,m	53/37	MTLE dx	HS dx	HC bilat (dx)	HC bilat (dx)	no surgery
18,f	34/34	TLE dx	HS dx	NA	HCdx	no surgery
19,m	27/20	MTLE dx	T2W increased signal in right amygdala, PHG and HC	NA	HC bilat (dx)	complex malformation of HC, FCD 2B
20,f	18/1	TLE dx	right basal posterior temporal tumour	HC dx*	NA	ganglioglioma, FCD 1A

MRS-MD and MRS-T2 correlations were evaluated in the hippocampi only. MRS – magnetic resonance spectroscopy, MD – mean diffusivity, T2 – T2 relaxation time, m – male, f – female, dx – right, sin – left, T – temporal lobe, PHG – parahippocampal gyrus, bilat (dx) – bilateral pathology with the right side predominance, bilat (sin) – bilateral pathology with the left side predominance, (M)TLE – (mesial) temporal lobe epilepsy, T2W – T2 weighted images, HS – hippocampal sclerosis, HC – hippocampus, WM – white matter, MCD – malformation of cortical development, FCD – focal cortical dysplasia, NA – not available, # – diagnosed with developmental anterobasal temporal encephalocele, * – data from HC sin not available.

Table 2. Correlation slope, type and correlation coefficient between selected parameters in controls and patients' abnormal hippocampi.

	Controls	Non-lesional HC	Lesional HC	Controls	Non-lesional HC	Lesional HC
Correlation	Correlation	Correlation	Correlation	Correlation	Correlation	Correlation
	Slope A	Slope A	Slope A	Type (r)	Type (r)	Type (r)
MD-T2	23000±14600	21200±5200	18300±1100	P (0.38±0.16)	P (0.47±0.11)	P (0.61±0.16)
Cr/NAA-T2	0.006±0.004	0.013±0.003 ⁺	0.011±0.004 [#]	P (0.59±0.19)	P (0.59±0.12)	P (0.76±0.09)
Cr/NAA-MD	280±220	620±500	180±110	P (0.32±0.17)	P (0.41±0.19)	P (0.49±0.21)
Cho/NAA-T2	0.005±0.002	0.005±0.002	0.003±0.001	P (0.68±0.13)	P (0.64±0.13)	P (0.76±0.07)
Cho/NAA-MD	240±160	230±260	80±40 [#]	P (0.46±0.17)	P (0.45±0.22)	P (0.47±0.20)
Cho/Cr-T2	0.004±0.001	0.0018±0.0009	0.0008±0.0008 [#]	P (0.64±0.17)	P (0.63±0.12)	Ø (0.37±0.38)
Cho/Cr-MD	170±120	30±110	9±30 [#]	P (0.44±0.25)	Ø (0.28±0.40)	Ø (0.21±0.37)
Cho-T2	0.010±0.008	0.013±0.004 [*]	0.005±0.002 [*]	P (0.49±0.17)	P (0.68±0.13)	P (0.74±0.05)
Cho-MD	420±370	410±410	110±80	P (0.37±0.27)	P (0.37±0.21)	P (0.47±0.22)
Cr-T2	-0.01±0.02	0.020±0.006 ^{*+}	0.008±0.006 ^{*#}	Ø (-0.05±0.43)	P (0.59±0.15)	P (0.59±0.23)
Cr-MD	-530±1160	960±450 [*]	230±200 [*]	Ø (-0.03±0.38)	P (0.39±0.09)	P (0.39±0.23)
NAA-T2	-0.04±0.02	-0.022±0.018	-0.021±0.008	N (-0.62±0.13)	N (-0.38±0.20)	N (-0.74±0.06)
NAA-MD	-2180±1840	-1360±2090	-490±330 [#]	N (-0.30±0.18)	Ø (-0.26±0.35)	N (-0.54±0.12)

Mean value and its standard deviation over each group was calculated for correlation slope A and correlation coefficient r. Equation of linear regression $y=A.x+B$ was used to calculate a correlation slope A. *, +, # statistically significant difference ($p<0.05$) between both patients' groups, non-lesional epilepsy and controls resp., lesional epilepsy and controls resp. MD – mean diffusivity, T2 – T2 relaxation times, Cho – choline containing compounds, Cr – total creatine, NAA – N-acetylaspartate + N-acetylaspartylglutamate, P – positive correlation, N – negative correlation, Ø – no correlation.

Neuropathology

Tissue specimens taken during resective surgery were fixed in a 10% neutral buffered formalin and embedded in paraffin. Routine hematoxylin-eosin (HE) and cresyl violet staining were performed. A significant loss of pyramidal neurons in both the CA1 and CA4 hippocampal sectors accompanied by gliosis was interpreted as HS. To assess the degree of gliosis in both the hippocampus and the resected neocortex, standard immunoperoxidase staining was performed using antibodies against the glial fibrillary acidic protein (clone 6F2, DakoCytomation).

Palmini's classification (Palmini *et al.* 2004) was used for evaluating malformations of cortical development.

Results

Electro-clinical, radiological, correlation and histopathological features for each patient are listed in Table 1. Correlations of metabolic data with MD and T2 were calculated for both the control and patient groups. In all groups MD and T2 (MD-T2) revealed positive correlation. MD, T2, Cho and metabolic ratios Cr/NAA, Cho/Cr, Cho/NAA gradually decreased (Figs 1, 2) and NAA gradually increased in the anteroposterior direction

of the hippocampus in all subjects. The slopes and correlation coefficients are listed in Table 2.

Correlation findings in the control group

Positive correlation was found between T2 (or MD) and following metabolites (or metabolite ratios): Cho, Cr/NAA, Cho/Cr, Cho/NAA. NAA correlates with T2 or MD (NAA-T2, NAA-MD resp.) negatively and no correlation was found between Cr and T2 or MD (Table 2).

Based on the control group results, control intervals of each parameter were assessed and used for the subsequent semiautomatic evaluation (Figs 1, 2).

Correlation in non-lesional TLE patients

Automatic evaluation based on control data revealed abnormal metabolic values in at least one HC in all patients with non-lesional epilepsy. In two cases, the abnormal values were found also in the contralateral HC and they were thus classified as a bilateral pathology with one side predominance (Table 1). In the remaining cases, the contralateral hippocampal findings corresponded to the healthy controls. The semiautomatic evaluation based on control data lateralized all the cases in accordance with the electro-clinical results.

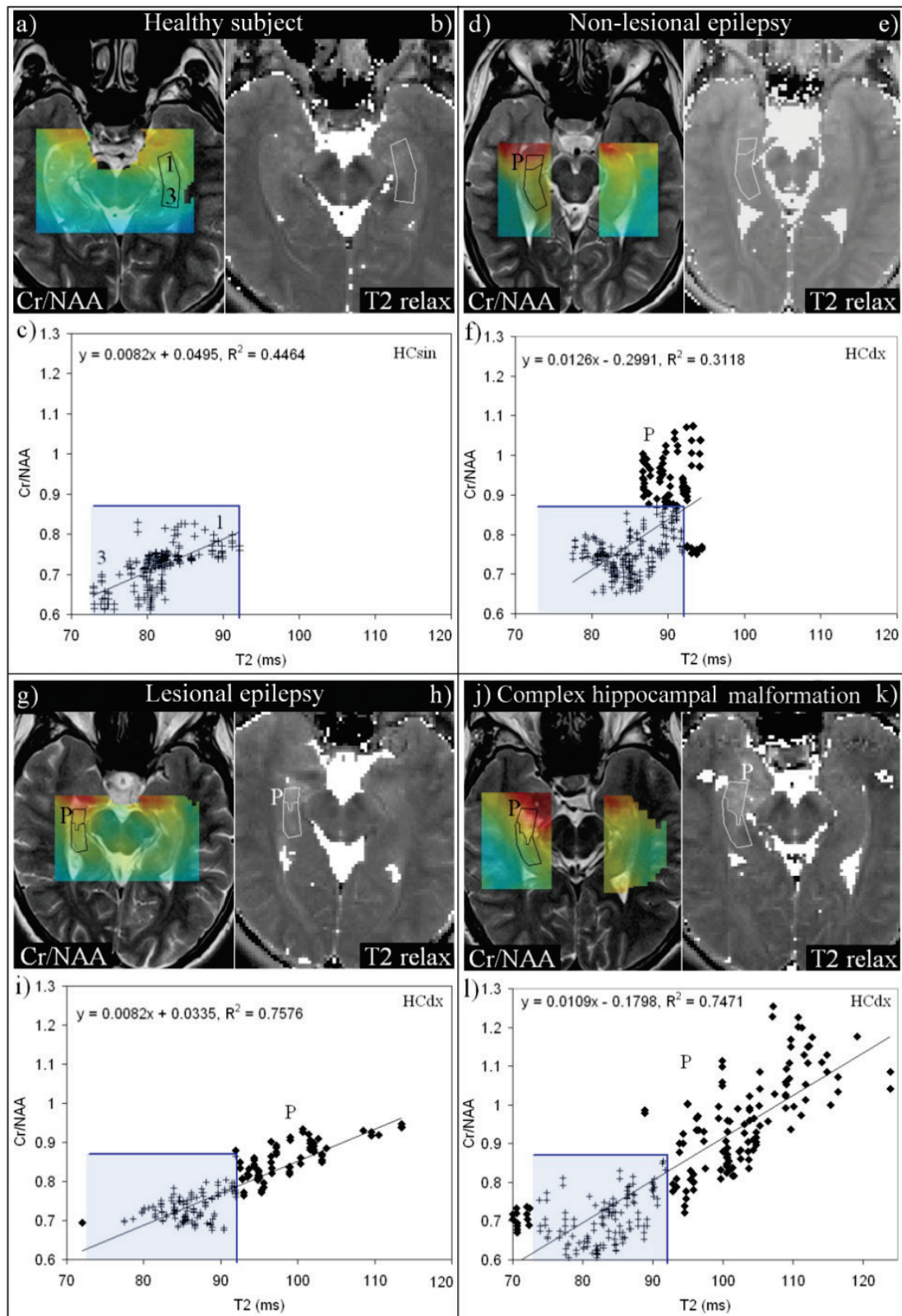


Fig. 1. The Cr/NAA-T2 correlations in hippocampi in a 24 year-old healthy control (**a-c**); in a 19 year-old female patient with non-lesional MTLE (**d-f**); in a 20 year-old male patient with right MTLE with HS (**g-i**); and in a 27 year-old male patient with right MTLE with complex malformation of the hippocampus (**j-l**). **a,d,g,j**: Cr/NAA maps positioned on T2 weighted images with the maximal value of the Cramer-Rao bound of total Cr/NAA ratios set to 15 %; **b,e,h,k**: T2 relaxation maps; **c,f,i,l**: correlation plots; each cross represents an ordered pair of Cr/NAA-T2 values corresponding to one pixel in the analyzed area. The borders of controls are visible in correlation plots as blue lines. All the values outside the control interval visible as diamonds correspond to tissue abnormalities. According to semiautomatic quantitative evaluation, the anterior portion of the right hippocampus in patients showed an abnormal finding whereas the left hippocampus in a healthy control has normal finding. Cr – total creatine, NAA – N-acetyl aspartate + N-acetylaspartylglutamate, T2 relax – T2 relaxation map, HCdx – right hippocampus, HCsin – left hippocampus, P – pathologic tissue.

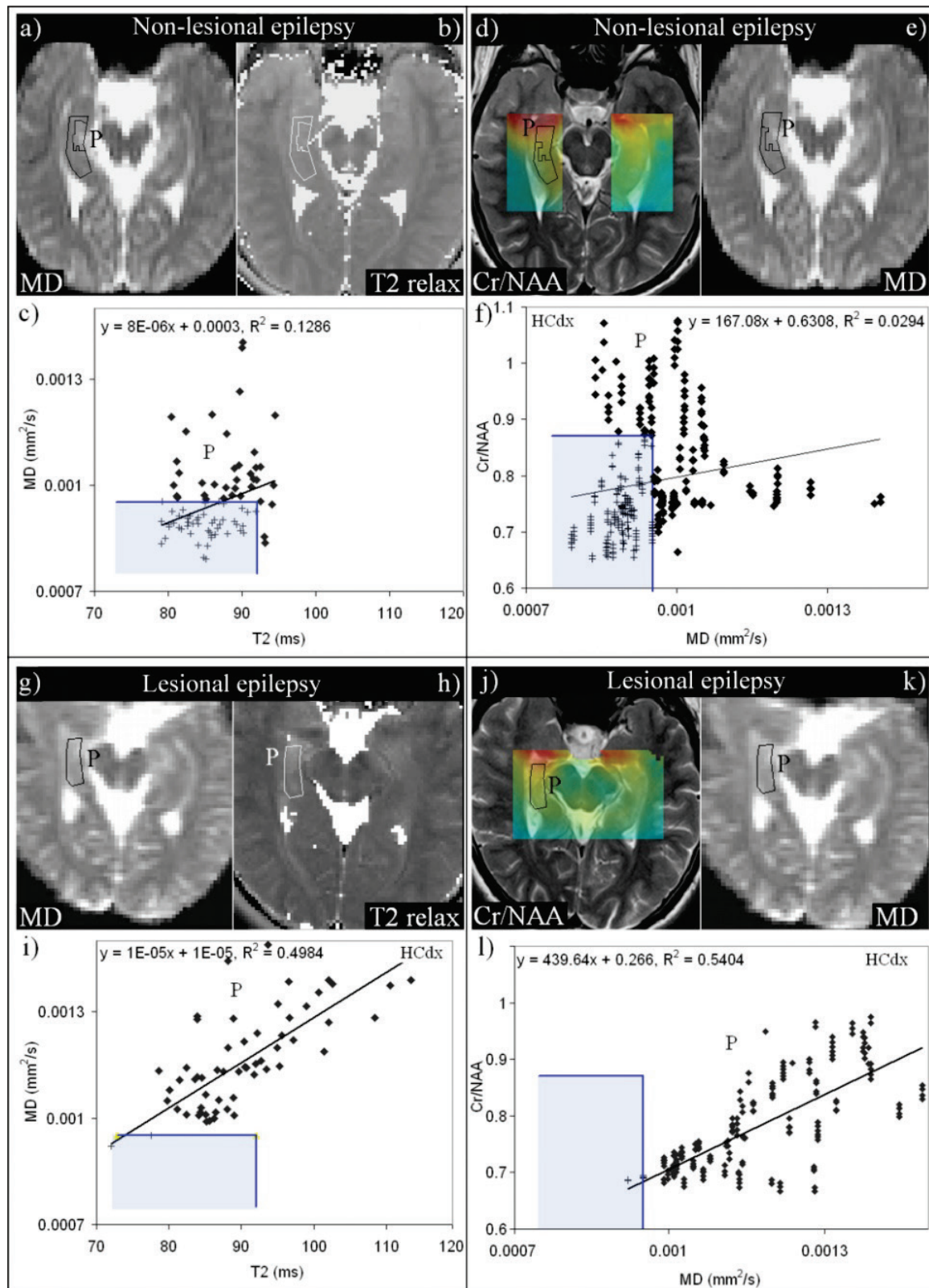


Fig. 2. The MD-T2 and Cr/NAA-MD correlations in the hippocampi in a 19 year-old female patient with right MTLE without HS (**a-f**); 20 year-old male patient with right MTLE with HS (**g-l**). **a,e,g,k**: MD maps; **b,h**: T2 relaxation maps; **d,j**: Cr/NAA maps positioned on T2 weighted images with the maximal value of the Cramer-Rao bound of total Cr/NAA concentrations set to 15 %; **c,f,i,l**: correlation plots in different scaling. Each cross represents an ordered pair of MD-T2 or Cr/NAA-MD values corresponding to one pixel in the analyzed area. The borders of controls data are visible in correlation plots as blue lines. All the values outside the control interval visible as diamonds correspond to tissue abnormalities. According to semiautomatic quantitative evaluation, the anterior portion of the right hippocampus in the patient without HS and entire HC in the patient with HS showed an abnormal finding. Cr – total creatine, NAA – N-acetyl aspartate + N-acetylaspartylglutamate, MD – mean diffusivity, T2 relax – T2 relaxation map, HCdx – right hippocampus, HCsin – left hippocampus, P – pathologic tissue.

Correlations in the HC with abnormal metabolic values are listed in Table 2. In contrast to controls, Cr and T2 (Cr-T2) and Cr and MD (Cr-MD) correlated positively. The other correlations were similar to those in controls. The slopes of Cr/NAA-T2 and Cr-T2 dependence were significantly higher in patients than in the controls ($p < 0.05$). The difference is caused by substantial metabolic changes in patients, as the T2 and MD values are within the control intervals. The examples of correlations between Cr/NAA and T2 (Cr/NAA-T2) are shown in Figure 1f.

MR findings in lesional TLE patients

Electro-clinical diagnosis (Table 1) and MRS-T2 evaluation lateralized EZ identically in all unilateral cases and the predominance in all bilateral cases. The results were confirmed by histopathology. The results of MRS-MD evaluation corresponded to electro-clinical diagnosis in all unilateral cases and the predominance in five out of the seven bilateral cases.

Correlation patterns found in the HC with abnormal values are listed in Table 2. In contrast to controls and patients with non-lesional TLE, Cho/Cr with T2 (or MD) did not significantly correlate. Other correlation patterns were similar to the non-lesional TLE patient group, however they exhibited stronger linear dependence (Table 2). The slopes of the Cr/NAA-T2 and Cr-T2 correlations differed significantly from the controls ($p < 0.05$). Moreover, Cr-T2(MD) and Cho-T2 slopes differed significantly from the non-lesional patients. The examples of Cr/NAA-T2 correlations are shown in Figures 1i, 1l. Although Cr/NAA-T2 correlations exhibited trends of slopes smaller than in non-lesional patients, they did not reach statistical difference ($p = 0.06$).

All patients with lesional TLE exhibited increased T2 values in HC compared to healthy controls (11 patients unilaterally and 1 patient bilaterally). T2 values between 100 ms and 120 ms were found in both HS and hippocampal non-specific gliosis (histopathologically confirmed). Other lesions (ganglioglioma, complex hippocampal malformation associated with focal cortical dysplasia) exhibited even higher T2 (> 120 ms).

Discussion

This work tested a new technique for studying mutual relationships between MR parameters based on a pixel-by-pixel image evaluation in groups of controls

and patients with TLE. It proved that the relationships between metabolic and structural processes in pathologic hippocampus can be studied noninvasively. It brings a new general view of the pathology in an individual patient, which can be used in the assessment of hippocampal involvement or EZ lateralization. Although EZ lateralization based on correlations between the metabolic and T2 relaxation data agreed with electro-clinical diagnosis in all tested cases, data processing is substantially complicated by measurement artifacts discussed below.

Mutual relationships between studied parameters in controls revealed gradual changes in individual parameters in the anteroposterior direction of the hippocampus and provide information about natural spatial distribution of these parameters across the hippocampus. The MD-T2 correlation (although weaker than in patients) reflects different morphology and showed increased extra- and intra-cellular space in the anterior portion compared to the posterior portion of the healthy hippocampus. The higher T2 relaxation times in the anterior HC portion are in accord with the previously reported studies (von Oertzen *et al.* 2002, Briellmann *et al.* 2004, Bartlett *et al.* 2007). We obtained significantly lower absolute values than the previous studies did. Nevertheless, von Oertzen himself mentioned that their method (dual-echo TSE sequence) resulted in higher T2 values than those measured with conventional relaxometry. We should also note that MD and T2 do not represent completely independent parameters as the diffusion measurements are weighted by relaxations and vice versa.

Different metabolic concentrations found in anteroposterior direction are also in agreement with previously reported studies performed at 1.5T (Chu *et al.* 2000, Vermathen *et al.* 2000). Unfortunately, we cannot distinguish the contribution of chemical shift artifact (CSA) and hippocampal morphology (i.e. tissue changes in anteroposterior direction) to the correlations found in healthy controls. Although CSA may be negligible at 1.5T, it represents a significant contribution to correlations at 3T. Chu proposed a method for EZ lateralization using spectroscopy and tissue segmentation based on T1 values at 1.5T; however, we did not measure T1 maps and we found out that T2 maps were not suitable at 3T due to substantial T2 changes in the lesions. Nevertheless, although CSA represents a possible systematic error, both control and patients' data are affected in the same direction. Therefore, in mutual

comparisons, CSA has no relevant effect on the final results.

The pixel-by-pixel image analysis evaluates all the measured parameters in a complex way. Highlighted pixels with MR parameters out of the control interval clearly determine the pathology extent which is convenient for routine discrimination of the hippocampal abnormality. However, it seems that analysis of the correlation patterns and their slopes provides more detailed information about the significance of metabolic and structural changes in the pathologic tissue. Higher slopes in case of the positive correlations indicate severe metabolic abnormalities, while lower slopes severe structural changes. The changes of the slopes describe the tissue state and may assist in better presurgical planning especially in patients with negative MRI findings. Our findings are in accordance with previously reported results at 1.5T (Namer *et al.* 1999, Pereira *et al.* 2006) showing that the combination of different methods (i.e. MRI, 1H-MRS, T2 relaxometry and diffusometry) provides clinically relevant information additional to standard clinical assessment.

All measured correlations showed higher slopes in non-lesional TLE than in lesional epilepsy (Table 2), although not all differences are significant. Only Cr-T2 correlation slope of linear regression differs significantly between all subject groups. It indicates that reactive astrogliosis (represented by increased Cr) and an increase of glial cell volume (increase of T2 values) are key factors in a hippocampal state characterization.

The correlation findings in non-lesional patients demonstrate no changes in the extra- and intra-cellular space (unchanged T2 and MD) but show neuronal dysfunction (decreased NAA) and reactive astrogliosis in the anterior portion of hippocampus. Biological barriers reducing ability of water diffusion therefore work properly and the tissue architecture is normally organized, without increased amount of glial cells (they have larger proportion of intracellular freely moving water – Pereira *et al.* 2006). These statements are in accordance with negative MRI findings in all these patients and with histopathological results in two patients who underwent surgery.

Patients with lesional TLE showed distinctive extra- and intra-cellular changes in the anterior portion of HC together with mild metabolic changes resulting in small slopes in positive linear correlations and high in negative ones. Therefore, distinctive neuronal loss or dysfunction and reactive astrogliosis are accompanied by

characteristic architectural disorganization of the damaged tissue. Strong MD-T2 correlation further indicates that increased water mobility reflecting disrupted biological barriers and increased intracellular water movement resulting from increased amount of glial cells are associated processes. These findings were in accordance with histopathological results which showed hippocampal sclerosis (gliosis) or hippocampal non-specific gliosis in the examined tissues. However, as both HS and HC non-specific gliosis exhibit increased T2, these two pathologies cannot be distinguished by correlation methods.

Linear regression fitted well correlations in controls and in patients with lesional epilepsy. In contrast, positive correlations in non-lesional patients seem to be non-linear or contain two components (Fig. 1f). We believe that it is a consequence of an inclusion of both healthy and pathological tissue into the examined region. Both tissues have normal architecture (negative MRI, normal MD and T2), but different metabolism represented by increased Cr and decreased NAA in patients.

The proposed correlation method may be sensitive to age as the pathologic tissue is automatically detected according to data from the control group. MR parameters change significantly in small children during brain maturation (Kreis *et al.* 1993, Pouwels *et al.* 1999) and in elderly people due to demyelination and degradation processes. In these cases, age matched subjects should be used in control database to avoid underestimation or overestimation of the pathology extent. Nevertheless, MR parameters in adolescents and adults are supposed to be stable and the use of one control group is sufficient.

The correlations of metabolic values with relaxation times were found to be the best markers for assessment of hippocampal involvement. The semiautomatic evaluation of correlations of other parameters with MD failed due to distortions in diffusion images leading to the increased MD values in the vicinity of the brain stem. Increased image distortions in the image plane containing both temporal and frontal regions are caused by an inherent sensitivity of echo planar imaging sequences to inhomogeneities of the static magnetic field. It could be corrected during images post-processing using an additional B0 map.

In our study, the metabolite concentrations were corrected neither for relaxation times nor for cerebrospinal fluid volume because it was unnecessary

for the proposed method and the exact absolute concentrations were not the stated aim of the study. Nevertheless, lack of these corrections has no effect on metabolic ratios.

Single voxel spectroscopy over the larger volume of the hippocampus may be sufficient for basic lateralization (Kuzniecky 1999, Hajek *et al.* 2008). However, the existence of correlation requires comparison of the patients' data and controls in the same portion of HC (Vermathen *et al.* 2000), as the values of metabolite concentration, T2 and MD gradually change in the anteroposterior direction. Averaging of the values over the whole hippocampus leads to a substantial data dispersion related to physiological properties of the tissue.

The CORIMA program reciprocally highlights pixels corresponding to control data using thresholds determined as the mean values \pm standard deviations. Therefore even in the healthy region may occur values exceeding the control interval of a corresponding MR parameter. This can be observed in Figures 1i, 1l (the pixels with very low T2 parameters). These values did not exceed the control interval by more than 5 % in T2 values and metabolic concentrations; however, MD values in the vicinity of the brain stem may exceed the MAX value by more than 20 %. Inclusion or exclusion of high MD values in the vicinity of the brain stem from the volunteers' statistics strongly affects the control interval and therefore may underestimate or overestimate the

pathology extent in patients (Fig. 2). The analysis alongside the diffusion distortions may lead to the failure of the MRS-MD assessment. Therefore, this method should be used only as semiautomatic with the supervision of an operator.

In conclusion, description of an extent and character of hippocampal pathology in patients with TLE can be substantially improved by a detailed analysis of multiple MR parameters. Evaluation of correlation patterns of the quantitative parameters along the anteroposterior direction of the hippocampus represents a suitable approach. The slopes of Cr/NAA-T2 and Cr-T2 correlations differed significantly between patients and controls and are the best biomarkers of the epileptogenic foci. The proposed method based on a pixel-by-pixel evaluation of MR images may supplement appropriately a standard clinical protocol. However, the automated processing should be carefully monitored in order to avoid errors caused by possible MR artifacts.

Conflict of Interest

There is no conflict of interest.

Acknowledgements

The study was supported by the following grant projects: IGA MZCR NS 9915-4/2008, MH CZ – DRO („Institute for Clinical and Experimental Medicine – IKEM, IN 00023001“), MH CZ – DRO („University Hospital Motol, Prague, Czech Republic 00064203“).

References

- BARTLETT PA, SYMMS MR, FREE SL, DUNCAN JS: T2 relaxometry of the hippocampus at 3T. *AJNR Am J Neuroradiol* **28**: 1095-1098, 2007.
- BONILHA L, EDWARDS JC, KINSMAN SL, MORGAN PS, FRIDRIKSSON J, RORDEN CH, RUMBOLDT Z, ROBERTS DR, ECKERT MA, HALFORD JJ: Extrahippocampal gray matter loss and hippocampal deafferentation in patients with temporal lobe epilepsy. *Epilepsia* **51**: 519-528, 2010.
- BRIELLMANN RS, SYNGENIOTIS A, FLEMING S, KALNINS RM, ABBOTT DF, JACKSON GD: Increased anterior temporal lobe T2 times in cases of hippocampal sclerosis: a multi-echo T2 relaxometry study at 3 T. *AJNR Am J Neuroradiol* **25**: 389-394, 2004.
- CHU WJ, KUZNIECKY RI, HUGG JW, ABOU-KHALIL B, GILLIAM F, FAUGHT E, HETHERINGTON HP: Statistically driven identification of focal metabolic abnormalities in temporal lobe epilepsy with corrections for tissue heterogeneity using 1H spectroscopic imaging. *Magn Reson Med* **43**: 359-367, 2000.
- CONCHA L, BEAULIEU C, COLLINS DL, GROSS DW: White-matter diffusion abnormalities in temporal-lobe epilepsy with and without mesial temporal sclerosis. *J Neurol Neurosurg Psychiatry* **80**: 312-319, 2009.
- DUZEL E, KAUFMANN J, GUDERIAN S, SZENTKUTI A, SCHOTT B, BODAMMER N, HOPF M, KANOWSKI M, TEMPELMANN C, HEINZE HJ: Measures of hippocampal volumes, diffusion and 1H MRS metabolic abnormalities in temporal lobe epilepsy provide partially complementary information. *Eur J Neurol* **11**: 195-205, 2004.

- ENGEL J JR: Introduction to temporal lobe epilepsy. *Epilepsy Res* **26**: 141-150, 1996.
- FSL [computer program]. Available via <http://www.fmrib.ox.ac.uk/fsl/>
- HAJEK M, DEZORTOVA M, KRSEK P: 1H MR spectroscopy in epilepsy. *Eur J Radiol* **67**: 258-267, 2008.
- HERYNEK V, WAGNEROVA D, HEJLOVA I, DEZORTOVA M, HAJEK M: Changes in the brain during long-term follow-up after liver transplantation. *J Magn Reson Imaging* **35**: 1332-1337, 2012.
- JACK CR: Hippocampal T2 relaxometry in epilepsy: past, present, and future. *AJNR Am J Neuroradiol* **17**: 1811-1914, 1996.
- JIRU F, SKOCH A, KLOSE U, GRODD W, HAJEK M: Error images for spectroscopic imaging by LCModel using Cramer-Rao bounds. *Magn Reson Mater Phy* **19**: 1-14, 2006.
- JIRU F, SKOCH A, WAGNEROVA D, DEZORTOVA M, HAJEK M: jSIPRO - analysis tool for magnetic resonance spectroscopic imaging. *Comput Methods Programs Biomed* **112**: 173-188, 2013.
- KANTARCI K, SHIN C, BRITTON JW, SO EL, CASCINO GD, JACK CR JR: Comparative diagnostic utility of 1H MRS and DWI in evaluation of temporal lobe epilepsy. *Neurology* **58**: 1745-1753, 2002.
- KELLER SS, ROBERTS N: Voxel-based morphometry of temporal lobe epilepsy: an introduction and review of the literature. *Epilepsia* **49**: 741-757, 2008.
- KNAKE S, SALAT DH, HALGREN E, HALKO MA, GREVE DN, GRANT PE: Changes in the white matter microstructure in patients with TLE and hippocampal sclerosis. *Epileptic Disord* **11**: 244-250, 2009.
- KREIS R, ERNST T, ROSS BD: Development of the human brain: in vivo quantification of metabolite and water content with proton magnetic resonance spectroscopy. *Magn Reson Med* **30**: 424-437, 1993.
- KUZNIECKY R: Magnetic resonance spectroscopy in focal epilepsy: 31P and 1H spectroscopy. *Rev Neurol* **155**: 495-498, 1999.
- KUZNIECKY R, PALMER CH, HUGG J, MARTIN R, SAWRIE S, MORAWETZ R, FAUGHT E, KNOWLTON R: Magnetic resonance spectroscopic imaging in temporal lobe epilepsy: Neuronal dysfunction or cell loss? *Arch Neurol* **58**: 2048-2053, 2001.
- MARGERISON JH, CORSELLIS JAN: Epilepsy and the temporal lobe. A clinical, electroencephalographic and neuropathological study of the brain in epilepsy, with particular reference to the temporal lobes. *Brain* **89**: 499-530, 1966.
- NAMER IJ, BOLO NR, SELLAL F, NGUYEN VH, NEDELEC JF, HIRSCH E, MARESCAUX C: Combined measurements of hippocampal N-acetyl-aspartate and T2 relaxation times in the evaluation of mesial temporal lobe epilepsy: correlation with clinical severity and memory performances. *Epilepsia* **40**: 1424-1432, 1999.
- PALMINI A, NAJM I, AVANZINI G, BABB T, GUERRINI R, FOLDVARY-SCHAEFER N, JACKSON G, LUDERS HO, PRAYSON R, SPREAFICO R, VINTERS HV: Terminology and classification of the cortical dysplasias. *Neurology* **62**: S2-S8, 2004.
- PEREIRA PMG, OLIVEIRA E, ROSADO P: Apparent diffusion coefficient mapping of the hippocampus and the amygdala in pharmacoresistant temporal lobe epilepsy. *AJNR Am J Neuroradiol* **27**: 671-683, 2006.
- POUWELS PJW, BROCKMANN K, KRUSE B, WILKEN B, WICK M, HANEFELD F, FRAHM J: Regional age dependence of human brain metabolites from infancy to adulthood as detected by quantitative localized proton MRS. *Pediatr Res* **46**: 474-485, 1999.
- PROVENCHER SW: Estimation of metabolite concentrations from localized in vivo proton NMR spectra. *Magn Reson Med* **30**: 672-679, 1993.
- VERMATHEN P, LAXER KD, MATSON GB, WEINER MW: Hippocampal structures: anteroposterior N-acetylaspartate differences in patients with epilepsy and control subjects as shown with proton MR spectroscopic imaging. *Radiology* **214**: 403-410, 2000.
- VON OERTZEN J, URBACH H, BLUMCKE I, REUBER M, TRABER F, PEVELING T, MENZEL C, ELGER CE: Time-efficient T2 relaxometry of the entire hippocampus is feasible in temporal lobe epilepsy. *Neurology* **58**: 257-264, 2002.
- WAGNEROVA D, JIRU F, DEZORTOVA M, VARGOVA L, SYKOVA E, HAJEK M: The correlation between 1H MRS choline concentrations and MR diffusion trace values in human brain tumours. *Magn Reson Mater Phy* **22**: 19-31, 2009.