

Disparity Between Two-Dimensional Echocardiographic and Electroanatomic Left and Right Atrial Volumes in Patients Undergoing Catheter Ablation for Long-Standing Persistent Atrial Fibrillation

L. ŠKŇOUŘIL¹, Š. HAVRÁNEK², V. BULKOVÁ², M. DORDA¹, T. PALEČEK², J. ŠIMEK², Z. FINGROVÁ², A. LINHART², J. JANUŠKA¹, D. WICHTERLE^{2,3}, M. FIALA^{1,4}

¹Department of Cardiology, Hospital Podlesí, Třinec, Czech Republic, ²Second Department of Medicine, Department of Cardiovascular Medicine, First Faculty of Medicine, Charles University and General University Hospital, Prague, Czech Republic, ³Department of Cardiology, Institute for Clinical and Experimental Medicine, Prague, Czech Republic, ⁴Department of Medicine and Cardiology, University Hospital, Masaryk University, Brno, Czech Republic

Received February 3, 2016

Accepted August 5, 2016

On-line December 16, 2016

Summary

Left atrial (LA) volume (LAV) is used for the selection of patients with atrial fibrillation (AF) to rhythm control strategies. Calculation of LAV from the LA diameters and areas by two-dimensional (2D) echocardiography may result in significant error. Accuracy of atrial volume assessment has never been studied in patients with long-standing persistent AF (LSPAF) and significant atrial remodeling. This study investigated correlation and agreement between 2D echocardiographic (Simpson method) and electroanatomic (CARTO, Biosense Webster) left and right atrial (RA) volumes (LAV_{ECHO} vs. LAV_{CARTO} and RAV_{ECHO} vs. RAV_{CARTO}) in patients undergoing catheter ablation for LSPAF. The study enrolled 173 consecutive subjects (females: 21 %, age: 59±9 years). There was only modest correlation between LAV_{ECHO} (92±31 ml) and LAV_{CARTO} (178±37 ml) (R=0.57), and RAV_{ECHO} (71±29 ml) and RAV_{CARTO} (173±34 ml) (R=0.42), respectively. LAV_{ECHO} and RAV_{ECHO} underestimated LAV_{CARTO} and RAV_{CARTO} with the absolute bias (±1.96 standard deviation) of -85 (-148; -22) ml and -102 (-169; -35) ml, respectively, and with the relative bias of -48 (-75; -21) % and -59 (-88; -30) %, respectively (all P<0.000001 for their mutual difference). Significant confounders of this difference were not identified. In patients with LSPAF, 2D echocardiography significantly underestimated both LA and RA volumes as compared with electroanatomic reference. This disagreement was independent of clinical, echocardiographic and mapping characteristics.

Key words

Long-standing atrial fibrillation • Echocardiography • Atrial volume • Electroanatomic mapping

Corresponding author

M. Fiala, Department of Internal Medicine and Cardiology, University Hospital Brno, Jihlavská 53, Brno, 659 91, Czech Republic. Fax: +420532232162. E-mail: martin.fiala@gmail.com

Introduction

Atrial fibrillation (AF) is frequently associated with left atrial (LA) enlargement which is also an acknowledged marker of resistance to pharmacological and non-pharmacological treatment of AF (Berruezo *et al.* 2007, Hof *et al.* 2009b, Montefusco *et al.* 2010, Von Bary *et al.* 2012, Zhuang *et al.* 2012). Although LA antero-posterior diameter in long-axis parasternal (PLAX) view has been largely used as a simple index of the LA size, its correlation with the LA volume (LAV) was poor in multiple prior studies (Lester *et al.* 1999, Pritchett *et al.* 2003, Badano *et al.* 2008, Hof *et al.* 2009a). Three-dimensional (3D) echocardiography, computed tomography (CT) or magnetic resonance (MR) imaging are not commonly used in routine clinical practice for more accurate

assessment of LAV (Russo *et al.* 2010, Miyasaka *et al.* 2011, Mor-Avi *et al.* 2012, Shimada and Shiota 2012, Koka *et al.* 2012, Patel *et al.* 2003, Müller *et al.* 2010, Vandenberg *et al.* 1995, Rodevan *et al.* 1999, Maceira *et al.* 2010, Abhayaratna *et al.* 2006, Lang *et al.* 2005, Havranek *et al.* 2016). On the other hand, routinely employed automated algorithms for calculation of LAV from the LA diameters and areas by two-dimensional (2D) echocardiography may result in significant error.

Electroanatomic mapping in patients undergoing catheter ablation for AF offers an alternative tool of 3D atrial reconstruction and volume assessment independent of geometric assumptions (Patel *et al.* 2003, Müller *et al.* 2010). The LAV derived from electroanatomic mapping (LAV_{CARTO}) poorly corresponded with 2D-echocardiographic LAV (LAV_{ECHO}) in patients ablated for predominantly paroxysmal AF in prior studies (Patel *et al.* 2003, Havranek *et al.* 2016). However, no prior study compared LAV_{CARTO} and LAV_{ECHO} in the subjects with long-standing persistent AF (LSPAF), the most difficult-to-ablate AF type because of extensive LA remodeling. In addition, although arrhythmogenic substrate of LSPAF involves RA in up to 30 % of cases (Rostock *et al.* 2008, Narayan *et al.* 2012, Haissaguerre *et al.* 2014), RA is not routinely mapped during AF ablation and correspondence between 2D echocardiographic and electroanatomic RA volumes (RAV_{ECHO} and RAV_{CARTO}) is generally unknown.

This study aimed at investigating the relationship between the 2D echocardiographic LAV_{ECHO} and RAV_{ECHO} calculated by the Simpson method and the LAV_{CARTO} and RAV_{CARTO} derived from 3D electroanatomic mapping in patients undergoing catheter ablation for LSPAF.

Methods

Study population

The study included 173 consecutive patients who underwent their first ablation for LSPAF between August 2007 and December 2011 and met the following criteria: 1) age 18-80 years; 2) symptomatic LSPAF lasting >12 months without intervening sinus rhythm; 3) refractory to oral amiodarone; 4) resistant to electrical cardioversion or recurring within 7 days after. Ethical approval was obtained for the study protocol, and all patients gave written informed consent.

Electroanatomic mapping

Electroanatomic LA and RA maps (CARTO, Biosense Webster, Diamond Bar, CA, USA) were acquired during AF by mapping/ablation catheter with a 3.5-mm irrigated-tip electrode (NaviStar ThermoCool, Biosense Webster, Diamond Bar, CA, USA). The maps were based on 3D virtual LA/RA shells reconstructed by software interpolations over the co-ordinates of multiple endocardial points. Efforts were made to obtain high-density maps consisting of evenly distributed contact points. Transition of the tubular segment of pulmonary vein (PV) into the PV antrum was identified by combined information obtained from fluoroscopy, recording of PV and LA potentials, and impedance drop. Intracardiac echocardiography assisted in visualization of critical atrial structures in a majority of cases. The LAV_{CARTO} and RAV_{CARTO} were automatically derived from 3D electroanatomic maps that comprised broader PV antra and entire appendages. The CT image was registered in the electroanatomic map by an automated algorithm that minimizes the distance between mapping points and the CT surface. The match between both merged maps was optimized by eliminating inner and outer electroanatomic points due to inadequate contact or excessive pressure against the atrial wall as well as respiration-related shifts. LAV_{CARTO} and RAV_{CARTO} were automatically provided by a built-in computation function of the Biosense system. In addition to volume assessment, the proportions of mapping points arbitrarily divided into 3 groups exhibiting voltage <0.2 mV (severe interstitial fibrosis), 0.2-1.0 mV, and >1 mV (normal atrial myocardium) were obtained as described previously (Fiala *et al.* 2010).

Echocardiographic examination

Transthoracic echocardiography using an echocardiograph iE 33 (Phillips, Bothell, WA, USA) were completed by 3 experienced physicians prior to the ablation according to the guidelines (Pritchett *et al.* 2003, Abhayaratna *et al.* 2006, Lang *et al.* 2005). Left ventricular diameters were measured in PLAX view using M-mode when possible, or 2D echocardiography if more accurate. Antero-posterior LA diameter in PLAX view, and LA and RA long- and short-axis diameters in apical four-chamber (A4CH) and apical two chamber (A2CH) views were measured as the maximum end-systolic linear dimensions not including venous ostia or appendages. Atrial volumes were automatically obtained by biplane (A2CH and A4CH) and single-plane (A4CH) modified Simpson method for LAV_{ECHO} and RAV_{ECHO}, respectively (Lang *et al.* 2005).

Statistical analysis

Continuous variables were expressed as a mean with standard deviation and compared by 2-tailed t-test for independent samples. Categorical variables were expressed as a percentage and compared by χ^2 -test. Pearson's correlation and multivariate linear regression were used to analyze the relationship between LAV_{ECHO} and RAV_{ECHO} together with other clinical covariates as independent variables and LAV_{CARTO} and RAV_{CARTO} as dependent variable. Stepwise forward method was used for all variables with univariate relationship of $P \leq 0.20$. The agreement between atrial volumes was analyzed using the modified method of Bland-Altman assuming that LAV_{CARTO} and RAV_{CARTO} are substantially more accurate than LAV_{ECHO} and RAV_{ECHO}. P-value < 0.05 was considered significant. All analyses were performed using the STATISTICA vers.12 software (Statsoft, Inc., Tulsa, USA).

Results

Baseline characteristics of the study population are shown in Table 1. Pre-ablation LAV_{ECHO} and LAV_{CARTO} were compared in all 173 patients; comparison of RAV_{ECHO} and RAV_{CARTO} was available in 169 patients. Echocardiographic and electroanatomic mapping parameters are summarized in Tables 2 and 3. The distribution of LAV_{ECHO} (92±31 ml) / RAV_{ECHO} (71±29 ml) and LAV_{CARTO} (178±37 ml) / RAV_{CARTO} (173±34 ml) is shown in Figure 1.

There was only modest correlation between LAV_{ECHO} and LAV_{CARTO} ($R=0.57$), and RAV_{ECHO} and RAV_{CARTO} ($R=0.42$), respectively ($P < 0.0001$ for both coefficients) (Fig. 2). LAV_{ECHO} and RAV_{ECHO} underestimated LAV_{CARTO} and RAV_{CARTO} with the absolute bias (± 1.96 standard deviation) of -85 (-148; -22) ml and -102 (-169; -35) ml, respectively, and with the relative bias of -48 (-75; -21) % and -59 (-88; -30) %, respectively (all $P < 0.000001$ for their mutual difference) (Fig. 3). The proportions of patients exhibiting difference between echocardiographic and electroanatomic LAV and RAV that exceeded predefined level of error are shown in Table 4. No significant and independent covariates of the difference between LAV_{ECHO} and LAV_{CARTO} and between RAV_{ECHO} and RAV_{CARTO} were identified by multivariate regression analysis.

Discussion

This study demonstrated that the LAV derived from electroanatomic endocardial map was

approximately twofold larger than that assessed by the 2D echocardiographic Simpson method and, importantly, that the limits of agreement were considerably wide. Such disagreement was for the first time shown in patients with intractable LSPAF and significant left atrial enlargement. This is also the first study that revealed similarly poor correspondence between electroanatomic and echocardiographic RAV.

Table 1. Baseline characteristics.

Age (years)	59±9 (32-79)
Females	37 (21 %)
Total AF history (months)	median 60, IQR 31-93 (13-504)
Persistent AF duration (months)	median 26, IQR 17-48 (13-254)
Arterial hypertension	107 (62 %)
Diabetes mellitus	20 (12 %)
Stroke/TIA	22 (13 %)
Coronary artery disease	13 (8 %)
Pulmonary disease	21 (12 %)
History of heart failure	34 (19 %)
LVEF ≤ 40 % before ablation	28 (16 %)
Hypothyroidism	13 (8 %)
CHADS ₂	1.2±1.0 (0-4)
CHA ₂ DS ₂ VASC	1.7±1.4 (0-6)
Body mass index (kg/m ²)	31±4 (19-44)
LV end-diastolic diameter (mm)	52±7 (37-79)
LV end-systolic diameter (mm)	37±8 (21-67)
LVEF (%)	median 58, IQR 51-60 (25-67)

Data shown as mean \pm standard deviation (range) or median with interquartile range (IQR) (range) or count (percentage). AF – atrial fibrillation, LV – left ventricular, LVEF – left ventricular ejection fraction, TIA – transitory ischemic attack.

Table 2. Left and right atrial echocardiographic parameters.

LA antero-posterior diameter (mm)	48±5
LA long-axis diameter (mm)	68±6
LA short axis diameter (mm)	47±6
RA long-axis diameter (mm)	61±6
RA short axis diameter (mm)	44±8
LAV _{ECHO} (ml)	92±31
RAV _{ECHO} (ml)	71±29

Data shown as mean \pm standard deviation (range). LA – left atrial, RA – right atrial, LAV_{ECHO}, RAV_{ECHO} – left and right atrial volumes assessed by 2D echocardiography (Simpson method).

Table 3. Left and right atrial electroanatomic mapping parameters.

<i>LA mapping points</i>	222±39
<i>RA mapping points</i>	177±29
<i>LA points <0.2 mV (%)</i>	24±18
<i>LA points >1.0 mV (%)</i>	19±11
<i>RA points <0.2 mV (%)</i>	17±11
<i>RA points >1.0 mV (%)</i>	35±16
<i>LA maximum voltage (mV)</i>	5.5±2.4
<i>RA maximum voltage (mV)</i>	6.2±2.5
<i>LAV_{CARTO} (ml)</i>	178±37
<i>RAV_{CARTO} (ml)</i>	173±34

Data shown as mean ± standard deviation (range). LA – left atrial, RA – right atrial, LAV_{CARTO}, RAV_{CARTO} – left and right atrial volumes derived from electroanatomic mapping.

Table 4. Proportions of subjects with relative deviation of echocardiographic from electroanatomic atrial volume.

	LAV _{ECHO} vs. LAV _{CARTO}	RAV _{ECHO} vs. RAV _{CARTO}
<i>Magnitude of error >10 %</i>	99 %	97 %
<i>Magnitude of error >20 %</i>	95 %	97 %
<i>Magnitude of error >30 %</i>	92 %	93 %
<i>Magnitude of error >50 %</i>	46 %	73 %

Results are shown for 4 categories defined by lower limit of error. LAV_{ECHO}, RAV_{ECHO} – left and right atrial volumes automatically assessed by 2D echocardiography (Simpson method), LAV_{CARTO}, RAV_{CARTO} – left and right atrial volumes assessed by electroanatomic mapping.

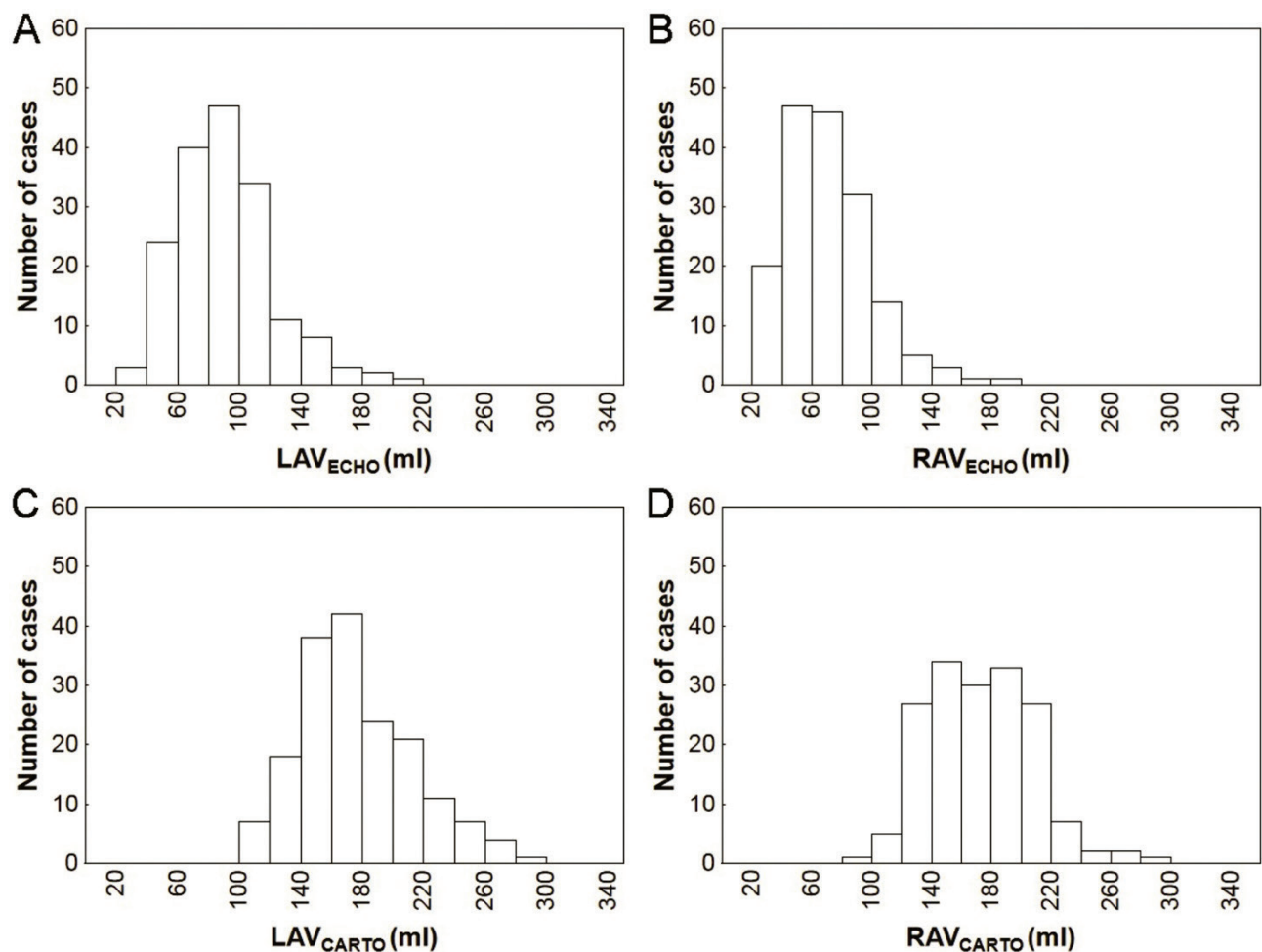


Fig. 1. Distribution of left and right atrial volumes. LAV_{ECHO}, RAV_{ECHO} – left and right atrial volume assessed by 2D echocardiography (Simpson method), LAV_{CARTO}, RAV_{CARTO} – left and right atrial volumes derived from electroanatomic mapping.

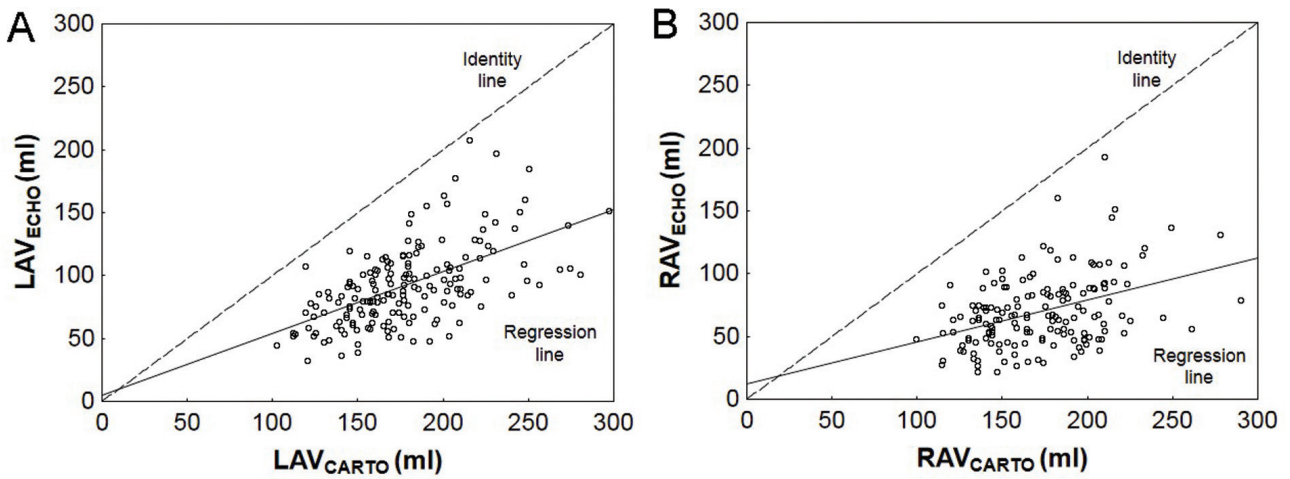


Fig. 2. Pearson's correlation between two-dimensional echocardiographic and electroanatomic volumes. Correlation of left atrial volumes (A) and right atrial volumes (B). Abbreviations as in Figure 1.

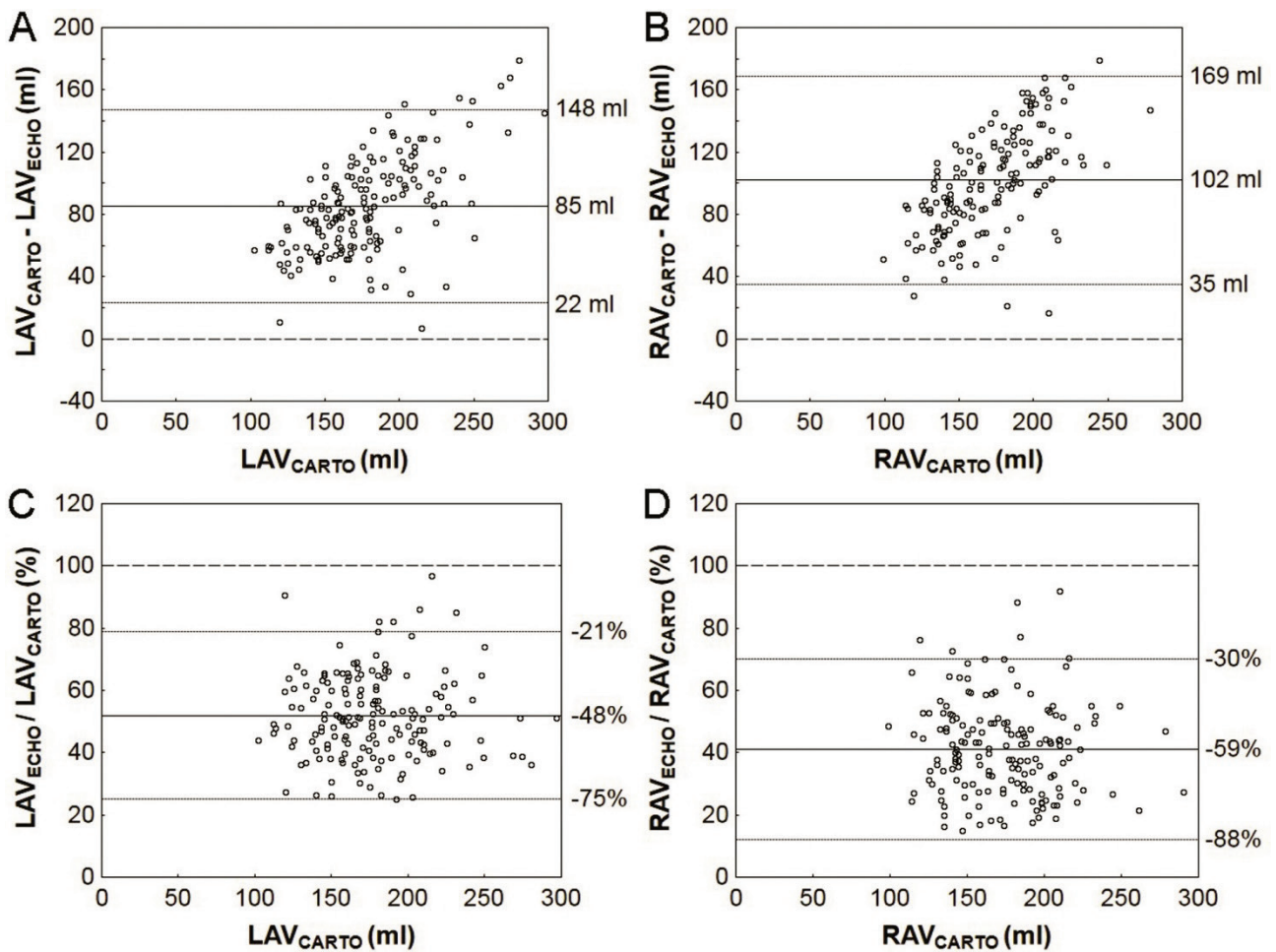


Fig. 3. Agreement between two-dimensional echocardiographic and electroanatomic atrial volumes. Scatterplots for absolute (A and B) and relative (C and D) differences between left atrial (A and C) and right atrial (B and D) volumes obtained by 2D echocardiography and electroanatomic mapping. Dashed line – identity line, solid line – bias, dotted line – limits of agreement (± 1.96 standard deviation). Abbreviations as in Figure 1.

The present study corroborated previously reported systematic underestimation (by ~30 %) of LAV assessed by 2D echocardiography when compared with the assessment by CT or MR (Koka *et al.* 2012, Rodevan *et al.* 1999). LAV obtained by echocardiographic biplane Simpson method was also lower by 20-30 % when compared with electroanatomic LAV; this study reported excellent correlation ($r=0.9$) between electroanatomic and echocardiographic LAV; however, it included a relatively small number of patients with only paroxysmal AF (Patel *et al.* 2003). Our concurrent analysis of a larger population with all AF types showed an increasing scatter of differences between LAV_{ECHO} and LAV_{CARTO} as well as trend to greater both absolute and relative underestimation of true LA size in patients with excessive LA enlargement (Havranek *et al.* 2016).

Electroanatomic instead of CT atrial volumes were used in our study. We are convinced that they can be used promiscuously because excellent match between high-density electroanatomic map and CT image can be invariantly achieved during AF ablation procedures. This is supported by prior study which showed that electroanatomic reconstruction could display true LA 3D anatomy as defined by the CT with high accuracy in most of the LA regions (Piorkowski *et al.* 2006). Recently, the LAV derived from electroanatomic mapping correlated and agreed well with the LAV calculated by MR (Rabbat *et al.* 2015).

Inaccuracy of LAV/RAV_{ECHO} may be influenced by availability of suitable echocardiographic window, observer-dependent adjustment of angulation and gain for endocardial contour visualization, and correct timing of measurement at the end of ventricular systole (Lester *et al.* 1999, Ujino *et al.* 2006). The image quality and anatomically correct projection are frequently competing factors, so that the planes may not be aligned to geometric centre of the chamber in order to achieve maximum cross-sectional area, and biplane assessments may not be strictly orthogonal. Thus, the disparity between the methods might results from: i) failure of simple geometric assumptions applied by 2D echocardiography to assess adequately the true volume of complex atrial shape (Cozma *et al.* 2007) and/or ii) failure to acquire the proper images for biplane assessment in terms of orthogonality and nice endocardial contour. Although the Simpson method is less dependent on simple geometric assumption (like, for example, prolate ellipsoid method), we believe that both are important sources of error. One can easily imagine that

non-spherical structure is prone to either overestimation or underestimation, while more spherical structure is prone to underestimation only. Therefore, bidirectional deviations are mutually cancelled in small, non-spherical atria in patients with paroxysmal AF while unidirectional deviations aggregate in significantly remodeled and more spherically shaped atria in patients with LSPAF. Besides spherical remodeling of the LA (Bisbal *et al.* 2013), other factors may also play a role: enlargement of the funnel-shaped PV antra (Tsao *et al.* 2001), LA roof reshaping (Kurotobi *et al.* 2011), and dilation of the anterior LA including the LA appendage (Nedios *et al.* 2011).

The results of our study are clearly biased by the volume of LA appendage that was mapped, i.e. included into the LAV_{CARTO}. Biplane 2D echocardiography does not display LA appendage that was, therefore, principally excluded from the LAV_{ECHO} calculation. LA appendage volume ranges between 10-30 ml according to different studies, so that the sizeable difference between LAV_{CARTO} and LAV_{ECHO} in our study would hardly have been eliminated if electroanatomic maps had been edited in this respect.

Importantly, there is also bias in the opposite direction that relates to the timing of LAV/RAV assessment. While echocardiographic readings are performed at the end-systolic maximum of atrial volume, the electroanatomic mapping is triggered by the QRS complexes, i.e. points are acquired at the end-diastolic phase when atrial volume is consistently lower by approximately 20-30 ml, which may offset the bias related to the LA appendage (see above).

The difference between LAV_{CARTO} and LAV_{ECHO} was substantially greater than in prior studies and we were not able to find any clinical or morphological variables responsible for this disagreement as in our previous study (Havranek *et al.* 2016). However, this study investigated a significantly larger and more heterogeneous population of AF patients and consequently was more powered to identify individual confounders.

Limitations

Because of retrospective nature of our investigation, the study has several limitations:

Readings of CT-derived atrial volumes were not available. We have no centre-specific data on within- and inter-examiner reproducibility of 2D echocardiographic LAV/RAV. The same applies for LAV/RAV assessed by means of electroanatomic mapping which was performed

only once per patient by single experienced operator.

Finally, despite limitations of 2D echocardiography for the assessment of atrial volume, the vast majority of prognostic data is derived from this method. Therefore, before adoption of other imaging methods into clinical practice, their prognostic value should be assumed as unknown.

Conclusions

In patients with LSPAF and significant atrial remodeling, the 2D echocardiography with the use of single/biplane Simpson method significantly underestimated the atrial size compared to the

electroanatomic reference. Therefore, the results of this method should be interpreted with caution, especially when used for selection of suitable candidates for rhythm control strategies including catheter ablation. More focused studies are needed to disclose the main source of inaccuracy in atrial volume assessment by 2D echocardiography in patients with severe atrial dilation.

Conflict of Interest

There is no conflict of interest.

Acknowledgements

Grants of Czech Ministry of Health NR 9143-3/2007 and NS/9684-4/2008.

References

- ABHAYARATNA WP, SEWARD JB, APPLETON CP, DOUGLAS PS, OH JK, TAJIK AJ, TSANG TSM: Left atrial size: physiologic determinants and clinical applications. *J Am Coll Cardiol* **47**: 2357-2363, 2006.
- BADANO LP, PEZZUTTO N, MARINIGH R, CINELLO M, NUCIFORA G, PAVONI D, GIANFAGNA P, FIORETTI PM: How many patients would be misclassified using M-mode and two-dimensional estimates of left atrial size instead of left atrial volume? A three dimensional echocardiographic study. *J Cardiovasc Med* **9**: 476-484, 2008.
- BERRUEZO A, TAMBORERO D, MONT L, BENITO B, TOLOSANA JM, SITGES M, VIDAL B, ARRIAGADA G, MÉNDEZ F, MATIELLO M, MOLINA I, BRUGADA J: Pre-procedural predictors of atrial fibrillation recurrence after catheter ablation. *Eur Heart J* **28**: 836-841, 2007.
- BISBAL F, GUIU E, CALVO N, MARIN D, BERRUEZO A, ARBELO E, ORTIZ-PÉREZ J, DE CARALT TM, TOLOSANA JM, BORRÀS R, SITGES M, BRUGADA J, MONT L: Left atrial sphericity: a new method to assess atrial remodeling. Impact on the outcome of atrial fibrillation ablation. *J Cardiovasc Electrophysiol* **24**: 752-759, 2013.
- COZMA D, POPESCU BA, LIGHEZAN D, LUCIAN P, MORNOS C, GINGHINA C, DRAGULESCU SI: Left atrial remodeling: assessment of size and shape to detect vulnerability to atrial fibrillation. *Pacing Clin Electrophysiol* **30** (Suppl 1): S147-S150, 2007.
- FIALA M, WICHTERLE D, CHOVANČÍK J, BULKOVÁ V, WOJNAROVÁ D, NEVŘALOVÁ R, JANUŠKA J: Left atrial voltage during atrial fibrillation in paroxysmal and persistent atrial fibrillation patients. *Pacing Clin Electrophysiol* **33**: 541-548, 2010.
- HAISSAGUERRE M, HOCINI M, DENIS A, SHAH AJ, KOMATSU Y, YAMASHITA S, DALY M, AMRAOUI S, ZELLERHOFF S, PICAT MQ, QUOTB A, JESEL L, LIM H, PLOUX S, BORDACHAR P, ATTUEL G, MEILLET V, RITTER P, DERVAL N, SACHER F, BERNUS O, COCHET H, JAIS P, DUBOIS R: Driver domains in persistent atrial fibrillation. *Circulation* **130**: 530-538, 2014.
- HAVRANEK S, FIALA M, BULAVA A, SKNOURIL L, DORDA M, BULKOVA V, FINGROVA Z, SOUCKOVA L, PALECEK T, SIMEK J, LINHART A, WICHTERLE D: Multivariate analysis of correspondence between left atrial volumes assessed by echocardiography and 3-dimensional electroanatomic mapping in patients with atrial fibrillation. *PLoS One* **11**: e0152553, 2016.
- HOF I, ARBAB-ZADEH A, SCHERR D, CHILUKURI K, DALAL D, ABRAHAM T, LIMA J, CALKINS H: Correlation of left atrial diameter by echocardiography and left atrial volume by computed tomography. *J Cardiovasc Electrophysiol* **20**: 159-163, 2009a.

- HOF I, CHILUKURI K, ARBAB-ZADEH A, SCHERR D, DALAL D, NAZARIAN S, HENRIKSON C, SPRAGG D, BERGER R, MARINE J, CALKINS H: Does left atrial volume and pulmonary venous anatomy predict the outcome of catheter ablation of atrial fibrillation? *J Cardiovasc Electrophysiol* **20**: 1005-1010, 2009b.
- KOKA AR, GOULD SD, OWEN AN, HALPERN EJ: Left atrial volume: comparison of 2D and 3D transthoracic echocardiography with ECG-gated CT angiography. *Acad Radiol* **19**: 62-68, 2012.
- KUROTOBI T, IWAKURA K, INOUE K, KIMURA R, TOYOSHIMA Y, ITO N, MIZUNO H, SHIMADA Y, FUJII K, NANTO S, KOMURO I: The significance of the shape of the left atrial roof as a novel index for determining the electrophysiological and structural characteristics in patients with atrial fibrillation. *Europace* **13**: 803-808, 2011.
- LANG RM, BIERIG M, DEVEREUX RB, FLACHSKAMPF FA, FOSTER E, PELLIKKA PA, PICARD MH, ROMAN MJ, SEWARD J, SHANEWISSE JS, SOLOMON SD, SPENCER KT, SUTTON MS, STEWART WJ; CHAMBER QUANTIFICATION WRITING GROUP; AMERICAN SOCIETY OF ECHOCARDIOGRAPHY'S GUIDELINES AND STANDARDS COMMITTEE; EUROPEAN ASSOCIATION OF ECHOCARDIOGRAPHY: Recommendations for chamber quantification: a report from the American Society of Echocardiography's Guidelines and Standards Committee and the Chamber Quantification Writing Group, developed in conjunction with the European Association of Echocardiography, a branch of the European Society of Cardiology. *J Am Soc Echocardiogr* **18**: 1440-1463, 2005.
- LESTER SJ, RYAN EW, SCHILLER NB, FOSTER E: Best method in clinical practice and in research studies to determine left atrial size. *Am J Cardiol* **84**: 829-832, 1999.
- MACEIRA AM, COSÍN-SALES J, ROUGHTON M, PRASAD SK, PENNELL DJ: Reference left atrial dimensions and volumes by steady state free precession cardiovascular magnetic resonance. *J Cardiovasc Magn Reson* **12**: 65, 2010.
- MIYASAKA Y, TSUJIMOTO S, MAEBA H, YUASA F, TAKEHANA K, DOTE K, IWASAKA T: Left atrial volume by real-time three-dimensional echocardiography: validation by 64-slice multidetector computed tomography. *J Am Soc Echocardiogr* **24**: 680-686, 2011.
- MONTEFUSCO A, BIASCO L, BLANDINO A, CRISTOFORETTI Y, SCAGLIONE M, CAPONI D, DI DONNA P, BOFFANO C, CESARANI F, COIN D, PERVERSI J, GAITA F: Left atrial volume at MRI is the main determinant of outcome after pulmonary vein isolation plus linear lesion ablation for paroxysmal-persistent atrial fibrillation. *J Cardiovasc Med* **11**: 593-598, 2010.
- MOR-AVI V, YODWUT C, JENKINS C, KÜHL H, NESSER HJ, MARWICK TH, FRANKE A, WEINERT L, NIEL J, STERINGER-MASCHERBAUER R, FREED BH, SUGENG L, LANG RM: Real-time 3D echocardiographic quantification of left atrial volume: multicenter study for validation with CMR. *JACC Cardiovasc Imaging* **5**: 769-777, 2012.
- MÜLLER H, BURRI H, GENTIL P, LERCH R, SHAH D: Measurement of left atrial volume in patients undergoing ablation for atrial fibrillation: comparison of angiography and electro-anatomic (CARTO) mapping with real-time three-dimensional echocardiography. *Europace* **12**: 792-797, 2010.
- NARAYAN SM, KRUMMEN DE, SHIVKUMAR K, CLOPTON P, RAPPEL WJ, MILLER JM: Treatment of atrial fibrillation by ablation of localized sources: the conventional ablation for atrial fibrillation with and without focal impulse and rotor modulation (CONFIRM) trial. *J Am Coll Cardiol* **60**: 628-636, 2012.
- NEDIOS S, TANG M, ROSER M, SOLOWJOWA N, GERDS-LI JH, FLECK E, KRIATSELIS C: Characteristic changes of volume and three-dimensional structure of the left atrium in different forms of atrial fibrillation: predictive value after ablative treatment. *J Interv Card Electrophysiol* **32**: 87-94, 2011.
- PATEL VV, REN JF, JEFFERY ME, PLAPPERT TJ, ST JOHN SUTTON MG, MARCHLINSKI FE: Comparison of left atrial volume assessed by magnetic endocardial catheter mapping versus transthoracic echocardiography. *Am J Cardiol* **91**: 351-354, 2003.
- PIORKOWSKI C, HINDRICKS G, SCHREIBER D, TANNER H, WEISE W, KOCH A, GERDS-LI JH, KOTTKAMP H: Electroanatomic reconstruction of the left atrium, pulmonary veins, and esophagus compared with the true anatomy on multislice computed tomography in patients undergoing catheter ablation of atrial fibrillation. *Heart Rhythm* **3**: 317-327, 2006.

- PRITCHETT AM, JACOBSEN SJ, MAHONEY DW, RODEHEFFER RJ, BAILEY KR, REDFIELD MM: Left atrial volume as an index of left atrial size: a population-based study. *J Am Coll Cardiol* **41**: 1036-1043, 2003.
- RABBAT MG, WILBER D, THOMAS K, MALICK O, BASHIR A, AGRAWAL A, BISWAS S, SANAGALA T, SYED MA: Left atrial volume assessment in atrial fibrillation using multimodality imaging: a comparison of echocardiography, invasive three-dimensional CARTO and cardiac magnetic resonance imaging. *Int J Cardiovasc Imaging* **31**: 1011-1018, 2015.
- RODEVAN O, BJORNERHEIM R, LJOSLAND M, MAEHLE J, SMITH HJ, IHLEN H: Left atrial volumes assessed by three- and two-dimensional echocardiography compared to MRI estimates. *Int J Card Imaging* **15**: 397-410, 1999.
- ROSTOCK T, STEVEN D, HOFFMANN B, SERVATIUS H, DREWITZ I, SYDOW K, MÜLLERLEILE K, VENTURA R, WEGSCHEIDER K, MEINERTZ T, WILLEMS S: Chronic atrial fibrillation is a biatrial arrhythmia: data from catheter ablation of chronic atrial fibrillation aiming arrhythmia termination using a sequential ablation approach. *Circ Arrhythm Electrophysiol* **1**: 344-353, 2008.
- RUSSO C, HAHN RT, JIN Z, HOMMA S, SACCO RL, DI TULLIO MR: Comparison of echocardiographic single-plane versus biplane method in the assessment of left atrial volume and validation by real time three-dimensional echocardiography. *J Am Soc Echocardiogr* **23**: 954-960, 2010.
- SHIMADA YJ, SHIOTA T: Underestimation of left atrial volume by three-dimensional echocardiography validated by magnetic resonance imaging: a meta-analysis and investigation of the source of bias. *Echocardiography* **29**: 385-390, 2012.
- TSAO HM, YU WC, CHENG HC, WU MH, TAI CT, LIN WS, DING YA, CHANG MS, CHEN SA: Pulmonary vein dilation in patients with atrial fibrillation: detection by magnetic resonance imaging. *J Cardiovasc Electrophysiol* **12**: 809-813, 2001.
- UJINO K, BARNES ME, CHA SS, LANGINS AP, BAILEY KR, SEWARD JB, TSANG TS: Two-dimensional echocardiographic methods for assessment of left atrial volume. *Am J Cardiol* **98**: 1185-1188, 2006.
- VANDENBERG BF, WEISS RM, KINZEY J, ACKER M, STARK CA, STANFORD W, BURNS TL, MARCUS ML, KERBER RE: Comparison of left atrial volume by two-dimensional echocardiography and cine-computed tomography. *Am J Cardiol* **75**: 754-757, 1995.
- VON BARY C, DORNIA C, EISSNERT C, NEDIOS S, ROSER M, HAMER OW, GERDS-LI JH, PAETSCH I, JAHNKE C, GEBKER R, WEBER S, FLECK E, KRIATSELIS C: Predictive value left atrial volume measured by non-invasive cardiac imaging in the treatment of paroxysmal atrial fibrillation. *J Interv Card Electrophysiol* **34**: 181-188, 2012.
- ZHUANG J, WANG Y, TANG K, LI X, PENG W, LIANG C, XU Y: Association between left atrial size and atrial fibrillation recurrence after single circumferential pulmonary vein isolation: a systematic review and meta-analysis of observational studies. *Europace* **14**: 638-645, 2012.
-