

# Histological Aspects of Skeletal Muscle Fibers Splitting of C57BL/6NCrI Mice

Peter MAKOVICKÝ<sup>1</sup>, Pavol MAKOVICKÝ<sup>2</sup>

<sup>1</sup>Czech Centre for Phenogenomics, Institute of Molecular Genetic of the Czech Academy of Sciences, Vestec, Czech Republic. <sup>2</sup>Department of Biology, Faculty of Education, J. Selye University, Komarno, Slovak Republic

Received July 1, 2019

Accepted November 28, 2019

Epub Ahead of Print March 23, 2020

## Summary

The objective of the current study is to present data on the splitting of skeletal muscle fibers in C57BL/6NCrI mice. Skeletal muscles (*m. rectus femoris* (*m. quadriceps femoris*)) from 500 (250 ♀ and 250 ♂) C57BL/6NCrI mice in the 16th week of life were sampled during autopsy and afterwards standardly histologically processed. Results show spontaneous skeletal muscle fiber splitting which is followed by skeletal muscle fiber regeneration. One solitary skeletal muscle fiber is split, or is in contact with few localized splitting skeletal muscle fibers. Part of the split skeletal muscular fiber is phagocytosed, but the remaining skeletal muscular fiber splits are merged into one regenerating skeletal muscle fiber. Nuclei move from the periphery to the regenerating skeletal muscle fiber center during this process. No differences were observed between female and male mice and the morphometry results document <1 % skeletal muscle fiber splitting. If skeletal muscular fibers splitting occurs 5 %> of all skeletal muscular fibers, it is suggested to describe and calculate this in the final histopathological report.

## Key words

Myopathology • Skeletal muscle fiber • Regeneration • Skeletal muscles

## Corresponding author

Peter Makovický, Czech Centre for Phenogenomics, Institute of Molecular Genetic of the Czech Academy of Sciences, Průmyslová 595, 252 50 Vestec, Czech Republic. E-mail: peter.makovicky@img.cas.cz

## Introduction

Skeletal muscle regeneration is a highly

orchestrated process and the factors that impact skeletal muscle structure, function and regeneration are of great importance and interest not only scientifically but also clinically. This means, skeletal muscles regeneration is in the interest of medical research (Kinter and Sinnreich 2014, Liu *et al.* 2018). Today skeletal muscle regeneration is studied at a high level including injury, development, factors contributing to regeneration, satellite cells, stem cells, the role of secreted factors and extracellular matrix remodelling (Baghdadi and Tajbakhsh 2018, Liu *et al.* 2019, Wosczyzna *et al.* 2019). The results are important for applied research and especially for muscular dystrophies, which are characterized by atrophy, degeneration and fragmentation of skeletal muscle fibers with a partial or complete loss of contractility. It is well known, that smaller mechanical damage to skeletal muscle fibers can be accompanied by regeneration, but traumas that are more extensive are always followed by reparation with fibrosis (Filip *et al.* 2019, Holecck and Micuda 2017, Li *et al.* 2017, Morimoti *et al.* 2015, Ohno *et al.* 2019, Wens *et al.* 2019). Skeletal muscular fibers splitting with creating new skeletal muscular fibers are in this study present as possible activators or one ways to skeletal muscles regeneration (Antonio and Gonyea 1994). Most experiments are now carried out on rodents, due to their size, low breeding costs, high reproduction rate and stable genetic background. The mouse (*Mus musculus*, family Muridae) is the preferred laboratory animal in basic research. The International Mouse Phenotyping Consortium (IMPC) is an international effort by 19 research institutions to identify the function of every protein-coding gene in the mouse genome. Several

objectives were identified (Meehan *et al.* 2017). Mice are produced and maintained on a C57BL/6N genetic background with support mice derived from C57BL/6NJ, C57BL/6NTac, or C57BL/6NCrl. All phenotyping centers across the world follow standards and generate seven females and seven male homozygotes, and compare them with seven female and seven male of the mentioned control mice. Veterinary pathologists play an important role, especially towards the end of the phenotyping process during necropsies, as well as evaluating histological slides of sampled organs. Cross-striated skeletal muscles are mandatory part of this sampling procedure. Here in this article, we suggest that the final histology results should describe two individual parameters related to the splitting of skeletal muscular fibers. First, to recognize and define skeletal muscular fiber splitting and second to calculate the percentage of split skeletal muscular fibers. This is descriptive light microscopy histopathological work and findings could be useful for the highly focused community in rodent histopathology. The objective of this study is to present data on the skeletal muscular fiber splitting in a wider set of proprietary material using C57BL/6NCrl mice skeletal muscles of *m. rectus femoris (m. quadriceps femoris)*.

## Material and Methods

### *Animal characteristics*

In this study C57BL/6NCrl mice were investigated and histologically examined in the Histopathology unit of the Czech Centre for Phenogenomics in Vestec as part of the phenogenic screening. The Histopathology laboratory adheres to good laboratory practice (GLP) and all steps of mouse sample processing are according to standard operation procedures (SOP). All mice were sampled at 16 weeks of age. Femoral skeletal muscles of the right and left pelvic limbs were used for this purpose. Skeletal muscles (*m. rectus femoris (m. quadriceps femoris)*) from 500 (250 ♀ and 250 ♂) healthy C57BL/6NCrl mice were sampled during the autopsy. Mice were anesthetized using Isoflurane appropriately (Forane<sup>®</sup>, AbbVie s.r.o., Prague, Czech Republic) and a dosing device. Subsequently, they were euthanized and skeletal muscles were sampled up to 20 min. after euthanasia.

### *Histological procedures*

The skeletal muscles were fixed for a minimum of 24 hours in 4% formalin solution. Material was

excised and skeletal muscles were transversally oriented, and processed according to standardized protocols using autotechnicon Leica ASP 6P25 (Leica Biosystems Nussloch GmbH, Heidelberger, Germany). All samples were embedded into paraffin blocks using embedding station Leica EG 1150H (Leica Biosystems Nussloch GmbH, Heidelberger, Germany). Samples were cut on rotary microtome Leica RM2255 (Leica Biosystems Nussloch GmbH, Heidelberger, Germany). Serial slices were placed onto standard slides (Knittel Glass GmbH, Sakska, Germany) and stained with hematoxylin-eosin and integrated into permanent histological preparation with an automated staining station SYMPHONY system (Ventana Medical Systems, Inc. Tuscon, Arizona, USA).

### *Samples evaluation*

Two slices per mouse were placed on each slide and analyzed. The prepared samples were evaluated as light-microscopic images obtained using the Carl Zeiss Axio Scope A1 (Zeiss, Munchen, Germany) at magnifications 50x, 100x, 200x and 400x (Zeiss, Munchen, Germany). The slides were also evaluated using AxioScan.Z1 slide scanner (Zeiss, Munchen, Germany) and the percentage of split skeletal muscular fibers to all skeletal muscular fibers was quantified for each slide. The results were averaged and compared between male and female mice.

### *Statistical analysis*

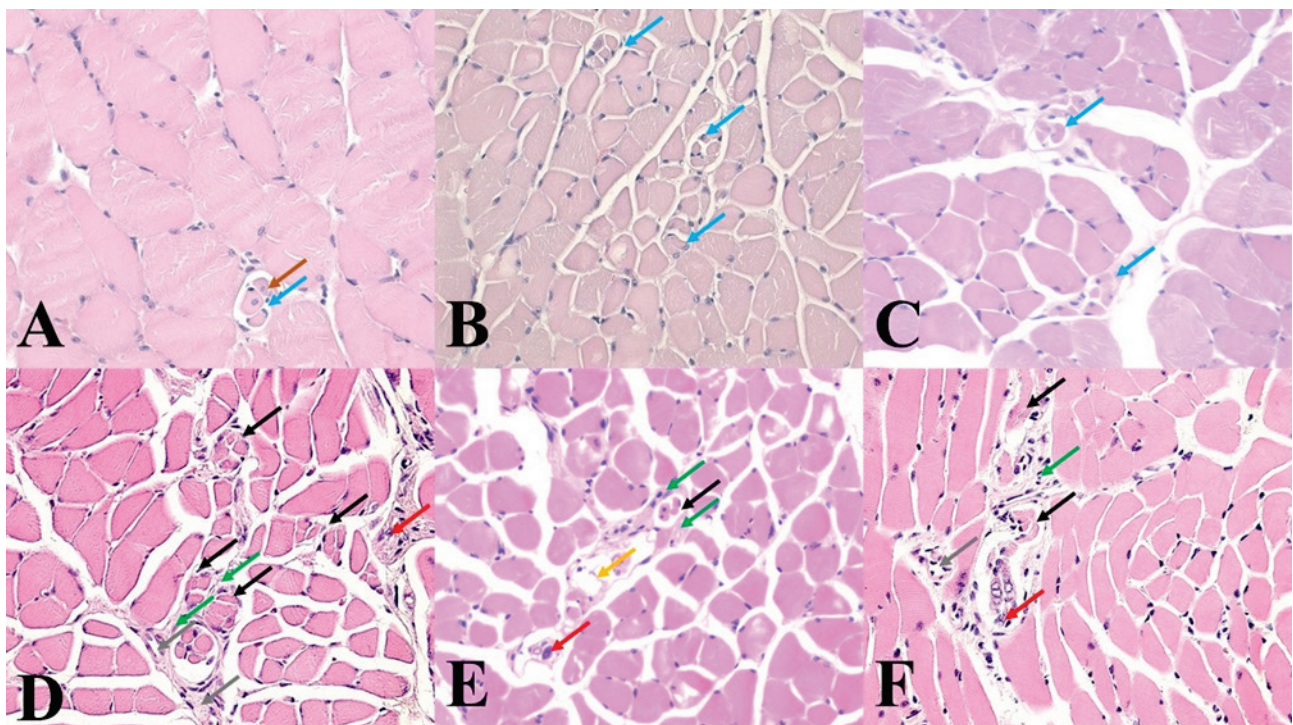
The morphometry results were analyzed using ANOVA and statistical computation was carried out using Statistix9 and IfoStat packages. Differences were declared significant at  $p < 0.05$ .

## Results

Histological view with partially transversally, partially longitudinally sectioned skeletal muscles with sporadically visible solitary arranged hypertrophic spherical shape basophilic skeletal muscle fibers, which are mostly localized in the periphery of a primary muscle septum. Part of them are split to several miniature, shapeless, or triangular formations. Some have similar thicknesses compared to normal skeletal muscle fibers. The splitting mechanism is almost identical. An individual skeletal muscle fiber is visible, or there are few skeletal muscle fibers in close proximity to each other (Fig. 1A, and Fig. 1B). Mostly however, the sarcolemma remains preserved, and the skeletal muscular

fiber split at one section into several thinner ellipsoid daughter units with several highlighted lighter nuclei. Subsequently, there is skeletal muscle fiber hypertrophy with nuclei movement at their periphery. Part of the split skeletal muscle fiber is phagocytosed and what remains is able to merge into one skeletal muscle fiber (Fig. 1C). The nuclei move from the periphery to the center of a split skeletal muscle fiber. Such skeletal muscle fibers are well recognizable due to the presence of bright, vesicular nuclei with prominent nucleoli when organized in chain formations and approach each other from opposite sides (Fig. 1D). The process continues until the nuclei interfere with each other at complete skeletal muscle fiber renewal. Consequently, the nuclei acquires a classical oval to semi-circular shape with subsarcolemal localization. In

certain areas there is an interstitial reaction where the increasing content of epimysium surrounding the splitting skeletal muscular fibers is visible (Fig. 1E). In some individual cases, with an increasing content of split skeletal muscle fibers there are junctions between peripheral nerves and skeletal muscle fibers visible with focal axon degeneration (Fig. 1F). Others in the full material normal perimysium and normal several miniature capillaries are visible. No significant differences in the average percentage of skeletal muscular fiber regeneration, average percentage of hypertrophic skeletal muscular fibers and finally the average percentage of splitting skeletal muscular fibers were observed between female and male mice ( $p < 0.05$ ).



**A)** a cross-section of skeletal muscles with one well visible split skeletal muscular fiber. The brown arrow shows centrally localized nuclei and the blue arrow shows peripheral localized nuclei. Legend: HE: 400x. **B)** variably sized ellipsoid split skeletal muscular fibers. the blue arrows show nuclei localized at the periphery. Legend: HE: 400x. **C)** split skeletal muscular fibers. blue arrows show several ellipsoid formations with almost peripherally localized nuclei. Legend: HE: 400x. **D)** notably increased content of split skeletal muscle fibers (black arrows) with peripherally localized interstitial reaction (green arrows). The red arrow shows a periphery nerve and the grey arrow shows a capillary. **E)** view of the junction between periphery nerves (red arrow) and several split skeletal muscle fibres (black arrow) with focal skeletal muscle fiber necrosis (yellow arrow) and peripherally localized interstitial reaction (green arrows). **F)** another view of the junction between periphery nerves (red arrow) and several longitudinally sectioned split skeletal muscle fibres (black arrow) with periphery localised interstitial reaction (green arrows), the grey arrow shows a capillary.

## Discussion

Skeletal muscle tissue damage and the following repair or regeneration are today intensively studied from many different views with high clinical importance. The

regeneration of skeletal muscle fibers in skeletal muscles can occur in two ways; the origin of new skeletal muscle fibers derived from undifferentiated cells or autoregeneration of existing skeletal muscle fibers. The first option is to activate satellite cells that survive

between fully differentiated skeletal muscle fibers. However, there are only limited possibilities (Forcina *et al.* 2019). The second variant consists in the splitting of existing skeletal muscle fibers. We have observed this phenomenon in our samples repeatedly and histologically there are differences between skeletal muscle fiber regeneration after injury, and skeletal muscle fiber splitting. An isolated splitting skeletal muscle fiber is a common finding, however if skeletal muscle fiber splitting exceeds 5% value on evaluated slices, we believe this should be recorded and calculated in the final histopathology report. Here the veterinary pathologist can note if splitting is sufficient to compensate muscular defect, towards the relationships with normal skeletal muscle fibers. Other information about changes in the blood or lymphatic vessels, nerve fibers, the amount and type of connective tissue and necrosis should also be in the final report stated. In comparison to our previous work, where we observed the frequency of splitting skeletal muscle fibers in skeletal muscle of pigs. We found that with a pig's increasing age, a percentage increase in the occurrence of splitting skeletal muscle fibers is apparent, but this process has no importance in postnatal growth of skeletal muscle (Makovický *et al.* 2015). Muscle splitting, proliferation of residual cellular islets, recombination of preserved skeletal muscle fibers and residual sarcoplasm have been observed histologically (Maxie 2016). On the other hand, it is not fully understood if the splitting of skeletal muscle fibers plays some role in the regeneration of damaged skeletal muscles, and is still a matter of research (Chen *et al.* 2019, Siles *et al.* 2019). There may be some differences in skeletal muscular fibers, including tissue responsiveness to internal and external influences. Therefore, we think that this phenomenon can be interpreted as a sign of muscular disruption. On the other hand, we here also accept an alternative of periphery nerve-skeletal muscles excitement exchange disorder. So finally skeletal muscle fibers splitting can be interpreted also as muscular fiber degeneration, followed by skeletal muscle fiber regeneration. For example, in standard veterinary bioptic practice, we practically do not see any skeletal muscular fibers splitting in domestic animals. On the other hand, using rodents, we had the opportunity to investigate multiple muscles at once in one histological preparation, comprising of a greater percentage of muscle tissue compared to the samples taken from the skeletal muscles of larger animals. Also in the scientific literature, there is an alternative to skeletal muscle fiber hyperplasia

in adult skeletal muscles, but with significant differences in individual animal species (Brown 2000). By comparing our findings and conclusions with data in the scientific literature, we find partially similar and partially conflicting views. Generally, the hypothesis is that regeneration of skeletal muscles is dependent on the extent of skeletal muscle tissue damage. When the sarcoplasm and at least some of the nuclei remain preserved, the regeneration may be complete. The sarcoplasm increases its volume and produces multinuclear multinuclei protoplasmic islets that bind to become a syncytium. However, damage to muscle tissue with complete disruption of skeletal muscle fibers will always end with reparation. One study, for example, states that skeletal muscles regeneration takes place in two interdependent phases (Charge and Rudnicki 2004). This is a degenerative and regenerative phase. Necrosis of damaged skeletal muscle fibers along with the presence of inflammation are the main parts of the degenerative phase, which could also correspond with our findings when part of the split skeletal muscle fiber remains phagocytosed. In the regenerative phase, myogenic cells are activated in which the myofibrils are synthesized and arranged. At this stage, skeletal muscle fiber splitting was also observed, but this is explained as a result of insufficient fusion of regenerative skeletal muscle fibers (Cabral *et al.* 2008). Some of the works describing the splitting of skeletal muscle fibers are related to hypertrophic or even giant skeletal muscle fibers (Fazarin *et al.* 2002). On the contrary, we document that the splitting phenomenon is not bound to skeletal muscle fiber calibre. Here we believe that the thickness of skeletal muscle fibers is limited by the possibilities of transporting nutrients and oxygen to skeletal muscle fibers and vice versa. Murach *et al.* (2019) hypothesizes that fiber splitting is a non-pathological component of extreme loading and hypertrophy, which is primarily supported by evidence in animals, and proposes that the mechanisms and consequences of fiber splitting deserve further exploration. This partly correlates with our previous findings when we found that larger skeletal muscle fibers and especially hypertrophic, possibly giant skeletal muscle fibers are predisposed to splitting (Makovický 2010). Conversely, the increased percentage of split skeletal muscle fibers ultimately endangers skeletal muscle function (Kiriaev *et al.* 2018). In any case, it is true that hypertrophic skeletal muscle fibers usually become subject to splitting. These can be splits into several thin to miniature basophilic elements, which

sometimes markedly resemble isolated myoblasts, or myotubes with several bright vesicular nuclei and prominent nucleoli. However, it is a question of whether these are separate skeletal muscle fibers, which do not yet explain the mechanism of the formation of sarcolemma by splitting. There is a hypothesis that the original skeletal muscle fiber remains continuous, but in several places it was in fact split. It is not about the creation of separate skeletal muscle fibers, but only about sister skeletal muscle fibers within one. Here, we are inclined to the hypothesis of myofibril damage with their branching and subsequent disintegration of the hypertrophic skeletal muscle fiber (Faber *et al.* 2014). However, it is doubtful whether a part of the skeletal muscle fiber is able to regenerate, especially if part of the split skeletal muscular fiber remains phagocytosed. Another study was based on the assumption that hypertrophic skeletal muscle fibers are the result of muscle damage and the splitting of skeletal muscle fibers is the result of an older trauma, while others reflect the ongoing traumatic process (Eriksson *et al.* 2006). Contrary to us, the authors of this study have analyzed samples of the skeletal muscle of weightlifters, where the splitting is subject to particularly

hypertrophic skeletal muscle fibers. It is well known that excessive muscular effort can lead to rhabdomyolysis and thus to the spectrum of degenerative changes in skeletal muscle fibers. The projected patterns of splitting hypertrophic skeletal muscle fibers could therefore respond to decaying skeletal muscle fibers. Microscopic changes here represent a continuum whose end stage is the removal of necrotic skeletal muscle fibers by phagocytosis.

### Conflict of interest

There is no conflict of interest.

### Acknowledgement

Supported by RVO 68378050, BIOCEV-CZ.1.05/1.1.00/02.0109, LM2015040, CZ.1.05/2.1.00/19.0395. Thanks to Czech Centre for Phenogenomics, Histopathology unit staff (Attila Juhász, Tereza Kalendová, MSc. Jan Kučera, MSc. Linda Kutlíková, MSc. Vanessa Pianta, MSc. Markéta Pícková, MSc. Ivana Pohorecká, Jana Zima, DiS.) for their excellent histological service. Special thanks to B.Sc. Miles Joseph Raishbrook for his English editorial assistance with this manuscript.

### References

- ANTONIO J, GONYEA WJ: Muscle fiber splitting in stretch-enlarged avian muscle. *Med Sci Sports Exerc* 26: 973-977, 1994. <https://doi.org/10.1249/00005768-199408000-00007>
- BAGHDADI MB, TAJBAKSH S: Regulation and phylogeny of skeletal muscle regeneration. *Dev Biol* 433: 200-209, 2018. <https://doi.org/10.1016/j.ydbio.2017.07.026>
- CABRAL AJV, MACHADO V, FARINDA R, CABRITA A: Skeletal muscle regeneration: a brief review. *Exp Pathol Health Sci* 2: 9-17, 2008.
- BROWN LE: Skeletal muscle fiber hyperplasia: Why it can or cannot occur in humans. *Strength Cond J* 22: 28-29, 2000. <https://doi.org/10.1519/00126548-200004000-00008>
- ERIKSSON A, LINDSTROM M, CARLSSON L, THORNELL LE: Hypertrophic muscle fibers with fissures in powerlifters; fibers splitting or defect regeneration? *Histochem Cell Biol* 126: 409-417, 2006. <https://doi.org/10.1007/s00418-006-0176-3>
- FABER RM, HALL JK, CHAMBERLAIN JS, BANKS GB: Myofiber branching rather than myofiber hyperplasia contributes to muscle hypertrophy in mdx mice. *Skeletal Muscle* 23: 10, 2014. <https://doi.org/10.1186/2044-5040-4-10>
- FAZARINC G, CANDEK-POTOKAR M, URSIC M, VRECL M, POGACNIK A: Giant muscle fibres in pigs with different Ryr1 genotype. *Anat Histol Embryol* 31: 367-371, 2002. <https://doi.org/10.1046/j.1439-0264.2002.00420.x>
- FILIP S, MOKRY J, FOROSTYAK O, DAYANITHI G: Analysis of Ca(2+) signaling mechanisms – our experience on the intercellular communication in muscle remodeling. *Physiol Res* 68: 325-328, 2019. <https://doi.org/10.33549/physiolres.934082>
- FORCINA L, MIANO C, PELOSI L, MUSARO A: An overview about the biology of skeletal muscle Satellite cells. *Curr Genomics* 20: 24-37, 2019. <https://doi.org/10.2174/1389202920666190116094736>

- CHARGE SB, RUDNICKI MA: Cellular and molecular regulation of muscle regeneration. *Physiol Rev* 84: 209-238, 2004. <https://doi.org/10.1152/physrev.00019.2003>
- CHEN F, ZHOU J, LI Y, ZHAO Y, CAO Y, WANG L, ZHANG Z, ZHANG B, WANG CC, CHEUNG TH, WU Z, WONG CC, SUN H, WANG H: YY1 regulates skeletal muscle regeneration through controlling metabolic reprogramming of Satellite cells. *EMBO J* 38: 99727, 2019. <https://doi.org/10.15252/embj.201899727>
- HOLECEK M, MICUDA S: Amino acid concentrations and protein metabolism of two types of rat skeletal muscle in postprandial state and after brief starvation. *Physiol Res* 66: 959-967, 2017. <https://doi.org/10.33549/physiolres.933638>
- KINTER J, SINNREICH M: Molecular targets to treat muscular dystrophies. *Swiss Med Wkly* 144: 13916, 2014. <https://doi.org/10.4414/smw.2014.13916>
- KIRIAEV L, KUEH S, MORLEY JW, NORTH KN, HOUWELING PJ, HEAD SI: Branched fibers from old fast-twitch dystrophic muscles are the sites of terminal damage in muscular dystrophy. *Am J Physiol Cell Physiol* 314: C662-C664, 2018. <https://doi.org/10.1152/ajpcell.00161.2017>
- LI XY, FU LL, CHENG HJ, ZHAO SH: Advances on microRNA in regulating mammalian skeletal muscle development. *Yi Chuan* 39: 1046-1053, 2017. <https://doi.org/10.16288/j.ycz.17-112>
- LIU J, SAUL D, BOKER KO, ERNST J, LEHMAN W, SCHILLING AF: Current methods for skeletal muscle tissue repair and regeneration. *BioMed Res Int* 1: 1984897, 2018. <https://doi.org/10.1155/2018/1984879>
- LIU X, ZENG Z, ZHAO L, CHEN P, XIAO W: Impaired skeletal muscle regeneration induced by macrophage depletion could be partly ameliorated by MGF injection. *Front Physiol* 10: 601, 2019. <https://doi.org/10.3389/fphys.2019.00601>
- MAKOVICKY P: Histological study of giant fibres in skeletal muscles of pigs. *Fleischwirt Int* 25: 966-968, 2010.
- MAKOVICKY P, MAKOVICKY P, LIPPAI R, SZIKSZ E, SAMASCA G: A harántcsíkolt izomrostok fejlődése és növekedése. (In Hungarian) *Magy Allatorvosok* 137: 559-567, 2015.
- MAXIE G: *Jubb, Kenedy, and Palmers Pathology of domestic animals*. St. Louis, Elsevier 798, 2010.
- MEEHAN TF, CONTE N, WEST DB, JACOBSEN JO, MASON J, WARREN J, CHEN CK, TUDOSE I, RELAC M, MATTHEWS P, et al.: Disease model discovery from 3,328 gene knockouts by The International Mouse Phenotyping Consortium. *Nat Genet* 8: 1231-1238, 2017. <https://doi.org/10.1038/ng.3901>
- MORIMOTO Y, KONDO Y, KATAOKA H, HONDA Y, KOZU R, SAKAMOTO J, NAKANO J, ORIGUCHI T, YOSHIMURA T, OKITA M: Heat treatment inhibits skeletal muscle atrophy of glucocorticoid-induced myopathy in rats. *Physiol Res* 64: 897-905, 2015.
- MURACH KA, DUNGAN CM, PETERSON CA, MCCARTHY JJ: Muscle fiber splitting is a physiological response to extreme loading in animals. *Exerc Sport Sci Rev* 47: 108-115, 2019. <https://doi.org/10.1249/JES.0000000000000181>
- OHNO Y, EGAWA T, YOKOYAMA S, FUJAYA H, SUGIURA T, OHIRA Y, YOSHIOKA T, GOTO K: MENS-associated increase of muscular protein content via modulation of caveolin-3 and TRIM72. *Physiol Res* 68: 265-273, 2019. <https://doi.org/10.33549/physiolres.933992>
- SILES L, NINFALI C, CORTES M, DARLING DS, POSTIGO A: ZEB1 protects skeletal muscle from damage and is required for its regeneration. *Nat Commun* 10: 1364, 2019. <https://doi.org/10.1038/s41467-019-08983-8>
- WENS I, DALGAS U, VERBOVEN K, KOSTEN L, STEVENS A, HENS N, EIJNDE BO: Impact of high intensity exercise on muscle morphology in EAE rats. *Physiol Res* 64: 907-923, 2015.
- WOSCZYNA MN, KONISHI CT, PEREZ CARBAJAL EE, WANG TT, WALSH RA, GAN Q, WAGNER MW, RANDO TA: Mesenchymal stromal cells are required for regeneration and homeostatic maintenance of skeletal muscles. *Cell Rep* 27: 2029-2035, 2019. <https://doi.org/10.1016/j.celrep.2019.04.074>
-