

IDH2-Deficient Mice Develop Spinal Deformities With Aging

U. CHAE^{1,2*}, N.-R. PARK^{3*}, E. S. KIM⁴, J.-Y. CHOI³, M. YIM⁵, H.-S. LEE^{1,2}, S.-R. LEE⁷, S. LEE⁶, J.-W. PARK^{1,2}, D.-S. LEE^{1,2}

* These authors contributed equally to this work.

¹School of Life Sciences and Biotechnology, BK21 Plus KNU Creative BioResearch Group, Kyungpook National University, Daegu, Republic of Korea, ²College of Natural Sciences, Kyungpook National University, Daegu, Republic of Korea, ³Department of Biochemistry and Cell Biology, Cell and Matrix Research Institute, BK21 Plus KNU Biomedical Convergence Program, School of Medicine, Kyungpook National University, Daegu, Republic of Korea, ⁴Department of Orthopedic Surgery, Yuseong Sun General Hospital, Daejeon, Republic of Korea, ⁵College of Pharmacy, Sookmyung Women's University, Seoul, Republic of Korea, ⁶Animal Biotechnology Division, National Institute of Animal Science, Rural Development Administration, Jeollabuk-do, Republic of Korea, ⁷National Primate Research Center, Korea Research Institute of Bioscience and Biotechnology (KRIBB), Cheongju, Republic of Korea

Received July 11, 2017

Accepted February 9, 2018

On-line March 12, 2018

Summary

Spinal deformities such as scoliosis and kyphosis are incurable, and can lead to decreased physical function, pain, and reduced quality of life. Despite much effort, no clear therapies for the treatment of these conditions have been found. Therefore, the development of an animal model for spinal deformity would be extremely valuable to our understanding of vertebral diseases. In this study, we demonstrate that mice deficient in the mitochondrial enzyme isocitrate dehydrogenase 2 (IDH2) develop spinal deformities with aging. We use morphological analysis as well as radiographic and micro-CT imaging of IDH2-deficient mice to characterize these deformities. Histological analysis showed increased abnormalities in IDH2-deficient mice compared to wild type mice. Taken together, the results suggest that IDH2 plays a critical role in maintaining the spinal structure by affecting the homeostatic balance between osteoclasts and osteoblasts. This indicates that IDH2 might be a potent target for the development of therapies for spinal deformities. Our findings also provide a novel animal model for vertebral disease research.

Key words

Isocitrate dehydrogenase 2 • Spinal deformity • Osteoclast • Osteoblast • Aging • Animal models

Corresponding authors

J.-W. Park and D.-S. Lee, College of Nature Sciences, Kyungpook National University, Daegu 41566, Republic of Korea. E-mail: parkjw@knu.ac.kr and lee1@knu.ac.kr

Introduction

Spinal deformities, including scoliosis and kyphosis, are common vertebral diseases, which can result in suppression of physical function and other clinical symptoms. Scoliosis presents as abnormal sideways spinal curvature in all age groups, and can result in delayed development, muscle imbalance, and breathing difficulties. In contrast to scoliosis, kyphosis involves abnormal forward curvature of the spine, disrupting spinal balance and affecting the ability of the spine to effectively support the body weight (Ito *et al.* 2016). Kyphosis can be classified into two types: primary kyphosis, also called Scheuermann's disease, which occurs in children and teenagers, and secondary kyphosis, which occurs as a result of the aging process. Many studies have associated specific genes with spinal deformities (Juneja *et al.* 2014, Kim *et al.* 2013), but the

mechanisms by which these genes affect spinal deformities remain unknown. A particular difficulty in the study of spinal deformities has been a lack of animal models to study these diseases.

Isocitrate dehydrogenases catalyze the oxidative decarboxylation of isocitrate to α -ketoglutarate as part of the tricarboxylic acid (Krebs) cycle. These enzymes are separated into two subclasses, which use NAD^+ or NADP^+ as electron acceptors to form NADH and NADPH , respectively (Smolkova and Jezek 2012). There are three isotypes of isocitrate dehydrogenase: mitochondrial NAD^+ dependent IDH3, cytosolic NADP^+ dependent IDH1, and mitochondrial NADP^+ dependent IDH2. IDH1 and IDH2 mutations have aggressive effect against glioma formation (Megova *et al.* 2014). IDH mutations have also been also detected in breast cancer (Fathi *et al.* 2014), prostate cancer (Ghiam *et al.* 2012) and acute myelogenous leukemia (Rakheja *et al.* 2012) which suggests that IDHs may play important roles in many types of tumors. Accordingly, many studies have demonstrated that IDH2 plays a critical role in oncogenesis (Reitman *et al.* 2010), as well as in cell defense mechanisms against oxidative damage (Yu *et al.* 2012) and neurotoxicity (Kim *et al.* 2016). IDH2 deficiency results in increased generation of intracellular peroxide, leading to oxidative damage and decreased cell survival. Previous studies have suggested that oxidative stress-induced inflammation can be a causative factor in many diseases, including osteoporosis and osteoarthritis (Basu *et al.* 2001, Banfi *et al.* 2008). Several studies have also suggested that age-related ROS production can cause bone abnormalities (Loeser 2010) indicating that regulation of ROS may be helpful in the treatment of bone diseases. We have reported that IDH2 has an important role as an NADPH donor, ensuring adequate amounts of reduced glutathione and peroxiredoxin (Smolkova and Jezek 2012, Jo *et al.* 2001). Therefore, IDH2 may play an important role during age-related ROS production.

Considering the regulatory role of IDH2, we speculated that IDH2 might affect bone formation and deformity. In the present study, we have used IDH2-deficient (knockout, $\text{Idh2}^{-/-}$) and wild type ($\text{Idh2}^{+/+}$) mice to investigate the effects of IDH2 on the incidence of bone abnormalities through morphological, medical imaging, and histological analyses.

Methods

Animals

All animal experiments were approved and performed in accordance with the guidelines of the Animal Care Committee of Kyungpook National University. The mice used in this study were $\text{IDH2}^{-/-}$ germ-line knockout mice. The generation and genetic background of $\text{IDH2}^{-/-}$ mice has been described previously (Kim *et al.* 2014). C57BL/6J mice were used as wild-type (WT) controls. The animals were housed at 24 °C with a 12 h light/dark cycle and free access to water and food. Classification of mice was carried out with DNA extracted from the tails using the Direct PCR Lysis Reagent (Viagen Biotech, Los Angeles, California, USA). DNA was amplified by PCR and the genotypes were confirmed by electrophoresis.

Morphology, radiography, and micro-CT scanning

Gross morphology was examined immediately after the mice were anesthetized. Micro-CT was performed on vertebrae and long bones using MICRO-CT equipment (Siemens Healthcare, Inveon, KBSI, Ochang Center, Chungcheongbuk-do, Republic of Korea). X-ray analysis was performed using the same equipment. Radiography was carried out at 80 Kv and 500 μA , with a 200 ms exposure time. Analysis of micro-CT and X-ray images was performed with an Inveon Research Workplace (IRW, Siemens Healthcare). Bone density and other parameters were detected between 0.7 and 2.3 mm below the growth plate on trabecular bone. Nomenclature of all bone micro-CT data follows the guidelines of the American Society for Bone and Mineral Research (ASBMR) (Bouxsein *et al.* 2010).

Histological analyses

Mice were sacrificed at 10, 27, and 47 weeks, fixed in 4 % paraformaldehyde (Merck, Darmstadt, Germany) for 72 h, and decalcified in 14 % EDTA for 10 days. After decalcification, spinal tissues were embedded in paraffin blocks. Hematoxylin and eosin (H&E) staining and tartrate-resistant acid phosphatase (TRAP) staining was performed on sectioned samples using standard protocols. For von Kossa staining, calcified bones were mounted in paraffin and sectioned at 3 μm , as previously described (Erben 1997).

Statistical analysis

Values are presented as the mean \pm SEM for three or more independent experiments. Group comparison analysis and Dunnett's multiple comparison tests were performed with GraphPad Prism version 5.0 (GraphPad Software, La Jolla, CA, USA). A $p < 0.05$ was considered statistically significant.

Results

The spines of IDH2-deficient mice display morphological changes with aging

To begin our comparison of control and IDH2-deficient mice, we measured size, body weight, and morphology. There were no differences in size or body weight between IDH2-deficient mice and control mice (data not shown). Both lateral and dorsal views of mice stripped of epidermis displayed visible spinal deformities in the IDH2-deficient mice at 47 weeks, but not at 27 weeks (Fig. 1A-B). Knockout of IDH2 was confirmed by genotyping analysis, with the 1055-bp band representing IDH2 observed in the control mice, but not the IDH2 knockout mice (Fig. 1C). Because IDH2 is the key enzyme of mitochondrial functions related with ROS generation (Ku *et al.* 2015), we confirmed ROS levels of tissues in IDH2-deficient mice. As we expected, ROS level of IDH2-deficient mice was increased compared with control mice (Fig. 1D). These findings indicate that IDH2 gene deficiency plays a critical role in maintenance of spine morphology in later age.

Analysis of spinal abnormalities in IDH2-deficient mice by X-ray and micro-CT imaging

We next used radiographic methods to confirm and further study the observed spinal abnormalities in IDH2-deficient mice. First, X-ray assessment was performed in the lateral and dorsal planes. In the lateral plane, although there were no significant spinal abnormalities in 27-week-old mice, X-ray assessment revealed significant spinal abnormalities in the cervical and thoracic spines in 47-week-old IDH2-deficient mice (Fig. 2A). However, in the dorsal plane, no significant difference between control and IDH2-deficient mice was observed (Fig. 2B).

Lateral views of micro-CT images had similar appearance to the X-ray assessments (Fig. 3A), confirming that spinal curvature in IDH2-deficient mice dramatically increased after 27 weeks. The 3D-reconstruction images also display spinal abnormalities that

increase in curvature after 27 weeks (Fig. 3B). By 47 weeks, the spinal curvature of IDH2-deficient mice through the cervical and thoracic spine was nearly 90°. Bone mineral density in IDH2-deficient mice was found to be significantly lower than in wild type mice (Fig. 3C), as micro-CT analysis consistently showed that the ratio of trabecular bone volume to tissue volume was significantly lower in IDH2-deficient mice. The trabecular thickness and trabecular number were also reduced in IDH2-deficient mice compared to wild type, and trabecular separation was increased. Consistent with these results, 3D visualization of the spine clearly showed increased loss of trabecular bone in IDH2-deficient mice compared to wild type (Fig. 3D). The results of X-ray and micro-CT images analysis indicate that IDH2-deficient mice may develop bone abnormalities more quickly than wild type mice.

Histological analysis of bone from IDH2-deficient mice

In order to determine the underlying cause of the observed spinal deformities in IDH2-deficient mice, we next investigated histological changes in the bone tissue. Hematoxylin and Eosin (H&E) staining detected almost no difference in young mouse but more marked osteopenia in the thoracic vertebrae of old IDH2-deficient mice compared with corresponding sites in control mice (Fig. 4A). Vertebral bodies which is the core of hypertrophic chondrocytes of IDH2-deficient mice indicated different phenotype than controls. We also H&E stained cortical bone from each time point to observe the detailed structure of the trabecular sites. Although the trabecular endplates at 27 weeks indicated no significant changes in spongy or membrane bones between control and IDH2-deficient mice, at 47 weeks there were severe changes in both spongy bone and membrane bone in IDH2-deficient mice compared with control mice (Fig. 4B). Ultimately, the boundary between cortical and spongy bone became unclear, and the general structure of the endplates of cortical bones in IDH2-deficient mice was destroyed. Therefore, the results indicate that the bone disorder observed in IDH2-deficient mice might be severe enough to interfere with bone function and decrease its ability to support the body.

To further examine the cause of spinal deformities and aging-induced bone loss in IDH2-deficient mice, we next performed activity analysis of osteoclasts (using TRAP staining) and osteoblasts (with von Kossa staining) at 10, 27, and 47 weeks in control and IDH2-deficient mice. The number of TRAP-positive

osteoclasts increased dramatically with aging in IDH2-deficient mice, and at 47 weeks, there were noticeably more TRAP-positive osteoclasts in IDH2-deficient mice compared with controls (Fig. 4C). In contrast, von Kossa staining revealed that osteoblast activity was

higher in control mice than in IDH2-deficient mice (Fig. 4D). Taken together, IDH2-deficient mice show high levels of osteoclast activity but low osteoblast activity, resulting in loss of bone mass and the formation of bone abnormalities.

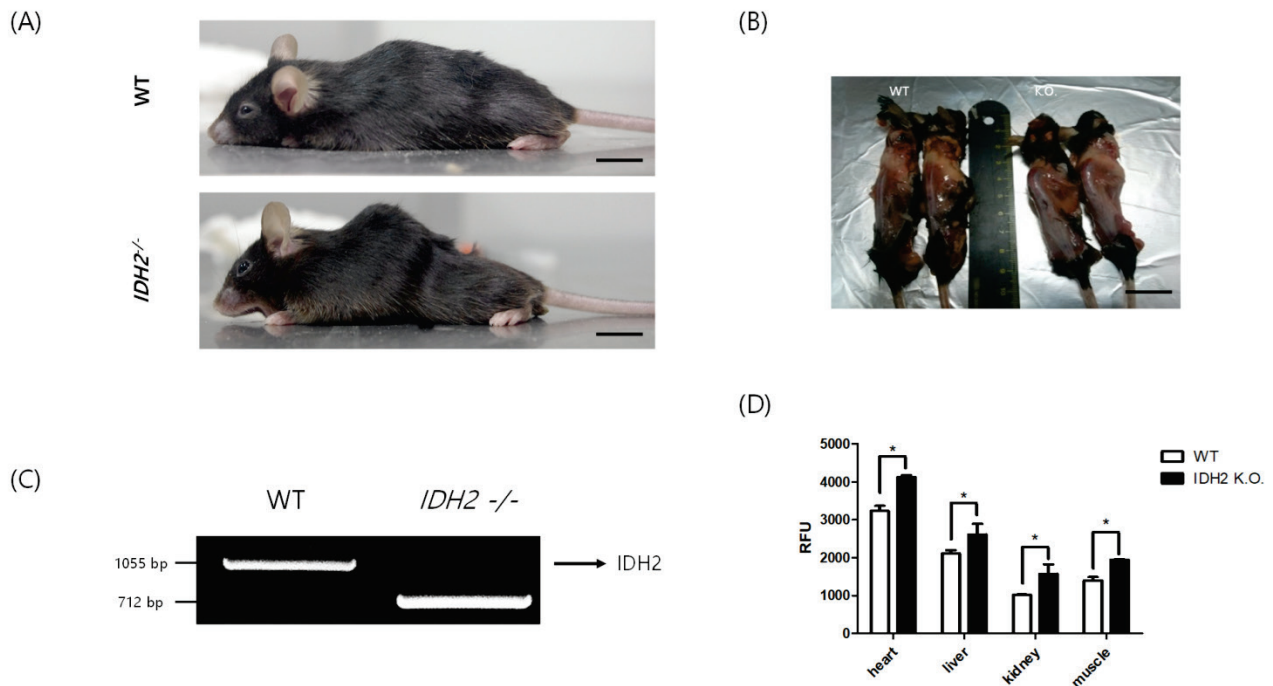


Fig. 1. Gross morphology of spinal deformities in IDH2-deficient mice. **(A)** Lateral view of 47-week-old IDH2^{+/+} (WT) and IDH2^{-/-} littermates, showing kyphosis in the IDH2^{-/-} mice. Scale bars represent 10 mm. **(B)** Dorsal view of 47-week-old IDH2^{+/+} (WT) and IDH2^{-/-} littermates, showing kyphosis in the IDH2^{-/-} mice. Scale bars represent 5 mm. **(C)** Genotyping of IDH2^{+/+} (WT) and IDH2^{-/-} mice. DNA was extracted from the tails and amplified by PCR. Arrow indicates the size of the expected IDH2 PCR product. **(D)** Relative ROS level was detected in heart, liver, kidney and muscle *via* assay kit. The level of ROS was indicated in relative fluorescence units (RFU). Data are expressed as means \pm SD ($n=3$). * $p < 0.05$, ** $p < 0.01$, and *** $p < 0.001$.

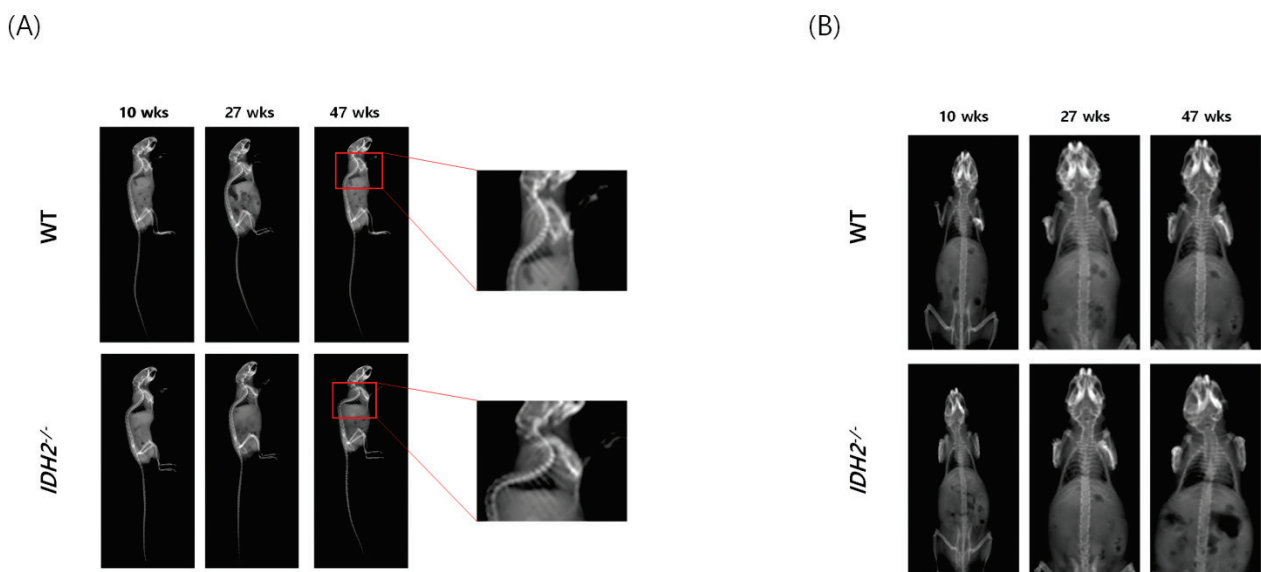


Fig. 2. X-ray assessment of spinal abnormalities in IDH2-deficient mice. **(A)** Lateral X-ray views of WT and IDH2^{-/-} mice at 10, 27, and 47 weeks. **(B)** Dorsal X-ray views of WT and IDH2^{-/-} mice at 10, 27, and 47 weeks ($n=6$ /group).

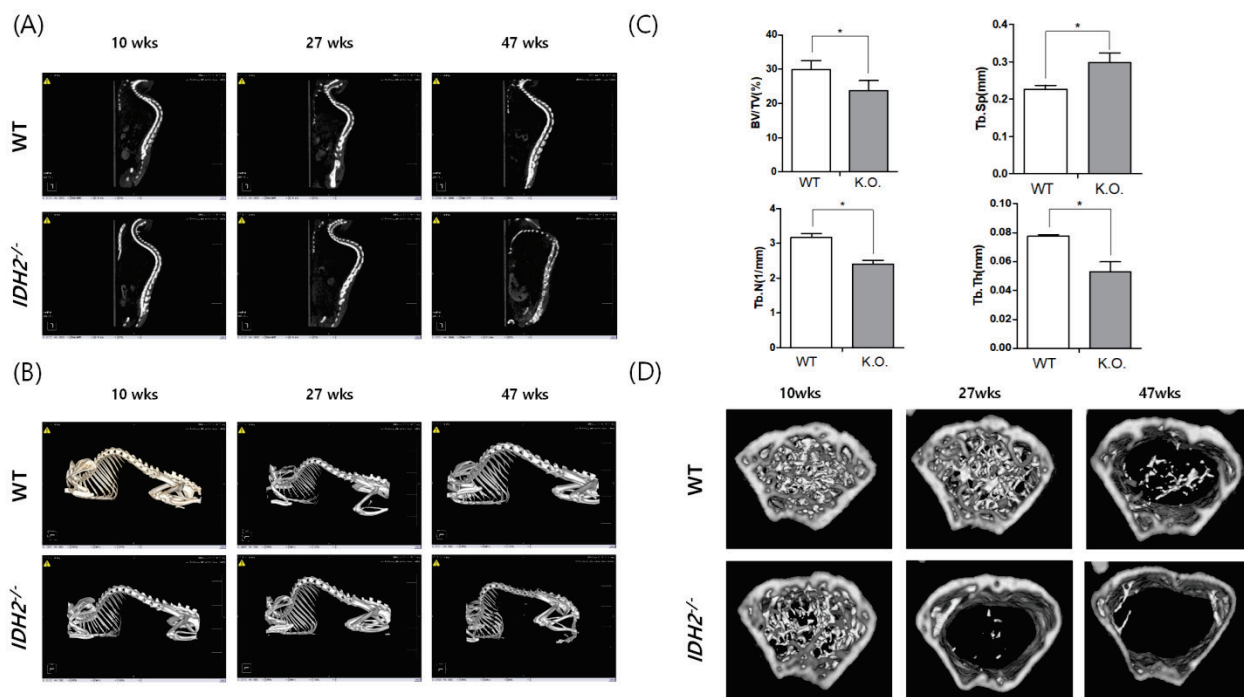


Fig. 3. Micro-CT analysis of spinal abnormalities in IDH2-deficient mice. **(A)** Lateral micro-CT views of WT and IDH2^{-/-} mice at 10, 27, and 47 weeks (n=6/group). **(B)** 3D reconstructions of micro-CT images of WT and IDH2^{-/-} mice. **(C)** Effects of IDH2-deficiency on standard parameters of bone loss. Trabecular bone volume/tissue volume (BV/TV), trabecular separation (Tb.Sp), trabecular thickness (Tb.Th), and trabecular number (Tb.N) were measured in 47-week-old wild type and IDH2-deficient mice. **(D)** Trabecular bone from WT and IDH2^{-/-} mice at each age was 3D reconstructed. Data are expressed as means ± SD (n=3). * $p < 0.05$, ** $p < 0.01$, and *** $p < 0.001$.

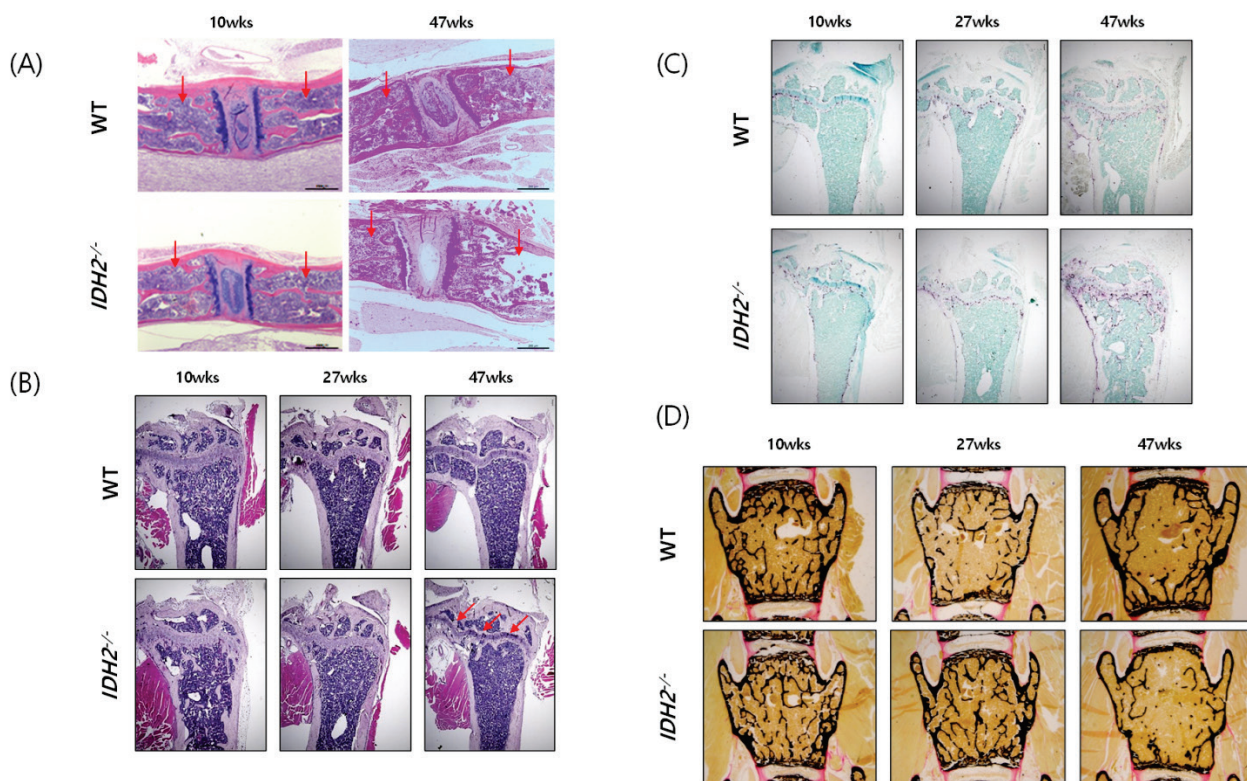


Fig. 4. Histologic analysis of IDH2-deficient mice. **(A)** Representative H&E-stained sections from WT and IDH2^{-/-} spinal tissue. At 47 weeks, the lumbar discs of the spines show partial collapse in the IDH2^{-/-} mice (n=6/group). Arrowheads indicated vertebral bodies. **(B)** H&E-stained sections of spongy bone and membrane bone. Note that the border between spongy and membrane bone becomes unclear (arrowheads) in an age-dependent manner (n=6/group). **(C)** TRAP staining in the tibias of WT and IDH2^{-/-} mice. There was no significant difference in the osteoclast population (red staining) until 27 weeks (n=6/group). At 47 weeks, IDH2^{-/-} mice displayed decreased osteoclasts. **(D)** Von Kossa staining of spinal tissue from WT and IDH2^{-/-} mice also showed no differences at 27 weeks, but there are decreased osteoblasts (black staining) in IDH2^{-/-} mice at 47 weeks (n=6/group).

Discussion

Kyphosis is characterized by abnormally excessive curvature in the cervical, thoracic, and sacral regions of spine. There are many causes of kyphosis, such as osteoporosis, disk degeneration, Scheuermann's disease, cancer, and certain cancer treatments. However, there are genetic causes of kyphosis as well, as infants can be born with kyphosis. Previous studies suggest that deletion of specific genes can lead to spinal deformities such as those seen in kyphosis (Juneja *et al.* 2014). Recently, several studies have suggested that the mitochondrial oxidative decarboxylase IDH2 can affect bone diseases. Mutations in IDH2 can result in a novel activity for the enzyme – the production of 2-hydroxyglutarate (2-HG), which can block osteoblast differentiation (Kato Kaneko *et al.* 2014). IDH2 mutation also associated with formation of enchondromas and chondrosarcomas. IDH2 mutation is frequently occurred in cartilaginous tumors like as enchondromas leads to Ollier disease and Maffucci syndrome (Pansuriya *et al.* 2011). In chondrosarcomas, IDH2 R172 mutations also detected frequently more than another genetic abnormalities (Amary *et al.* 2011). Furthermore, abnormal IDH2 function cannot regulate redox balance against oxidative damage (Kim *et al.* 2014), and this deregulation can induce many diseases, including musculoskeletal diseases (Wauquier *et al.* 2009). Therefore, dysfunction of IDH2 could be closely connected to bone diseases. However, the precise effects of IDH2 on bone have not been elucidated. In the present study, we investigated the roles of IDH2 in bone formation and maintenance using IDH2-deficient mice. Our results suggest that IDH2 has an important role in the maintenance of bone structures.

We report for the first time that IDH2-deficient mice develop spinal deformities at a higher rate than control mice. Like other knockout mice that have noticeable abnormalities in morphology (Kim *et al.* 2013), the noticeable curvature of the spines of IDH2-deficient mice visible with the naked eye was due to degenerative vertebrate modifications and kyphosis. X-ray assessment indicated marked curvature in IDH2-deficient mice at 47 weeks on lateral view. Micro-CT images of L4 vertebrae of control and IDH2-deficient mice show a clear difference from the cervical vertebrae to the thoracic in the IDH2-deficient mice. There were no differences of bone components between control and IDH2-deficient mice at 10 weeks,

but from 27 weeks on, the bone components of IDH2-deficient mice deteriorate much more rapidly than those of control mice. As a result, age-dependent kyphosis (Katzman *et al.* 2010) is accelerated in the absence of IDH2.

To date, a direct role for IDH2 in bone had not yet been described. Here, we use H&E, TRAP, and von Kossa staining (Gao *et al.* 2015, Mushahary *et al.* 2016, Hayer *et al.* 2005) to identify histological changes between wild type and IDH2-deficient mice, providing the first ever link between IDH2 and the regulation of osteoclasts and osteoblasts. We found that osteopenia was more advanced in the spines of IDH2-deficient mice than in control mice. Furthermore, spongy and membrane bones of IDH2-deficient mice were so disorganized that the border between spongy and membrane bone became difficult to recognize. The results suggest that IDH2 has an important role in maintaining bone during aging. Furthermore, we studied the direct cause of bone loss in IDH2-deficient mice through TRAP and von Kossa staining, which were used to detect osteoclasts and osteoblasts, respectively (Lutter *et al.* 2010). The results demonstrate that accelerated bone loss in IDH2-deficient mice is due to the presence of increased osteoclasts and decreased osteoblasts, suggesting that IDH2 is important for the regulation osteoclast/osteoblast homeostasis. Homeostasis of bone resorption by osteoclast and bone formation by osteoblast is important for maintaining bone structure (Tanaka *et al.* 2005). Dysregulation of osteoclast and osteoblast can lead to abnormality of bone remodeling. Degeneration of bone remodeling function can induce osteoporosis and various diseases of bone metabolism (Feng and McDonald 2011). Furthermore, previous study already suggested that bone turnover is associated with kyphosis (McDaniels-Davidson *et al.* 2016). As a result, we can hypothesize imbalance in bone turnover by dysregulation of osteoclast and osteoblast can lead to kyphosis.

In this study, we found that IDH2-deficient mice displayed accelerated development of spine abnormalities with aging, presumably due to deregulation of the balance between osteoclasts and osteoblasts and consequent deregulation of bone resorption. In IDH2-deficient mice, all of our data indicate faster bone loss and increased formation of bone abnormalities compared to control mice. This striking phenotype implies that the regulation of osteoclast/osteoblast homeostasis is highly important during aging. While more study is needed to fully understand the relationship between IDH2 and aging, we

predict that IDH2 plays a critical role in bone-related aging, and may affect several bone disorders, including osteoporosis and kyphosis. Therefore, IDH2 knockout mice are a promising mouse model for the study of age-related bone disorders like osteoporosis and kyphosis. In addition, IDH2 may represent an attractive target for the treatment of spinal deformity diseases.

Conflict of Interest

There is no conflict of interest.

Acknowledgements

This research was supported by grants from the National Research Foundation of Korea, Republic of Korea (NRF-2015R1A4A1042271, NRF-2017R1A2B4008176, NRF-2017R1A5A2015391), from the Korea Research Institute of Bioscience & Biotechnology (KRIBB) Research Initiative Program (KGM4611821) and from the government working for dog production technology development (Project No. PJ01179202), Rural Development Administration, Republic of Korea. We gratefully acknowledge Korea Mouse Phenotyping Center (KMPC) for technical support of mouse phenotyping.

References

- AMARY MF, BACSI K, MAGGIANI F, DAMATO S, HALAI D, BERISHA F, POLLOCK R, O'DONNELL P, GRIGORIADIS A, DISS T, ESKANDARPOUR M, PRESNEAU N, HOGENDOORN PCW, FUTREAL A, TIRABOSCO R, FLANAGAN AM: IDH1 and IDH2 mutations are frequent events in central chondrosarcoma and central and periosteal chondromas but not in other mesenchymal tumours. *J Pathol* **224**: 334-343, 2011.
- BANFI G, IORIO EL, CORSI MM: Oxidative stress, free radicals and bone remodeling. *Clin Chem Lab Med* **46**: 1550-1555, 2008.
- BASU S, MICHAELSSON K, OLOFSSON H, JOHANSSON S, MELHUS H: Association between oxidative stress and bone mineral density. *Biochem Biophys Res Commun* **288**: 275-279, 2001.
- BOUXSEIN ML, BOYD SK, CHRISTIANSEN BA, GULDBERG RE, JEPSEN KJ, MULLER R: Guidelines for assessment of bone microstructure in rodents using micro-computed tomography. *J Bone Miner Res* **25**: 1468-1486, 2010.
- ERBEN RG: Embedding of bone samples in methylmethacrylate: an improved method suitable for bone histomorphometry, histochemistry, and immunohistochemistry. *J Histochem Cytochem* **45**: 307-313, 1997.
- FATHI AT, SADRZADEH H, COMANDER AH, HIGGINS MJ, BARDIA A, PERRY A, BURKE M, SILVER R, MARTULIS CR, STRALEY KS, YEN KE, AGRESTA S, KIM H, SCHENKEIN DP, BORGER DR: Isocitrate dehydrogenase 1 (IDH1) mutation in breast adenocarcinoma is associated with elevated levels of serum and urine 2-hydroxyglutarate. *Oncologist* **19**: 602-607, 2014.
- FENG X, McDONALD JM: Disorders of bone remodeling. *Annu Rev Pathol* **6**: 121-145, 2011.
- GAO C, CHEN BP, SULLIVAN MB, HUI J, OUELLET JA, HENDERSON JE, SARAN N: Micro CT Analysis of spine architecture in a mouse model of scoliosis. *Front Endocrinol (Lausanne)* **6**: 38, 2015.
- GHIAM AF, CAIRNS RA, THOMS J, DAL PRA A, AHMED O, MENG A, MAK TW, BRISTOW RG: IDH mutation status in prostate cancer. *Oncogene* **31**: 3826, 2012.
- HAYER S, STEINER G, GORTZ B, REITER E, TOHIDAST-AKRAD M, AMLING M, HOFFMANN O, REDLICH K, ZWERINA J, SKRINER K, HILBERG F, WAGNER EF, SMOLEN JS, SCHETT G: CD44 is a determinant of inflammatory bone loss. *J Exp Med* **201**: 903-914, 2005.
- ITO K, IMAGAMA S, ITO Z, ANDO K, KOBAYASHI K, HIDA T, TSUSHIMA M, ISHIKAWA Y, MATSUMOTO A, NISHIDA Y, ISHIQURO N: Analysis of cervical kyphosis and spinal balance in young idiopathic scoliosis patients classified by the apex of thoracic kyphosis. *Eur Spine J* **25**: 3220-3225, 2016.
- JO SH, SON MK, KOH HJ, LEE SM, SONG IH, KIM YO, LEE YS, JEONG KS, KIM WB, PARK JW, SONG BJ, HUH TL: Control of mitochondrial redox balance and cellular defense against oxidative damage by mitochondrial NADP⁺-dependent isocitrate dehydrogenase. *J Biol Chem* **276**: 16168-16176, 2001.
- JUNEJA SC, VONICA A, ZEISS C, LEZON-GEYDA K, YATSULA B, SELL DR, MONNIER VM, LIN S, ARDITO T, EYRE D, REYNOLDS D, YAO Z, AWAD HA, YU H, WILSON M, HONNONS S, BOYCE BF, XING L, ZHANG Y, PERKINS AS: Deletion of Mecom in mouse results in early-onset spinal deformity and osteopenia. *Bone* **60**: 148-161, 2014.

- KATO KANEKO M, LIU X, OKI H, OQASAWARA S, NAKAMURA T, SAIDOH N, TSUJIMOTO Y, MATSUYAMA Y, URUNO A, SUQAWARA M, TSUCHIYA T, YAMAKAWA M, YAMAMOTO M, TAKAGI M, KATO Y: Isocitrate dehydrogenase mutation is frequently observed in giant cell tumor of bone. *Cancer Sci* **105**: 744-748, 2014.
- KATZMAN WB, WANEK L, SHEPHERD JA, SELLMAYER DE: Age-related hyperkyphosis: its causes, consequences, and management. *J Orthop Sports Phys Ther* **40**: 352-360, 2010.
- KIM H, KIM SH, CHA H, KIM SR, LEE JH, PARK JW: IDH2 deficiency promotes mitochondrial dysfunction and dopaminergic neurotoxicity: implications for Parkinson's disease. *Free Radic Res* **50**: 853-860, 2016.
- KIM HK, ARUWAJOYE O, SUCATO D, RICHARDS BS, FENG GS, CHEN D, KING PD, KAMIYA N: Induction of SHP2 deficiency in chondrocytes causes severe scoliosis and kyphosis in mice. *Spine (Phila Pa 1976)* **38**: E1307-E1312, 2013.
- KIM S, KIM SY, KU HJ, JEON YH, LEE HW, LEE J, KWON TK, PARK KM, PARK JW: Suppression of tumorigenesis in mitochondrial NADP(+)-dependent isocitrate dehydrogenase knock-out mice. *Biochim Biophys Acta* **1842**: 135-143, 2014.
- KU HJ, AHN Y, LEE JH, PARK KM, PARK JW: IDH2 deficiency promotes mitochondrial dysfunction and cardiac hypertrophy in mice. *Free Radic Biol Med* **80**: 84-92, 2015.
- LOESER RF: Age-related changes in the musculoskeletal system and the development of osteoarthritis. *Clin Geriatr Med* **26**: 371-386, 2010.
- LUTTER AH, HEMPEL U, WOLF-BRANDSTETTER C, GARBE AI, GOETTSCHE C, HOFBAUER LC, JESSBERGER R, DIETER P: A novel resorption assay for osteoclast functionality based on an osteoblast-derived native extracellular matrix. *J Cell Biochem* **109**: 1025-1032, 2010.
- MCDANIELS-DAVIDSON CR, KRITZ-SILVERSTEIN D, HUANG MH, LAUGHLIN GA, JOHNSON S, HAAPALAHTI J, SCHNEIDER DL, BARRETT-CONNOR E, KADO DM: The association between bone turnover markers and kyphosis in community-dwelling older adults. *Bone Rep* **5**: 57-61, 2016.
- MEGOVA M, DRABEK J, KOUDELAKOVA V, TROJANEC R, KALITA O, HAJDUCH M: Isocitrate dehydrogenase 1 and 2 mutations in gliomas. *J Neurosci Res* **92**: 1611-1620, 2014.
- MUSHAHARY D, WEN C, KUMAR JM, SRAVANTHI R, HODGSON P, PANDE G, LI Y: Strontium content and collagen-I coating of Magnesium-Zirconia-Strontium implants influence osteogenesis and bone resorption. *Clin Oral Implants Res* **27**: e15-e24, 2016.
- PANSURIYA TC, VAN EIJK R, D'ADAMO P, VAN RULER MA, KUIJER ML, OOSTING J, CLETON-JANSEN AM, VAN OOSTERWIJK JG, VERBEKE SL, MEIJER D, VAN WEZEL T, NORD KH, SANGIORGI L, TOKER B, LIEGL-ATZWANGER B, SAN-JULIAN M, SCIOT R, LIMAYE N, KINDBLOM LG, DAUGAARD S, GODFRAIND C, BOON LM, VIKKULA M, KUREK KC, SZUHAI K, FRENCH PJ, BOVÉE JV: Somatic mosaic IDH1 and IDH2 mutations are associated with enchondroma and spindle cell hemangioma in Ollier disease and Maffucci syndrome. *Nat Genet* **43**: 1256-1261, 2011.
- RAKHEJA D, KONOPLEV S, MEDEIROS LJ, CHEN W: IDH mutations in acute myeloid leukemia. *Hum Pathol* **43**: 1541-1551, 2012.
- REITMAN ZJ, PARSONS DW, YAN H: IDH1 and IDH2: not your typical oncogenes. *Cancer Cell* **17**: 215-216, 2010.
- SMOLKOVA K, JEZEK P: The role of mitochondrial NADPH-dependent isocitrate dehydrogenase in cancer cells. *Int J Cell Biol* **2012**: 273947, 2012.
- TANAKA Y, NAKAYAMADA S, OKADA Y: Osteoblasts and osteoclasts in bone remodeling and inflammation. *Curr Drug Targets Inflamm Allergy* **4**: 325-328, 2005.
- WAUQUIER F, LEOTOING L, COXAM V, GUICHEUX J, WITTRANT Y: Oxidative stress in bone remodelling and disease. *Trends Mol Med* **15**: 468-477, 2009.
- YU W, DITTENHAFFER-REED KE, DENU JM: SIRT3 protein deacetylates isocitrate dehydrogenase 2 (IDH2) and regulates mitochondrial redox status. *J Biol Chem* **287**: 14078-14086, 2012.