

The Temporal and Spatial Effects of Reconstructive Surgery on the Atrophy of Hindlimb Muscles in Anterior Cruciate Ligament Transected Rats

Akinori KANEGUCHI¹, Junya OZAWA¹, Kengo MINAMIMOTO², Kaoru YAMAOKA¹

¹Department of Rehabilitation, Faculty of Rehabilitation, Hiroshima International University, Higashi-Hiroshima, Hiroshima, Japan, ²Major in Medical Engineering and Technology, Graduate School of Medical Technology and Health Welfare Sciences, Hiroshima International University, Higashi-Hiroshima, Hiroshima, Japan

Received March 25, 2022

Accepted October 27, 2022

Epub Ahead of Print December 22, 2022

Summary

After anterior cruciate ligament (ACL) injury, a decrease in muscle strength associated with muscle atrophy is frequently observed. The temporal and spatial effects of reconstructive surgery on muscle atrophy have not been examined in detail. This study aimed to 1) reveal the short and mid-term effects of reconstructive surgery on muscle atrophy, and 2) investigate the differences in the degree of atrophy after ACL reconstruction in the hindlimb muscles. ACL transection with or without reconstructive surgery was performed unilaterally on the knees of rats. Untreated rats were used as controls. At one or four weeks post-surgery, the relative muscle wet weights (wet weight/body weight) of the hindlimb muscles were calculated to assess atrophy. At one week post-surgery, muscle atrophy was induced by ACL transection and further aggravated by reconstructive surgery. Reconstructive surgery facilitated recovery from muscle atrophy in some muscles compared with those without reconstructive surgery (ACL transection alone) at four weeks post-surgery. Muscle atrophy after ACL reconstruction was greater in the rectus femoris and plantar flexors than in the semitendinosus and plantar extensors at one week post-surgery. These results indicate that reconstructive surgery exacerbates muscle atrophy in the first week post-surgery, while facilitating recovery between the first and fourth week post-surgery. After reconstructive surgery, muscle atrophy was observed not only in the quadriceps and hamstrings, but also in the lower leg muscles, suggesting the need for muscle strengthening interventions for the lower leg muscles as well as the quadriceps and hamstrings.

Key words

ACL injury • ACL reconstruction • Arthrogenic muscle inhibition • Disuse • Muscle atrophy

Corresponding author

J. Ozawa, Department of Rehabilitation, Faculty of Rehabilitation, Hiroshima International University, Kurose-Gakuendai 555-36, Higashi-Hiroshima, Hiroshima, 739-2695, Japan. E-mail: j-ozawa@hirokoku-u.ac.jp

Introduction

Anterior cruciate ligament (ACL) injury is one of the most common sport-induced injuries [1]. After ACL injury, a decrease in muscle strength associated with muscle atrophy is frequently observed [2,3]. Because this decrease in muscle strength is related to poor functional outcomes and may contribute to the development of osteoarthritis [2], prevention and/or improvement of muscle atrophy are considered critical issues in patients with ACL injury.

The gold standard for treatment of ACL injury is reconstructive surgery. Previous studies have reported muscle atrophy in the early post-operative stage [4,5]. Yang *et al.* reported a significant decrease in thickness of the quadriceps muscles, measured by ultrasound, in the first seven days after surgery compared to pre-operatively [4]. Similarly, Lee *et al.* reported a significantly thinner vastus intermedius measured by ultrasound two to three

days after reconstructive surgery, compared with pre-operatively [5]. In summary, these studies provide evidence that reconstructive surgery amplifies muscle atrophy in the early post-operative stages.

As to the middle- and long-term effects of reconstructive surgery on skeletal muscles, Ageberg *et al.* reported no differences in knee extensor and flexor muscle strengths between patients with or without reconstructive surgery two to five years after ACL injury [6]. On the contrary, studies have reported improved knee flexor muscle strength two years or more after ACL injury when cases were treated with reconstructive surgery compared with cases without reconstructive surgery [7,8]. Thus, reconstructive surgery may have no negative effects on muscle weakness recovery in the middle- to long-term, but this possibility has not been examined in detail.

It is well known that muscle atrophy and decreased muscle strength after ACL reconstruction is more prominent in the quadriceps than in the hamstrings [9-11]. Decreased muscle strength after ACL reconstruction is observed also in the ankle planter flexors and extensors [12]. However, whether muscle atrophy develops in the lower leg muscles after ACL reconstruction has not been well studied. In ACL injury models, muscle atrophy has been observed in the lower leg muscles, such as the extensor digitorum longus (EDL), tibialis anterior (TA), gastrocnemius (GC), and soleus (SOL), as well as in the quadriceps and hamstrings [13-17]. Moreover, muscle atrophy in the lower leg muscles has been detected in knee arthritis models [18,19]. Based on these reports, we consider that ACL reconstruction may induce muscle atrophy not only in the quadriceps and hamstrings, but also in the lower leg muscles. If so, muscle strengthening interventions for the lower leg muscles, as well as the quadriceps and hamstrings, may be needed after ACL reconstructive surgery.

The aims of this study were to 1) reveal the short- and mid-term effects of reconstructive surgery on hindlimb muscles, and 2) investigate the differences in the degree of atrophy after ACL reconstruction in the hindlimb muscles. To achieve these goals, we comprehensively examined changes in the muscle wet weights in the hindlimb muscles between one and four weeks after ACL transection with or without reconstructive surgery in rats.

Methods

Experimental animals

A schematic diagram of the experimental protocol is shown in Figure 1. Fifty male Wistar rats (8 weeks old; Japan SLC, Shizuoka, Japan) were used in this study. Rats were randomly divided into control (n=8), sham (n=13), ACL transection (ACLT; n=14), and ACL reconstruction (ACLR; n=15) groups. Rats were sacrificed at one or four weeks post-surgery to assess muscle atrophy (n=6-8/group/time point, Fig. 1). Rats in the control group were sacrificed at nine or twelve weeks of age to produce age-matched controls (n=4/time point). In the control group, right and left hindlimbs were used as individual samples. Therefore, eight hindlimbs from four control rats were used at each time point (Fig. 1). Rats were housed in standard cages in a temperature-controlled room (20-25 °C) with a 12 h light/dark cycle. Standard rodent chow and water were provided *ad libitum*. This experimental design was approved by the animal experimentation committee of Hiroshima International University.

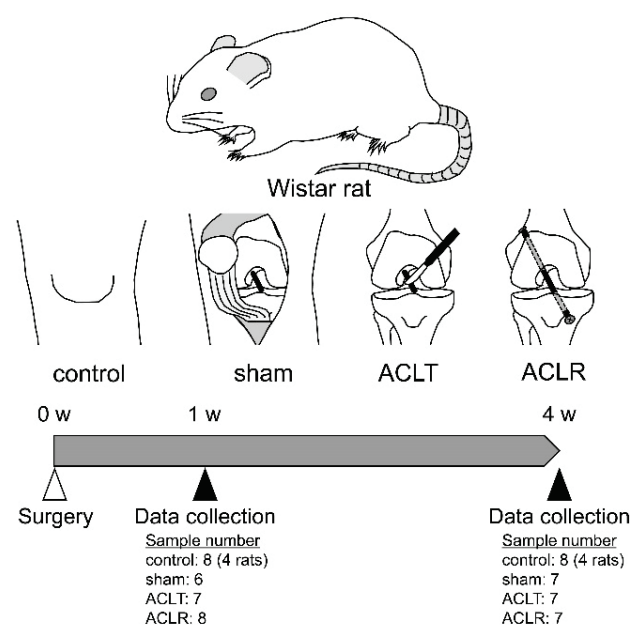


Fig. 1. Experimental protocol design. ACLT, anterior cruciate ligament transection; ACLR, anterior cruciate ligament reconstruction.

Knee surgery

Except for the control group, rats received knee surgery on the right knee using the methods described in previous studies [20,21]. In brief, rats were anesthetized

with an intraperitoneal injection of ketamine (80 mg/kg) and xylazine (10 mg/kg). The knee joint was opened *via* a medial parapatellar approach. The joint capsule and skin of rats in the sham group were sutured. For rats in the ACLT and ACLR groups, the ACL was transected using a surgical knife. The joint capsule and skin of the rats in the ACLT group were sutured. Rats in the ACLR group had bone tunnels from the antero-medial side of the proximal tibia to the lateral side of the distal femur made using a 0.8 mm diameter Kirschner wire. A quadruple-bundle tail tendon autograft was prepared and inserted through the bone tunnels, with both ends fixed to the bones with stainless steel interference screws (0.8 mm diameter and 2.0 mm length, TE-00001; Matsumoto, Chiba, Japan). Finally, the joint capsule and skin were sutured. Rats in the control group were left untreated. After surgery, rats could move freely in the cage without any intervention.

Measurement of body and muscle wet weight

At the end of the experimental period, rats were anesthetized by inhaled diethyl ether, and body weight was measured. Rats were sacrificed by exsanguination under anesthesia. The rectus femoris (RF), semitendinosus (ST), GC, SOL, plantaris (PL), TA, and EDL, which are easily isolated hindlimb muscles, were then sampled and the wet weights of these muscles were measured using an electronic balance (GX-200; A&D, Tokyo, Japan). To correct for differences in body size, relative muscle wet weights (muscle wet weight/body weight) were calculated and used as an index of muscle atrophy. In addition, the percent of atrophy of each muscle in the ACLR group was calculated using the following formula: percent of atrophy = $(1 - \text{relative muscle wet weight in the ACLR group} / \text{mean relative muscle wet weight in the control group}) * 100$.

Measurement of muscle fiber cross sectional area

After measurement of wet weight, the RF was frozen in isopentane cooled by liquid nitrogen. Transverse sections (10- μm -thick) were then cut from the mid-belly portion using a cryostat and were stained with hematoxylin and eosin. The central region of each section was photographed at 10 \times magnification, and cross-sectional area (CSA) of randomly selected more than 100 muscle fibers were manually measured using ImageJ software (National Institutes of Health, Bethesda, MD, USA). Finally, relative muscle fiber CSA (muscle fiber CSA/body weight) was calculated, because muscle fiber CSA is affected by body size [22].

Statistical analysis

Data are expressed as mean \pm standard deviation. Statistical analyses were performed using Dr. SPSS II for Windows (SPSS Japan Inc., Tokyo, Japan). For body weight, relative muscle wet weight, relative muscle fiber CSA, and percent of atrophy, two-way analysis of variance (ANOVA) was applied. If significant main or interaction effects were detected, *post hoc* Bonferroni tests were performed to localize the effects. After assumption of normality was checked using Kolmogorov-Smirnov test, the Pearson's correlation coefficient was calculated between relative muscle wet weight and relative muscle fiber CSA of the RF. A *P*-value of <0.05 was considered statistically significant.

Results

Body weight

At one week post-surgery, body weights in the control, sham, ACLT, and ACLR groups were 232 \pm 11, 239 \pm 6, 222 \pm 7, and 206 \pm 11 g, respectively (Fig. 2). Compared with the sham group, body weight in the ACLT group was significantly lower ($P=0.024$). Body weight in the ACLR group was significantly lower than in the control, sham, and ACLT groups ($P\leq 0.025$). At four weeks post-surgery, body weights in the control, sham, ACLT, and ACLR groups were 296 \pm 9, 288 \pm 9, 300 \pm 14, and 273 \pm 11 g, respectively (Fig. 2). For all groups, body weight at four weeks post-surgery was significantly higher than at one week post-surgery ($P<0.001$). Body weight in the ACLR group was significantly lower than in the control and ACLT groups ($P\leq 0.006$).

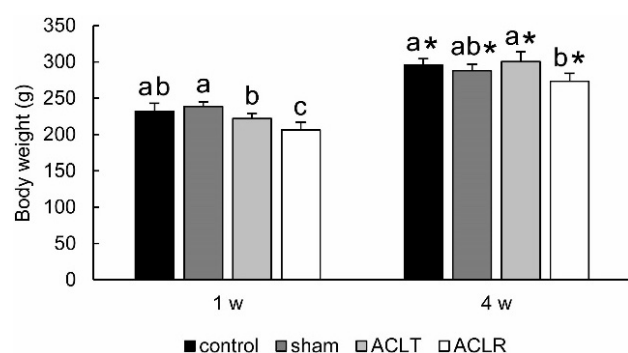


Fig. 2. Body weight. Values are expressed as mean \pm standard deviation. Different letters indicate statistically significant differences between groups at the same time point, such that groups not sharing the same letter are significantly different from one another. *: significant difference compared with one week post-surgery. ACLT, anterior cruciate ligament transection; ACLR, anterior cruciate ligament reconstruction.

Muscle wet weight

At one week post-surgery, the relative wet weights of the RF in the sham, ACLT, and ACLR groups were significantly lower than in the control group (Fig. 3A, $P < 0.001$). Compared with the sham group, the relative wet weights of the RF in the ACLT and ACLR groups were significantly lower ($P < 0.001$). Between the ACLT and ACLR groups, the relative wet weight of the RF was significantly lower in the ACLR group ($P = 0.020$). At four weeks post-surgery, the relative wet weights of the RF in the sham, ACLT, and ACLR groups were significantly higher than at one week post-surgery ($P < 0.001$). Compared with the control and sham groups, the relative wet weight of the RF was significantly lower in the ACLT group ($P \leq 0.009$), but not in the ACLR group ($P \geq 0.477$). There was no significant difference in the relative wet weight of the RF between the ACLT and ACLR groups at four weeks post-surgery ($P = 0.175$).

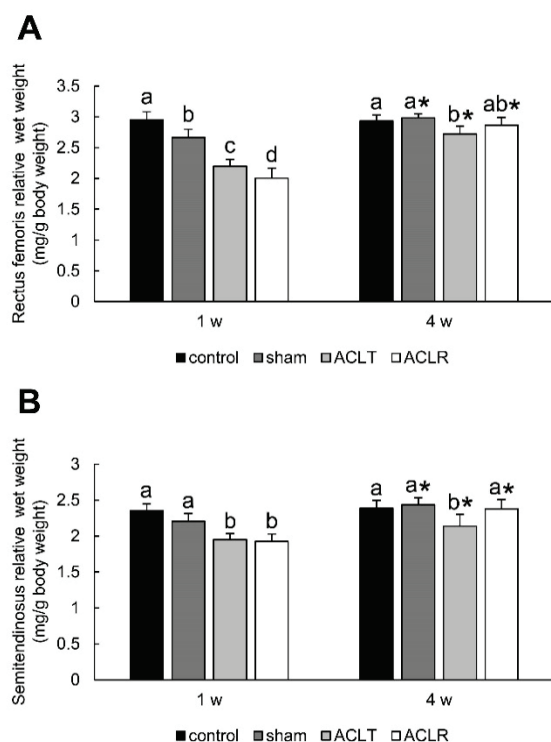


Fig. 3. Relative muscle wet weight of the thigh muscles. (A) Rectus femoris and (B) semitendinosus. Values are expressed as mean \pm standard deviation. Different letters indicate statistically significant differences between groups at the same time point, such that groups not sharing the same letter are significantly different from one another. *: significant difference compared with one week post-surgery. ACLT, anterior cruciate ligament transection; ACLR, anterior cruciate ligament reconstruction.

At one week post-surgery, the relative wet weights of the ST in the ACLT and ACLR groups were significantly lower than those in the control and sham

groups (Fig. 3B, $P \leq 0.001$). There was no significant difference in the relative wet weight of the ST between the ACLT and ACLR groups at one week post-surgery ($P = 1.000$). At four weeks post-surgery, the relative wet weights of the ST in the sham, ACLT, and ACLR groups were significantly higher than at one week post-surgery ($P \leq 0.003$). The relative wet weight of the ST in the ACLT group was significantly lower than in the control and sham groups ($P \leq 0.001$). In the ACLR group, the relative wet weight of the ST was significantly higher than in the ACLT group ($P = 0.002$) and was comparable to the control and sham groups ($P = 1.000$).

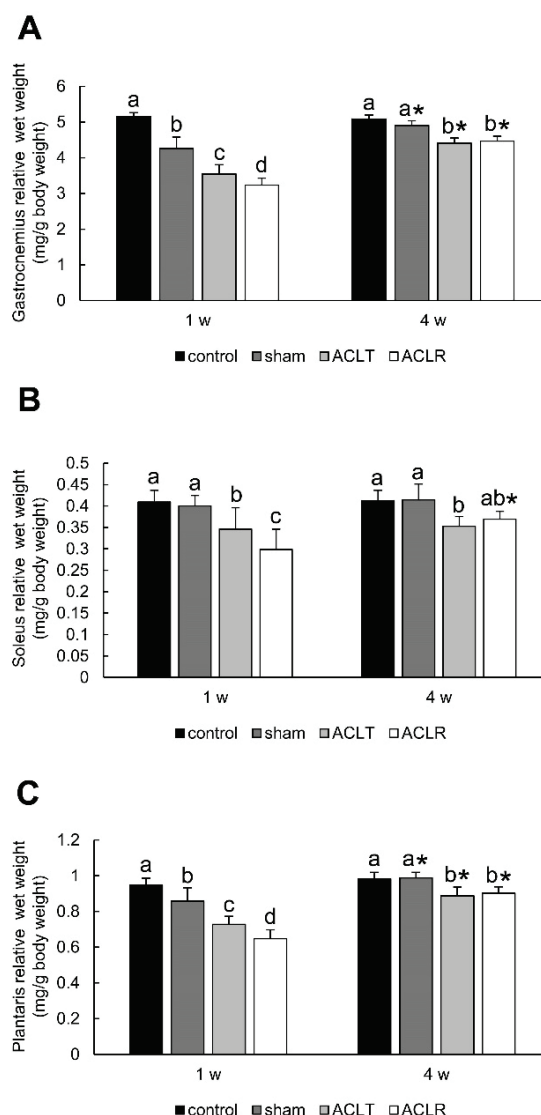


Fig. 4. Relative muscle wet weight of the plantar flexors. (A) Gastrocnemius, (B) soleus, and (C) plantaris. Values are expressed as mean \pm standard deviation. Different letters indicate statistically significant differences between groups at the same time point, such that groups not sharing the same letter are significantly different from one another. *: significant difference compared with one week post-surgery. ACLT, anterior cruciate ligament transection; ACLR, anterior cruciate ligament reconstruction.

At one week post-surgery, the relative wet weights of the GC in the sham, ACLT, and ACLR groups were significantly lower than in the control group (Fig. 4A, $P<0.001$). Among operated groups, the relative wet weights of the GC in the ACLT and ACLR groups were significantly lower than in the sham group ($P<0.001$). Between the ACLT and ACLR groups, the relative wet weight of the GC was significantly lower in the ACLR group ($P=0.013$). At four weeks post-surgery, the relative wet weights of the GC in the sham, ACLT, and ACLR groups were significantly higher than at one week post-surgery ($P<0.001$). Compared with the control and sham groups, the relative wet weights of the GC in the ACLT and ACLR groups were significantly lower ($P<0.001$). There was no significant difference in the relative wet weight of the GC between the ACLT and ACLR groups at four weeks post-surgery ($P=1.000$).

At one week post-surgery, the relative wet weights of the SOL in the ACLT and ACLR groups were significantly lower than in the control and sham groups (Fig. 4B, $P\leq 0.032$). Between the ACLT and ACLR groups, the relative wet weight of the SOL was significantly lower in the ACLR group ($P=0.049$). At four weeks post-surgery, the relative wet weight of the SOL in the ACLR group was significantly higher than at one week post-surgery ($P<0.001$). Compared with the control and sham groups, the relative wet weight of the SOL was significantly lower in the ACLT group ($P=0.007$), but not in the ACLR group ($P\geq 0.096$). There was no significant difference in the relative wet weight of the SOL between the ACLT and ACLR groups at four weeks post-surgery ($P=1.000$).

At one week post-surgery, the relative wet weights of the PL in the sham, ACLT, and ACLR groups were significantly lower than in the control group (Fig. 4C, $P\leq 0.005$). Compared with the sham group, the relative wet weights of the PL in the ACLT and ACLR groups were significantly lower ($P<0.001$). The relative wet weight of the PL in the ACLR group was significantly lower than in the ACLT group ($P=0.009$). At four weeks post-surgery, the relative wet weights of the PL in the sham, ACLT, and ACLR groups were significantly higher than at one week post-surgery ($P<0.001$). The relative wet weights of the PL in the ACLT and ACLR groups were significantly lower than in the control and sham groups ($P\leq 0.009$). There was no significant difference in the relative wet weight of the PL between the ACLT and ACLR groups at four weeks post-surgery ($P=1.000$).

At one week post-surgery, the relative wet weights of the TA in the sham, ACLT, and ACLR groups were significantly lower than in the control group (Fig. 5A, $P<0.001$). Compared with the sham group, the relative wet weights of the TA in the ACLT and ACLR groups were significantly lower ($P\leq 0.001$). Between the ACLT and ACLR groups, the relative wet weight of the TA was not significantly different ($P=0.799$). At four weeks post-surgery, the relative wet weights of the TA in the sham, ACLT, and ACLR groups were significantly higher than at one week post-surgery ($P<0.001$). In the ACLT group, the relative wet weight of the TA was significantly lower than in the control and sham groups ($P<0.001$). The relative wet weight of the TA in the ACLR group was also significantly lower than in the control group ($P=0.002$) but was significantly higher than in the ACLT group ($P=0.005$).

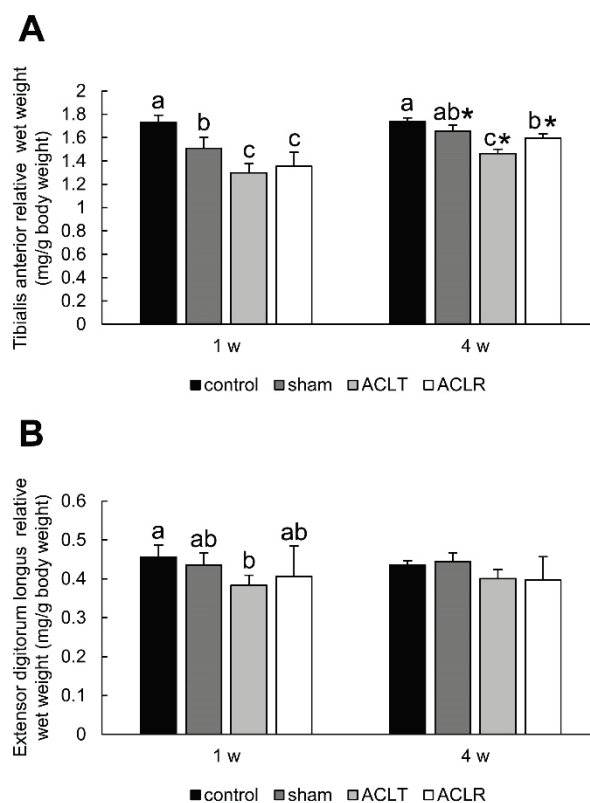


Fig. 5. Relative muscle wet weight of the plantar extensors. **(A)** Tibialis anterior and **(B)** extensor digitorum longus. Values are expressed as mean \pm standard deviation. Different letters indicate statistically significant differences between groups at the same time point, such that groups not sharing the same letter are significantly different from one another. *: significant difference compared with one week post-surgery. ACLT, anterior cruciate ligament transection; ACLR, anterior cruciate ligament reconstruction.

At one week post-surgery, compared with the control group, the relative wet weight of the EDL was significantly lower in the ACLT group ($P=0.008$) but not in the sham or ACLR groups (Fig. 5B, $P\geq 0.121$). There was no difference in the relative wet weights of the EDL among operated groups ($P\geq 0.179$). At four weeks post-surgery, the relative wet weights of the EDL were not significantly different among groups ($P\geq 0.252$).

Muscle fiber CSA

At one week post-surgery, each additional surgical step (i.e. arthrotomy, ACL transection, and ACL reconstruction) incrementally decreased the relative muscle fiber CSA of the RF (Fig. 6A-D, I). Compared

with the control group, the relative muscle fiber CSA of the RF was significantly lower in the sham, ACLT, and ACLR groups ($P\leq 0.031$). Among the sham, ACLT, and ACLR groups, there were no significant differences in the relative muscle fiber CSA of the RF ($P\geq 0.208$). At four weeks post-surgery, the relative muscle fiber CSA of the RF in the sham, ACLT, and ACLR groups were significantly higher than at one week post-surgery ($P\leq 0.040$, Fig. 6F-I). There were no significant differences in the relative muscle fiber CSA of the RF among groups at four weeks post-surgery ($P\geq 0.529$). Apparent pathological changes such as inflammation, fibrosis, or fatty tissue deposition were not observed in all groups at both time points.

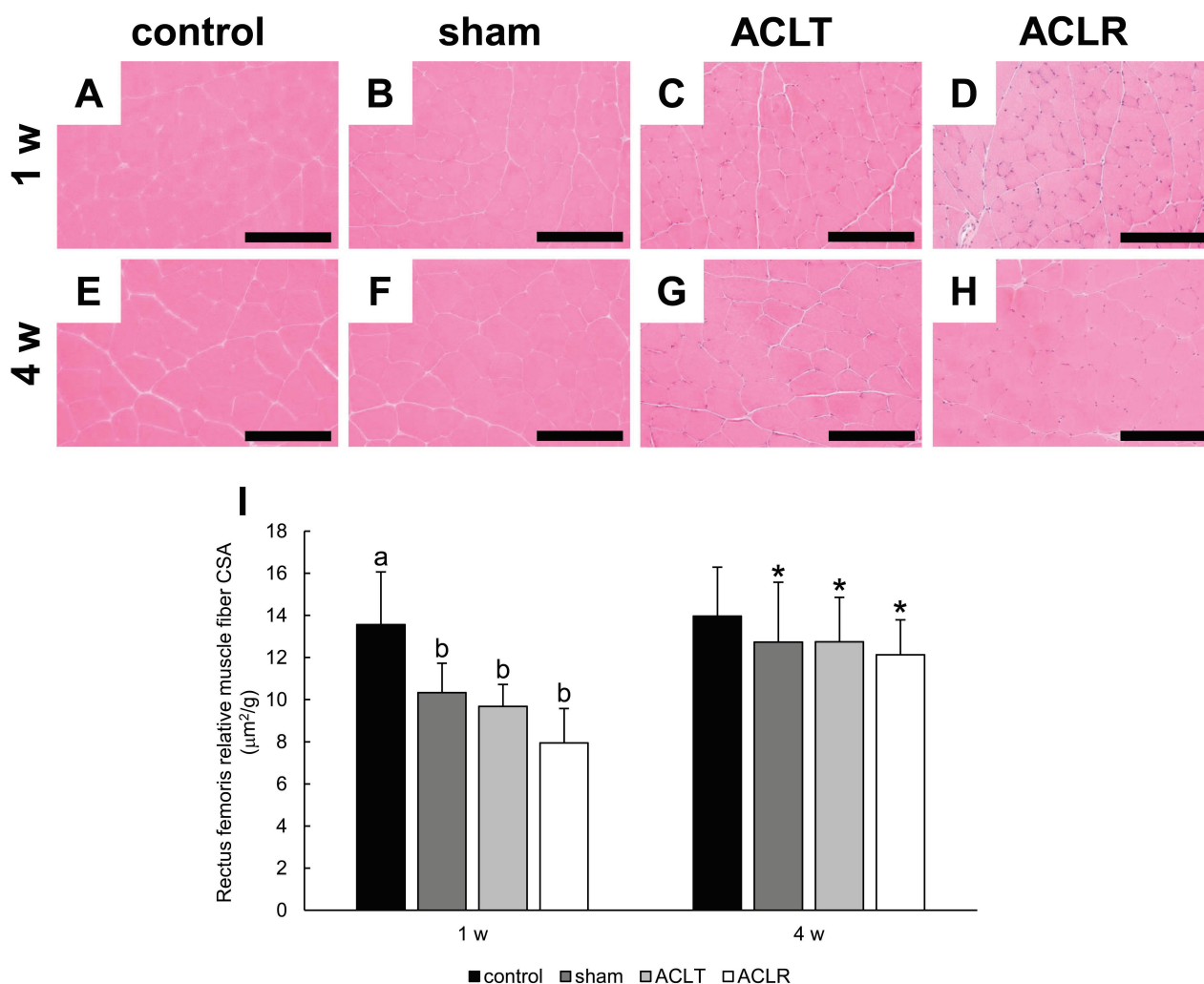


Fig. 6. Relative muscle fiber cross sectional area of the rectus femoris. (A-H) Histological changes in the rectus femoris examined by staining with hematoxylin and eosin. Representative images of the rectus femoris for the control (A and E), sham (B and F), ACLT (C and G), and ACLR (D and H) groups. A-D and E-H show sections at one and four weeks post-surgery, respectively. Scale bars: 200 µm. (I) Relative muscle fiber cross sectional area. Values are mean \pm standard deviation. Different letters indicate statistically significant differences between groups at the same time point, such that groups not sharing the same letter are significantly different from one another. *: significant difference between groups at one week post-surgery. CSA, cross sectional area; ACLT, anterior cruciate ligament transection; ACLR, anterior cruciate ligament reconstruction.

Correlation between muscle wet weight and muscle fiber CSA

In the RF, strong positive correlation was observed between relative muscle wet weight and relative muscle fiber CSA (Fig. 7).

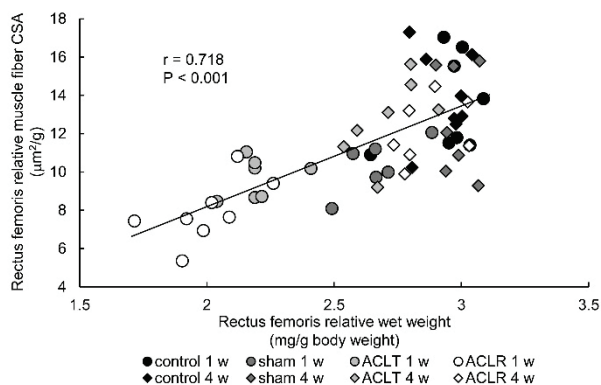


Fig. 7. Correlation between muscle wet weight and muscle fiber cross sectional area of the rectus femoris. CSA, cross sectional area; ACLT, anterior cruciate ligament transection; ACLR, anterior cruciate ligament reconstruction.

Differences in the percent of atrophy of muscles in the ACLR group

Overall, the percent of atrophy in the ACLR group tended to be higher in the knee extensor (RF) and plantar flexors (GC, SOL, and PL) than in the knee flexor (ST) and plantar extensors (TA and EDL) at one week post-surgery (Fig. 8). At one week post-surgery, the percent of atrophy in the GC was significantly higher than in the ST, TA, or EDL ($P \leq 0.004$). Percent of atrophy in the RF and PL was significantly higher than in the ST and EDL ($P \leq 0.021$). Moreover, the percent of atrophy in the SOL was significantly higher than in the EDL ($P = 0.002$). At four weeks post-surgery, the percent of atrophy was significantly lower than at one week post-surgery in all muscles ($P \leq 0.001$), except for the EDL ($P = 0.575$). Percent of atrophy in the knee extensor (RF) and flexor (ST) recovered nearly to 0%, while those in the plantar flexors (GC, SOL, and PL) and plantar extensors (TA and EDL) remained at approximately 10% at four weeks post-surgery. However, there were no significant differences in the percent of atrophy in muscles at four weeks post-surgery ($P \geq 0.132$).

Discussion

The first aim of this study was to study the short- and mid-term effects of ACL reconstructive surgery on

hindlimb muscle atrophy. At one week post-surgery, muscle atrophy, characterized by a significant decrease in relative muscle wet weight, was observed in all the examined muscles in the ACLT group. In the ACLR group, the atrophy of the RF, GC, SOL, and PL was more advanced compared with the ACLT group. At four weeks post-surgery, we observed a significant decrease in the relative muscle wet weight of all examined muscles, except for the EDL, in the ACLT group. However, the relative muscle wet weight of the RF, ST, and SOL as well as the relative muscle fiber CSA of the RF in the ACLR group recovered to non-significant levels in comparison with the control group. In particular, the relative muscle wet weight of the ST in the ACLR group was significantly higher than that of the ACLT group. In addition, although the relative muscle wet weight of the TA was significantly lower in both the ACLT and ACLR groups compared with the control and sham groups, the relative muscle wet weight was significantly higher in the ACLR group. These results indicate that ACL reconstructive surgery increases muscle atrophy in the first week post-surgery, while facilitating recovery in some muscles between the first and fourth week post-surgery.

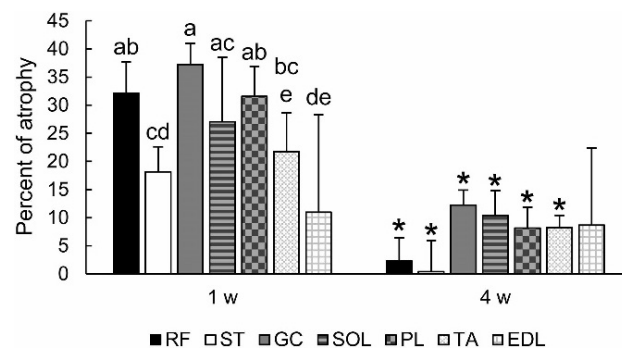


Fig. 8. Percent of atrophy of the muscles in the ACLR group. Values are expressed as mean \pm standard deviation. Different letters indicate statistically significant differences between groups at the same time point, such that groups not sharing the same letter are significantly different from one another. *: significant difference compared with one week post-surgery. RF, rectus femoris; ST, semitendinosus; GC, gastrocnemius; SOL, soleus; PL, plantaris; TA, tibialis anterior; EDL, extensor digitorum longus.

The mechanisms involved in muscle atrophy after ACL reconstructive surgery are not fully understood, but the contribution of disuse as well as arthrogenic muscle inhibition (AMI) has been suggested [2,23]. A previous study with rats reported that joint swelling at one week post-surgery was more intense in ACL reconstructed knees than in ACL transected knees

[20,24]. Moreover, they reported that knee joint motion and weight bearing time on the operated limb during treadmill walking transiently decreased at one week post-surgery in the ACL reconstructed rats compared with the ACL transected rats [20]. Thus, insult associated with reconstructive surgery (such as bone drilling and ligament reconstruction) would induce disuse (i.e. immobilization and unloading) of the operated limb by contributing to joint inflammation and nociception. This reconstructive surgery-induced disuse could explain, at least in part, the more severe muscle atrophy observed at one week after reconstructive surgery than the atrophy observed after ACL transection alone. The decrease in knee joint motion and weight bearing time after reconstructive surgery peaks at one week post-surgery and gradually recovers thereafter [20].

AMI is the inability to fully activate muscles after injury or surgery of the joint [25,26] and is frequently observed after ACL injury and reconstruction [2]. Joint laxity induced by ACL injury, as well as joint swelling and pain, are considered to contribute to AMI [25]. Using the index of voluntary quadriceps muscle activation ratio, studies have reported that re-stabilization of the knee joint by reconstructive surgery attenuates AMI after ACL injury [27-29]. Attenuation of AMI by ACL reconstruction may be able to explain the positive effects of reconstructive surgery on recovery from muscle atrophy detected between one and four weeks post-surgery.

The second aim of this study was to investigate the differences in the degree of atrophy after ACL reconstruction in the hindlimb muscles. It is well known that muscle atrophy after ACL injury and reconstructive surgery is greater in the quadriceps than in the hamstrings [9,30]. In our study, accordingly, the percent of atrophy at one week post-surgery was significantly increased in the RF compared to the ST. Although decreased muscle strength is observed also in the ankle planter flexors and extensors in patients with ACL reconstruction [12], whether muscle atrophy is also observed in the lower leg has not been well studied. We demonstrated that ACL reconstruction induces muscle atrophy not only in the quadriceps and hamstrings, but also in the lower leg muscles at one week post-surgery. However, at four weeks post-ACL reconstruction, the relative wet weight of both the RF and ST as well as relative muscle fiber CSA of the RF recovered to control levels, while some lower leg muscles (GC, PL, and TA) had a persistent significant reduction in relative wet

weight. The ankle and knee interact with each other through a kinetic chain [31,32], and poor self-reported ankle function in patients with ACL reconstruction is associated with poor self-reported knee function [33]. Thus, muscle strengthening interventions for the lower leg muscles, as well as for the quadriceps and hamstrings, may be required after ACL reconstruction.

Overall, the extent to which atrophy developed tended to be higher in the quadriceps (RF) and plantar flexors (GC, SOL, and PL) than in the hamstrings (ST) and plantar extensors (TA and EDL) at one week post-ACL reconstruction. As mentioned above, disuse caused by decreased weight bearing and joint motion could not be avoided after ACL reconstruction [20] and could contribute to the muscle atrophy observed early on after ACL reconstruction. In rodent hindlimb unloading models, the atrophy development rates in the quadriceps muscles and plantar flexors (GC, SOL, and PL) are higher than those in the plantar extensors (TA and EDL) [34-36]. In addition, muscle atrophy after human knee immobilization is greater in the quadriceps than in the hamstrings [37,38]. Thus, the differences in the degree of atrophy after ACL reconstruction among the hindlimb muscles may be explained, at least in part, by the differences in disuse responsiveness.

This study has some limitations. First, muscle fiber CSA was measured only in the RF, and only the relative muscle wet weight was used as an index for muscle atrophy in other muscles. Relative muscle wet weight may be affected not only by muscle fiber size, but also by muscle fiber number as well as water and connective tissue content. Measurement of muscle fiber size would provide more definitive conclusions. In the RF, apparent pathological changes such as inflammation, fibrosis, or fatty tissue deposition were not observed in all groups. We previously confirmed that these pathological changes were not apparent also in the ST and GC after ACL reconstruction in rats (unpublished data). Thus, we consider that water and connective tissue content in the muscles would not be significantly changed by ACL reconstruction. A previous study examined the changes in the muscle wet weight, muscle fiber CSA, and muscle fiber number after joint immobilization and reported that the muscle wet weight and muscle fiber CSA were similarly decreased, while muscle fiber number was not decreased [39]. Based on these results, authors concluded that quantification on the basis of muscle wet weight or muscle fiber CSA yield closely similar values, and therefore, both methods would serve

equally well for the determination of muscle atrophy [39]. In fact, strong positive correlation was detected between relative muscle wet weight and relative muscle fiber CSA of the RF in our study. Other study also reported parallel changes in muscle wet weight and muscle fiber size after denervation in the rat GC [40]. Therefore, muscle wet weight would reflect muscle fiber size also in other muscles, at least in part. Second, although most ACL reconstructive surgeries in human patients are performed arthroscopically, we chose an open approach for technical reasons. Because sham surgery (arthrotomy) alone induced a significant reduction of relative muscle wet weight in some muscles (RF, GC, PL, and TA) at one week post-surgery, muscle atrophy may have been overestimated. Third, we could not study the negative effects of graft harvesting from patellar or hamstring tendons, because we used a tail tendon autograft. In human patients, patellar and hamstring tendons are commonly used as graft materials. Thus, graft harvesting itself could be a cause of muscle weakness and may

induce muscle atrophy in human's cases [41-44]. Fourth, we used a small animal model, so its clinical relevance to the course of human patients may be limited.

In conclusion, we report that reconstructive surgery can intensify the development of muscle atrophy in the first week post-surgery, while facilitating recovery in some muscles between the first and fourth week post-surgery. ACL reconstruction induced muscle atrophy not only in the quadriceps and hamstrings, but also in the lower leg muscles, suggesting the need for muscle strengthening interventions for the lower leg muscles as well as for the quadriceps and hamstrings.

Conflict of Interest

There is no conflict of interest.

Acknowledgements

This study was supported by JSPS KAKENHI (grant numbers 18H06427 and 20K19400) and the Nakatomi Foundation.

References

1. Dai B, Herman D, Liu H, Garrett WE, Yu B. Prevention of ACL injury, part I: injury characteristics, risk factors, and loading mechanism. *Res Sports Med* 2012;20:180-197. <https://doi.org/10.1080/15438627.2012.680990>
2. Palmieri-Smith RM, Thomas AC, Wojtys EM. Maximizing quadriceps strength after ACL reconstruction. *Clin Sports Med* 2008;27:405-424. <https://doi.org/10.1016/j.csm.2008.02.001>
3. Kim HJ, Lee JH, Ahn SE, Park MJ, Lee DH. Influence of anterior cruciate ligament tear on thigh muscle strength and hamstring-to-quadriceps ratio: A meta-analysis. *PLoS One* 2016;11:e0146234. <https://doi.org/10.1371/journal.pone.0146234>
4. Yang JH, Eun SP, Park DH, Kwak HB, Chang E. The effects of anterior cruciate ligament reconstruction on individual quadriceps muscle thickness and circulating biomarkers. *Int J Environ Res Public Health* 2019;16:4895. <https://doi.org/10.3390/ijerph16244895>
5. Lee JH, Cheon S, Jun HP, Huang YL, Chang E. Bilateral comparisons of quadriceps thickness after anterior cruciate ligament reconstruction. *Medicina (Kaunas)* 2020;56:335. <https://doi.org/10.3390/medicina56070335>
6. Ageberg E, Thomee R, Neeter C, Silbernagel KG, Roos EM. Muscle strength and functional performance in patients with anterior cruciate ligament injury treated with training and surgical reconstruction or training only: A two to five-year followup. *Arthritis Rheum* 2008;59:1773-1779. <https://doi.org/10.1002/art.24066>
7. Pincivero DM, Heller BM, Hou SI. The effects of acl injury on quadriceps and hamstring torque, work and power. *J Sports Sci* 2002;20:689-696. <https://doi.org/10.1080/026404102320219392>
8. Tengman E, Brax Olofsson L, Stensdotter AK, Nilsson KG, Hager CK. Anterior cruciate ligament injury after more than 20 years. II. Concentric and eccentric knee muscle strength. *Scand J Med Sci Sports* 2014;24:e501-e509. <https://doi.org/10.1111/sms.12215>
9. Arangio GA, Chen C, Kalady M, Reed JF 3RD. Thigh muscle size and strength after anterior cruciate ligament reconstruction and rehabilitation. *J Orthop Sports Phys Ther* 1997;26:238-243. <https://doi.org/10.2519/jospt.1997.26.5.238>
10. Osteras H, Augestad LB, Tondel S. Isokinetic muscle strength after anterior cruciate ligament reconstruction. *Scand J Med Sci Sports* 1998;8:279-282. <https://doi.org/10.1111/j.1600-0838.1998.tb00483.x>

11. Keays SL, Bullock-Saxton J, Keays AC. Strength and function before and after anterior cruciate ligament reconstruction. *Clin Orthop Relat Res* 2000;(373):174-183. <https://doi.org/10.1097/00003086-200004000-00021>
12. Herlant M, Delahaye H, Voisin P, Bibre P, Adele MF. The effect of anterior cruciate ligament surgery on the ankle plantar flexors. *Isokinet Exerc Sci* 1992;2:140-144. <https://doi.org/10.3233/IES-1992-2307>
13. Wurtzel CN, Gumucio JP, Grekin JA, Khouri RK JR, Russell AJ, Bedi A, Mendias CL. Pharmacological inhibition of myostatin protects against skeletal muscle atrophy and weakness after anterior cruciate ligament tear. *J Orthop Res* 2017;35:2499-2505. <https://doi.org/10.1002/jor.23537>
14. Silva JMS, Alabarse PVG, Teixeira VON, Freitas EC, de Oliveira FH, Chakr R, Xavier RM. Muscle wasting in osteoarthritis model induced by anterior cruciate ligament transection. *PLoS One* 2018;13:e0196682. <https://doi.org/10.1371/journal.pone.0196682>
15. Anderson MJ, Diko S, Baehr LM, Baar K, Bodine SC, Christiansen BA. Contribution of mechanical unloading to trabecular bone loss following non-invasive knee injury in mice. *J Orthop Res* 2016;34:1680-1687. <https://doi.org/10.1002/jor.23178>
16. Cunha JE, Barbosa GM, Castro P, Luiz BLF, Silva ACA, Russo TL, Vasilceac FA, Cunha TM, Cunha FQ, Salvini TF. Knee osteoarthritis induces atrophy and neuromuscular junction remodeling in the quadriceps and tibialis anterior muscles of rats. *Sci Rep* 2019;9:6366. <https://doi.org/10.1038/s41598-019-42546-7>
17. Ohno M, Fujiya H, Goto K, Kurosaka M, Ogura Y, Yatabe K, Kudo T, Kobayashi H, Niki H, Musha H. Long term changes in muscles around the knee joint after ACL resection in rats: Comparisons of acl-resected, contralateral and normal limb. *J Sports Sci Med* 2017;16:429-437.
18. Gong D, Chu W, Jiang L, Geng C, Li J, Ishikawa N, Kajima K, Zhong L. Effect of fucoxanthin alone and in combination with d-glucosamine hydrochloride on carrageenan/kaolin-induced experimental arthritis in rats. *Phytother Res* 2014;28:1054-1063. <https://doi.org/10.1002/ptr.5093>
19. Ozawa J, Kurose T, Kawamata S, Yamaoka K. Morphological changes in hind limb muscles elicited by adjuvant-induced arthritis of the rat knee. *Scand J Med Sci Sports* 2010;20:e72-e79. <https://doi.org/10.1111/j.1600-0838.2009.00900.x>
20. Kaneguchi A, Ozawa J, Minamimoto K, Yamaoka K. A rat model of arthrofibrosis developed after anterior cruciate ligament reconstruction without rigid joint immobilization. *Connect Tissue Res* 2021;62:263-276. <https://doi.org/10.1080/03008207.2019.1693548>
21. Kaneguchi A, Ozawa J, Minamimoto K, Yamaoka K. Formation process of joint contracture after anterior cruciate ligament reconstruction in rats. *J Orthop Res* 2021;39:1082-1092. <https://doi.org/10.1002/jor.24800>
22. Nonaka K, Une S, Komatsu M, Yamaji R, Akiyama J. Heat stress prevents the decrease in succinate dehydrogenase activity in the extensor digitorum longus of streptozotocin-induced diabetic rats. *Physiol Res* 2018;67:117-126. <https://doi.org/10.33549/physiolres.933617>
23. Lepley LK, Davi SM, Burland JP, Lepley AS. Muscle atrophy after acl injury: Implications for clinical practice. *Sports Health* 2020;12:579-586. <https://doi.org/10.1177/1941738120944256>
24. Kaneguchi A, Umehara T, Yamaoka K, Ozawa J. Bilateral muscle atrophy after anterior cruciate ligament reconstruction in rats: Protective effects of anti-inflammatory drug celecoxib. *Knee* 2022;35:201-212. <https://doi.org/10.1016/j.knee.2022.03.011>
25. Rice DA, McNair PJ. Quadriceps arthrogenic muscle inhibition: Neural mechanisms and treatment perspectives. *Semin Arthritis Rheum* 2010;40:250-266. <https://doi.org/10.1016/j.semarthrit.2009.10.001>
26. Hopkins J, Ingersoll CD, Edwards J, Klootwyk TE. Cryotherapy and transcutaneous electric neuromuscular stimulation decrease arthrogenic muscle inhibition of the vastus medialis after knee joint effusion. *J Athl Train* 2002;37:25-31.
27. Lepley AS, Gribble PA, Thomas AC, Tevald MA, Sohn DH, Pietrosimone BG. Quadriceps neural alterations in anterior cruciate ligament reconstructed patients: A 6-month longitudinal investigation. *Scand J Med Sci Sports* 2015;25:828-839. <https://doi.org/10.1111/sms.12435>
28. Snyder-Mackler L, De Luca PF, Williams PR, Eastlack ME, Bartolozzi AR 3RD. Reflex inhibition of the quadriceps femoris muscle after injury or reconstruction of the anterior cruciate ligament. *J Bone Joint Surg Am* 1994;76:555-560. <https://doi.org/10.2106/00004623-199404000-00010>

29. Urbach D, Nebelung W, Becker R, Awiszus F. Effects of reconstruction of the anterior cruciate ligament on voluntary activation of quadriceps femoris a prospective twitch interpolation study. *J Bone Joint Surg Br* 2001;83:1104-1110. <https://doi.org/10.1302/0301-620X.83B8.11618>
30. Gerber C, Hoppeler H, Claassen H, Robotti G, Zehnder R, Jakob RP. The lower-extremity musculature in chronic symptomatic instability of the anterior cruciate ligament. *J Bone Joint Surg Am* 1985;67:1034-1043. <https://doi.org/10.2106/00004623-198567070-00007>
31. Theisen A, Day J. Chronic ankle instability leads to lower extremity kinematic changes during landing tasks: A systematic review. *Int J Exerc Sci* 2019;12:24-33.
32. Palmitier RA, An KN, Scott SG, Chao EY. Kinetic chain exercise in knee rehabilitation. *Sports Med* 1991;11:402-413. <https://doi.org/10.2165/00007256-199111060-00005>
33. Hoch JM, Baez SE, Hoch MC. Examination of ankle function in individuals with a history of acl reconstruction. *Phys Ther Sport* 2019;36:55-61. <https://doi.org/10.1016/j.pts.2019.01.002>
34. McMahon CD, Popovic L, Oldham JM, Jeanplong F, Smith HK, Kambadur R, Sharma M, Maxwell L, Bass JJ. Myostatin-deficient mice lose more skeletal muscle mass than wild-type controls during hindlimb suspension. *Am J Physiol Endocrinol Metab* 2003;285:E82-E87. <https://doi.org/10.1152/ajpendo.00275.2002>
35. Ito M, Kudo N, Miyake Y, Imai T, Unno T, Yamashita Y, Hirota Y, Ashida H, Osakabe N. Flavan 3-ol delays the progression of disuse atrophy induced by hindlimb suspension in mice. *Exp Gerontol* 2017;98:120-123. <https://doi.org/10.1016/j.exger.2017.07.010>
36. Fisher JS, Hasser EM, Brown M. Effects of ovariectomy and hindlimb unloading on skeletal muscle. *J Appl Physiol* (1985) 1998;85:1316-1321. <https://doi.org/10.1152/jappl.1998.85.4.1316>
37. Kilroe SP, Fulford J, Jackman SR, Van Loon LJC, Wall BT. Temporal muscle-specific disuse atrophy during one week of leg immobilization. *Med Sci Sports Exerc* 2020;52:944-954. <https://doi.org/10.1249/MSS.0000000000002200>
38. Hudelmaier M, Glaser C, Hausschild A, Burgkart R, Eckstein F. Effects of joint unloading and reloading on human cartilage morphology and function, muscle cross-sectional areas, and bone density - a quantitative case report. *J Musculoskelet Neuronal Interact* 2006;6:284-290.
39. Nicks DK, Beneke WM, Key RM, Timson BF. Muscle fibre size and number following immobilisation atrophy. *J Anat* 1989;163:1-5.
40. Jaeger MR, Braga-Silva J, Gehlen D, Pereira-Filho Gde A, Zettler CG, de Souza MA, Veas JR, Sebben A. End-to-end versus end-to-side motor and sensory neurotaphy in the repair of the acute muscle denervation. *Ann Plast Surg* 2011;67:391-396. <https://doi.org/10.1097/SAP.0b013e3182126816>
41. Huber R, Viocchi C, Bizzini M, Friesenbichler B, Dohm-Acker M, Rosenheck T, Harder L, Maffiuletti NA. Knee extensor and flexor strength before and after anterior cruciate ligament reconstruction in a large sample of patients: Influence of graft type. *Phys Sportsmed* 2019;47:85-90. <https://doi.org/10.1080/00913847.2018.1526627>
42. Petersen W, Taheri P, Forkel P, Zantop T. Return to play following ACL reconstruction: A systematic review about strength deficits. *Arch Orthop Trauma Surg* 2014;134:1417-1428. <https://doi.org/10.1007/s00402-014-1992-x>
43. Nomura Y, Kuramochi R, Fukubayashi T. Evaluation of hamstring muscle strength and morphology after anterior cruciate ligament reconstruction. *Scand J Med Sci Sports* 2015;25:301-307. <https://doi.org/10.1111/sms.12205>
44. Johnston PT, McClelland JA, Feller JA, Webster KE. Knee muscle strength after quadriceps tendon autograft anterior cruciate ligament reconstruction: Systematic review and meta-analysis. *Knee Surg Sports Traumatol Arthrosc* 2020;29:2918-2933. <https://doi.org/10.1007/s00167-020-06311-y>