

Rare Causes of Respiratory Insufficiency in Newborns

Jana BRUCKNEROVÁ¹, Jozef BABALA³, Eduard UJHÁZY⁴, Mojmír MACH⁴, Ivo JURÁNEK⁴, Ingrid BRUCKNEROVÁ²

¹Faculty of Medicine, Comenius University in Bratislava, Slovak Republic, ²Neonatal Department of Intensive Medicine, Comenius University in Bratislava and National Institute of Children's Diseases, Slovak Republic, ³Department of Paediatric Surgery Comenius University in Bratislava and National Institute of Children's Diseases, Slovak Republic, ⁴Centre of Experimental Medicine, Slovak Academy of Sciences, Slovak Republic

Received October 6, 2020

Accepted November 5, 2020

Summary

Congenital lung masses (CLM) the rare group of causes of acute respiratory insufficiency (RI) in newborns include congenital airway pulmonary malformation (CAPM), congenital overinflation, bronchopulmonary sequestration, and bronchial atresia. The presenting group consists of 13 newborns who were admitted to the Neonatal Department of Intensive Medicine (NDIM) during January 1st 2015-December 31st 2019 (8 males, 5 females, 2 premature/11 term newborns, spontaneous delivery: 2, caesarean section: 11) with positive prenatal diagnosis of CAPM in all cases. In 2 cases prenatal intervention was performed (drainage of the amniotic fluid, attempt of thoracentesis). Signs of acute RI immediately after delivery were seen in 5 newborns. Postnatal echocardiographic investigation confirmed the presence of increased pulmonary pressure in 8 patients, no patient had congenital heart abnormality. A thorax x-ray was positive also in asymptomatic patients. Computed tomography in patients brought detailed information about the position, size and character of CAPM. Six patients underwent surgery. In 15.4 % right lungs were affected by cystic malformation and in 23 % left lungs were affected. A final diagnosis of CAPM was confirmed in 5 patients using histopathologic examination. Multidisciplinary cooperation during prenatal as well as postnatal period is necessary.

Key words

Congenital lung masses • Congenital pulmonary airway malformation • Newborn

Corresponding author

I. Brucknerová, Neonatal Department of Intensive Medicine Comenius University in Bratislava, National Institute of Children's Diseases, Limbová 1, 833 40 Bratislava, Slovak Republic. E-mail: ingrid.brucknerova@fmed.uniba.sk

Introduction

The development of the respiratory system is intricately linked to the development of the digestive system. The respiratory system begins to form in the 4th week of gestation from the ventral wall of the foregut intestine. From the epithelium the laryngotracheal groove is formed, which is connected to the foregut. It gradually grows in a caudal direction and by means of a tracheoesophageal septum, the anterior intestine is divided into oesophagus and ventrally placed trachea with bronchopulmonary buds. As a result of this, the origin of the breathing tube is separated from the digestive tract. The epithelium of the airways and the respiratory part of the lungs arises from the entoderm. The mesenchyme form ligaments (and connective tissue proper in mucosa layer), smooth muscle, and blood vessels of the respiratory system (Kapeller and Pospíšilová 1991, Sadler, 2011, Mráz *et al.* 2015).

Several phases in the process of lung differentiation are distinguished (Sadler 2011, Bouchard 2018). For the 1st embryonic stage (3rd - 5th week of embryonic age) there is the typical formation of laryngotracheal diverticulum with subsequent formation of primary, secondary and tertiary bronchi and trachea. During the 2nd pseudoglandular stage (weeks 6 - 16) further branching of the terminal respiratory tree up to the terminal bronchioles is present. Respiratory alveoli and bronchioles are not yet formed. From prenatal weeks 5 to 17, the lungs look like a tubuloacinar gland with epithelial tubes that branch into the surrounding

mesenchyme (Berrocal *et al.* 2004). This period is characterized by the formation of an immature neural network. Type 2 pneumocytes appear (Bouchard, 2018). During the 3rd canalicular phase (weeks 16-26) each terminal bronchiole is divided into 2 or more respiratory bronchioles, and these are divided into 3 to 6 alveolar ducts. Respiratory bronchioles are more vascularized. Differentiation of the cuboidal epithelium into type I and type II cells, as well as the surfactant synthesis appears. The 4th phase is the saccular stage (26th week until delivery) presented with formation of widened airspaces and termed saccules that are formed on peripheral airways, to which capillaries are attached. Thinning of the connective tissue between the airspaces is detectable. Primitive alveoli are covered with type 1 and type 2 pneumocytes, maturation of the surfactant system is presented. After 28 weeks of gestation, significant reduction in mesenchymal tissue occurs, the distal saccules are divided, and their walls become thinner (Berrocal *et al.* 2004). The surfactant is detectable in amniotic fluid. An extracellular matrix is formed (Bouchard, 2018). The 5th phase is called alveolar stage (8th month of development to childhood: 7th - 10th year) with formation of mature alveoli and tight alveolar membrane. Alveoli are divided until there are 300 million of them. They reach this number in the 8th year of life (Berrocal *et al.* 2004).

Congenital airway pulmonary malformations, formerly referred to as congenital cystic adenomatoid pulmonary malformation (CCAPM), are rare developmental abnormalities of the lower respiratory tract. The incidence of congenital pulmonary malformations is in the range of 30-42 cases per 100,000 population, the incidence of CCAPM of 1: 10,000 - 1: 35,000 births (Costa *et al.* 2008).

Many studies have examined the effect of keratinocyte growth factor, fibroblast growth factor-10, glial cell-derived neurotrophic factor, and failure of "communication" between endoderm and mesoderm tissue, and an imbalance between cell proliferation and apoptosis during organogenesis (Berrocal *et al.* 2004). Swarr and his co-authors suggest three aetiologies (Swarr *et al.* 2018). Results from experimental work on animals can also help us to better understand the changes that occur during lung development (Piešová and Mach 2020).

CCAPM was first described in 1949 (Ch'In and Tang 1949). Stocker divided them into three main types (Stocker *et al.* 1977). According to Adzick, two types of lung lesions are distinguished (Adzick *et al.* 1985). The new classification specifies the place of origin of

congenital airway malformations (Andrade *et al.* 2011). Currently, a classification of 5 forms is used (Oerman *et al.* 2019, Egloff and Bulas 2020).

Cystic findings in the lungs are usually detected at 20th week of gestation (Witlox 2019). The fastest change in the size of cystically altered lungs is achieved between the 20th and 26th gestational week. The largest dimension is usually confirmed in the 25th gestational week. After this period, either a slow growth phase occurs or even a spontaneous regression may occur. Macrocystic lesions have been found to grow more slowly compared to microcystic or solid lesions. The probability of developing hydrops is not different (Morini *et al.* 2018). A necessary part of the examination of the newborn is detection of the presence of associated congenital anomalies (Harmath *et al.* 2007, Cavoretto *et al.* 2008).

The finding in the lungs affects the signs of respiratory insufficiency (RI) immediately after delivery. Majority of cases are presented after neonatal period. Postnatal examination methods include native chest X-rays and computed tomography (CT). High-resolution CT makes it possible to differentiate microcystic from macrocystic lesions. CT with the administration of a contrast substance is used for exclusion of pulmonary sequestration. Magnetic resonance imaging (MRI) clarifies the more detailed characteristics of the lesion. Sonography (brain, urinary system, heart) for associated congenital anomalies and for measurement of a pressure in lungs, genetic testing is recommended. New diagnostic options include ultrasound examination of the lungs.

Childcare begins at the stage of prenatal development (corticoids, surgery: decompression, resection, thoracocentesis, aspiration, continual drainage, fetal tracheobronchoscopy) (Witlox *et al.* 2011, Chon *et al.* 2018). Surgical resection prevents infections and malignant transformation. Childbirth management as well as care in the immediate postpartum period always requires multidisciplinary cooperation in a highly specialized medical facility.

The aim of presented work is to analyze prenatal and postnatal course, diagnostic and therapeutical attitudes.

Methods

Retrospective analysis of newborns admitted to the NDIM during January 1, 2015 - December 31, 2019 with prenatal suspicion of congenital airway pulmonary malformation. The group of patients consisted of 13 newborns.

Table 1a. Characteristic of the patients (1-7).

Patient	Prenatal admin. of corticoids	Age and clinical condition at admission to NDIM	AF	Characteristic of the patient			
				Delivery	BW (g)	BL (cm)	AS
1	without	- 1 hour - on spontaneous ventilation, FiO ₂ 0.21	clear	38+4 g. w., elective section from CLM	3146	49	9/9/1 0
2	without	- 6 days - on spontaneous ventilation, FiO ₂ 0.21	clear	38 g. w., section from the orthopaedic indication of the mother (condition after pelvic fracture) and CLM	3440	50	8/9
3	complete	- 2 hours - before transport: orotracheal intubation, ventilatory support, FiO ₂ 0.70 - after admission: ventilatory support	clear	38 g. w., section from pelvic position and congenital lung malformation	2830	49	
4	complete	- 7 days - on spontaneous ventilation, FiO ₂ 0.21	clear	38 g. w., planned section	3200	49	10/1 0
5	complete	- 3rd day (hydrops, syndrome of blue face and upper vena cava; petechiae; surfactant) - after admission: inotropic support (Dobutamine), ventilatory support, FiO ₂ 0.80	clear	31+6 g. w., section due to preeclampsia	2430	40	3/5/5
6	complete	- 4 days - on spontaneous ventilation, FiO ₂ 0.21	clear	38+3 g. w. spontaneous vacuum extraction	3080	50	
7	33 g. w. Betamethasone	- 3 days - on spontaneous ventilation, FiO ₂ 0.21	clear	36+5 g. w. spontaneous	2800	43	10/1 0

g. w. – gestational week, AF – amniotic fluid, AS – Apgar score, FiO₂ – oxygen fraction, g. – gram, cm – centimeter, CLM – congenital lung malformation, admin. – administration, BW – birth weight, BL – birth length, NDIM – Neonatal Department of Intensive Medicine

Results

The presenting group of patients with positive prenatal diagnosis of CAPM (fetal sonography, MRI)

consists of 13 newborns (8 males/5 females, 2 premature newborns/11 term newborns, spontaneous delivery: 2, caesarean section: 11) (Table 1a, 1b). In 2 cases prenatal intervention was performed (drainage of the amniotic

Table 1b. Characteristic of the patients (8-13).

Patient	Prenatal admin. of corticoids	Age and clinical condition at admission to NDIM	AF	Characteristic of the patient			
				Delivery	BW (g)	BL (cm)	AS
8	complete	after delivery: condition after chest drainage, O ₂ , intubation, ventilation, surfactant time of admission: 1 hour, high-frequency ventilation with FiO ₂ 0.99; continuous chest drainage; chest X-ray: left pneumothorax with transfer of mediastinum to right hemithorax; intensive ventilation mode; inotropic support (Adrenaline); transfusion of erythrocyte mass	clear	38 g. w., planned section due to macrocystic form	3500	49	8/7/6
9	without	- 1 hour - short time supportive ventilation, spontaneous ventilation, FiO ₂ 0.21	clear	38 g. w., planned section /CLM	3575	52	9/9
10	without	- 7 days - on spontaneous ventilation, FiO ₂ 0.21	clear	38 g. w., planned section/CLM	3010	48	9/10
11	without	- 3 hours - on spontaneous ventilation, FiO ₂ 0.21	clear	39 g. w., planned section/CLM	3180	48	10/10
12	complete + Betamethason e	- 1 hour - on spontaneous ventilation, FiO ₂ 0.21	clear	37 g. w., planned section /CLM	2800	48	10/10
13	without	- 1 hour - on spontaneous ventilation, FiO ₂ 0.21	clear	38+6 g. w., section	3014	50	10/10

g. w. – gestational week, AF – amniotic fluid, AS – Apgar score, FiO₂ – oxygen fraction, g. – gram, cm – centimetre, CLM – congenital lung malformation, admin. – administration, BW – birth weight, BL – birth length, NDIM – Neonatal Department of Intensive Medicine

fluid, attempt of thoracentesis). Signs of acute RI immediately after delivery in 5 newborns. Postnatal echocardiography confirmed the presence of increased pulmonary pressure in 8 patients, no patient had congenital heart abnormality. A thorax x-ray with the confirmation of the presence of congenital lung masses was positive not only in symptomatic but also in asymptomatic patients (Fig. 2, 3, 5, 6, 7a, 8a, 9a). CT in patients brought detailed information about the character

of CAPM (Fig. 1, 4, 7b, 8b, 9b). Six patients underwent surgery. In 15.4 % right lungs were affected by cystic malformation (1 patient: complete lobectomy of the right lower lung lobe, 1 patient: complete lobectomy of the right upper lung lobe). In 23 % left lungs were affected (2 patients: non-anatomical resection of the left upper lung lobe, 1 patient: complete lobectomy of the left lower lung lobe). The final surgical procedure was contraindicated due to haemodynamic instability during

operation in one patient, only therapeutic drainage of the pleural cavity was performed (Table 2a, 2b). No patient had associated malformations. A final diagnosis of

CCAPM was confirmed in 5 patients using histopathologic evaluation.

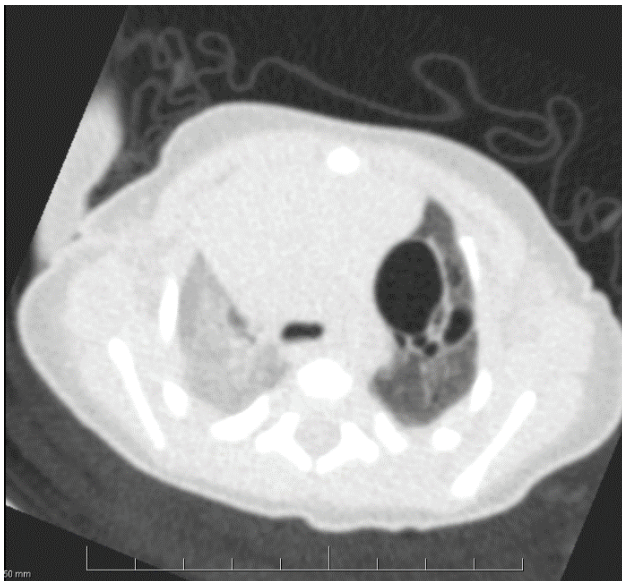

Fig. 1. Patient 2. Computed tomography/angiography. Bilaterally in the range of the lower and middle lobes, on the right and in the upper reduced transparency of the parenchyma. On the left in the range of the upper lobe present emphysematous bulges of various sizes, the largest up to a diameter of 20 mm, the others smaller.

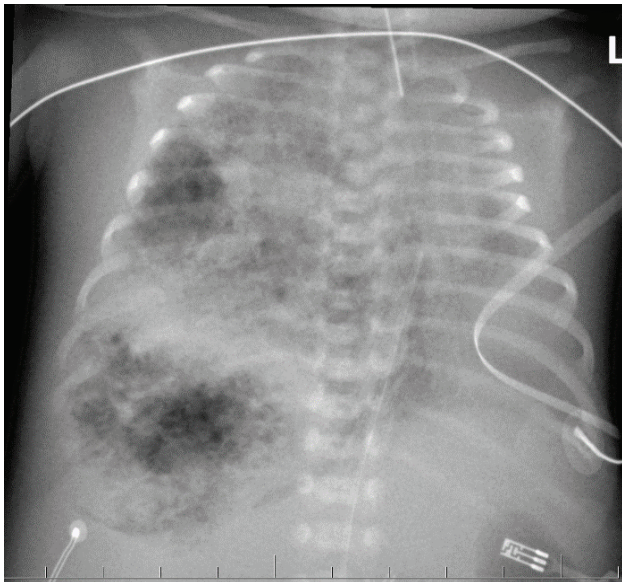


Fig. 3. Patient 5. Native X-ray of the thorax (anterior-posterior view). Both wings without a normal drawing (a markedly spotted, nodular pattern). Right lungs are significantly larger than the left, which are hypoplastic. Mediastinal organs are moved to the left, the border of the heart is out of focus. Various alternating areas of shading and brightening are located in the lungs.

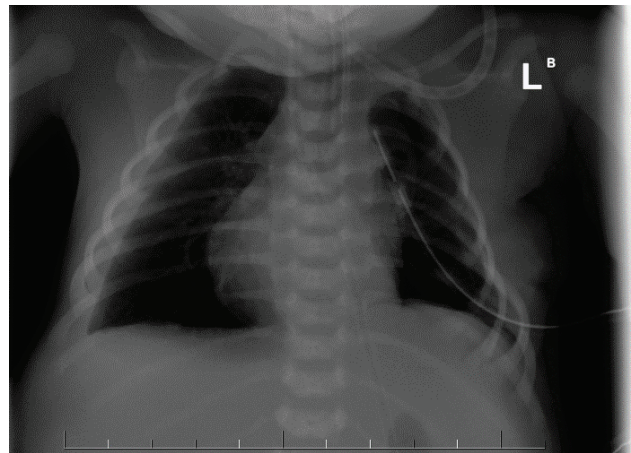


Fig. 2. Patient 3. Native X-ray of the thorax (anterior-posterior view). Reduced respiration area of both wings. Left altered structure and architecture of the lungs, alternating areas of increased and decreased airiness, emphysematous areas – the largest of them in the range of upper and middle lung left field (50x25 mm), smaller emphysematous areas in the area of lower lung field basal and medial. Also present, inhomogeneous, irregular areas of reduced airiness. Pathologically altered left lung with pressure manifestations on the organs of the mediastinum, heart, with their movement to the right and right substernal herniation of the left lung. On the right, the parenchyma is reduced, the hypoplastic whole chest is preserved.

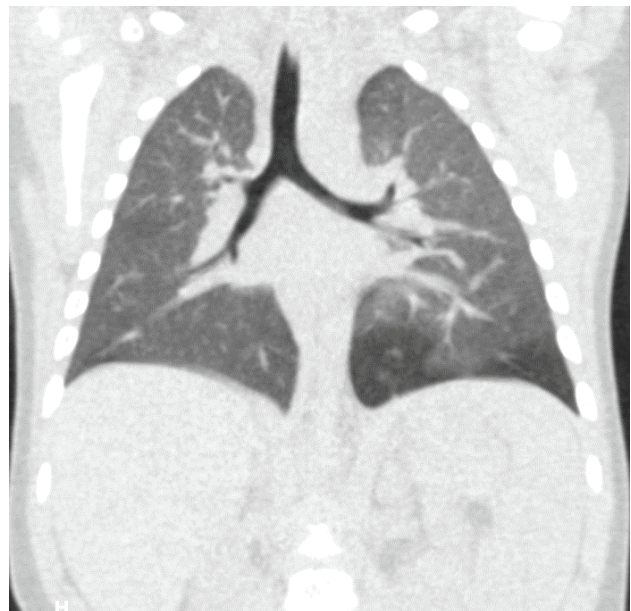

Fig. 4. Patient 6. Computed tomography/angiography. On the left in the lower lung lobe in the segments S7, S8, S9, S10 parenchyma of increased transparency with present microcysts with a diameter of up to max 3.2 mm, post-contrast without saturation, without the supply artery, is presented.

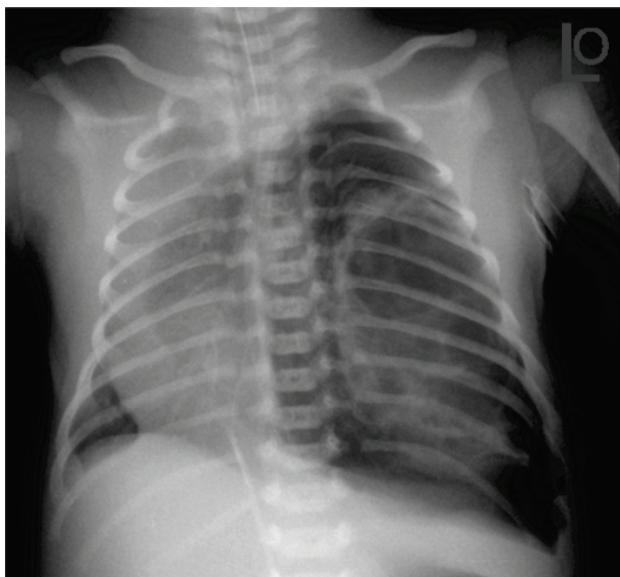


Fig. 5. Patient 8. Native X-ray of the thorax (anterior-posterior view). Increasing the airiness of the left hemithorax in the upper and middle lung field based on macrocystic dysplasia on the left. Mediastinum is dislocated with the shadow of the heart to the right based on macrocystic dysplasia on the left and hypoplasia of the lungs on the right. On the left side an increase in airiness of lung parenchyma without bronchovascular drawing due to the pneumothorax. Hypoplasia of the right wing, moving the mediastinum to the right.

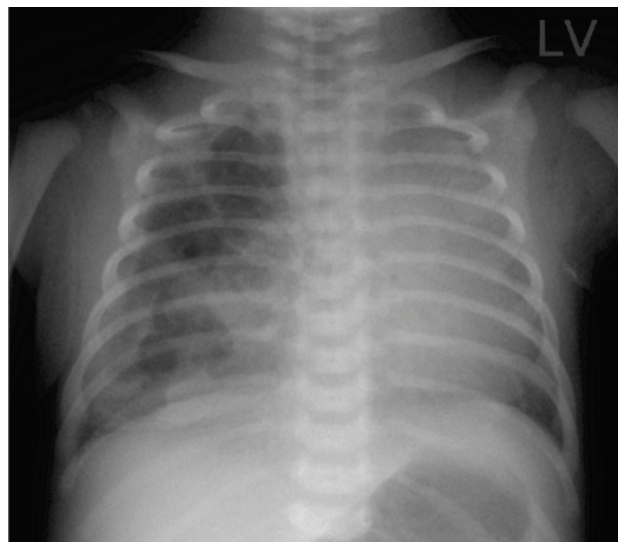


Fig. 6. Patient 9. Native X-ray of the thorax (anterior-posterior view). Inhomogeneous areas of reduced and increased airiness of right lung parenchyma in the sense of congenital cystic malformation of the lungs (cysts with a diameter of 10-28 mm). The left lung parenchyma is covered by shadow of the heart and mediastinum and basal lung parenchyma differentiable. Shadow of the heart and mediastinum with a shift to the left.

Discussion

Most patients with congenital pulmonary malformations (CPM) are asymptomatic in the neonatal period. These are about $\frac{3}{4}$ patients with a prenatally confirmed diagnosis of CAPM (Swarr *et al.* 2018). In our group of patients 4 newborns were admitted by the 1st hour of life on spontaneous ventilation, 1 patient by the 3rd hour of life also on spontaneous ventilation, and 5 newborns were admitted after 4 days of life on spontaneous breathing. Three patients were immediately after delivery intubated and put on ventilatory support.

Making differential diagnosis of CPM we excluded diaphragmatic hernia, bronchopulmonary sequester, pulmonary hypoplasia, tracheal atresia, bronchogenic cyst or bronchial stenosis or congenital high airway obstruction syndrome (Bulas and Egloff 2019, D'Eufemia *et al.* 2016).

Cavoretto *et al.* 2008 described 170 cases with the CCAPM. In 88 cases the lesion was leftsided, rightsided in 82 newborns. In our group of patients, the prenatal diagnosis of lung pathology was established in 100 %. Postnatally we confirmed the prevalence in the left lungs (38 %), in 4 case in right lungs (30 %), in 2 cases bilateral and in 2 cases the x-ray of the thorax was negative.

The therapeutic approach to patients in the previous period was not uniform. The diagnosis and treatment on our group of patients were proceeded according to the proposed algorithms according to Annunziata *et al.* 2019 and according to the summary presented in *UpToDate* 2020 (Egloff and Bulas 2020). Six patients from group underwent surgery. In 15.4 % right lungs were affected by cystic malformation (1 patient: complete lobectomy of the right lower lung lobe, 1 patient: complete lobectomy of the right upper lung lobe). In 23 % left lungs were affected (2 patients: non-anatomical resection of the left upper lung lobe, 1 patient: complete lobectomy of the left lower lung lobe). The final surgical procedure was contraindicated due to haemodynamic instability during operation in one patient (patient No 5), only therapeutic drainage of the pleural cavity was performed. In patient No 2, clinical status during first six days of life was optimal. This child did not have signs of respiratory insufficiency, but extensive findings in the lungs on CT-angiography indicated required surgery on 11th day of life. In this case optimal maturity together with physiological postnatal adaptation did not prevent the newborn surgery of the lungs.

The five patients (patient No 1, 9, 11, 12, 13) did not undergo surgery during the neonatal age. Their clinical condition was adequate and acute surgery was not required. Patient 1 (The control prenatal

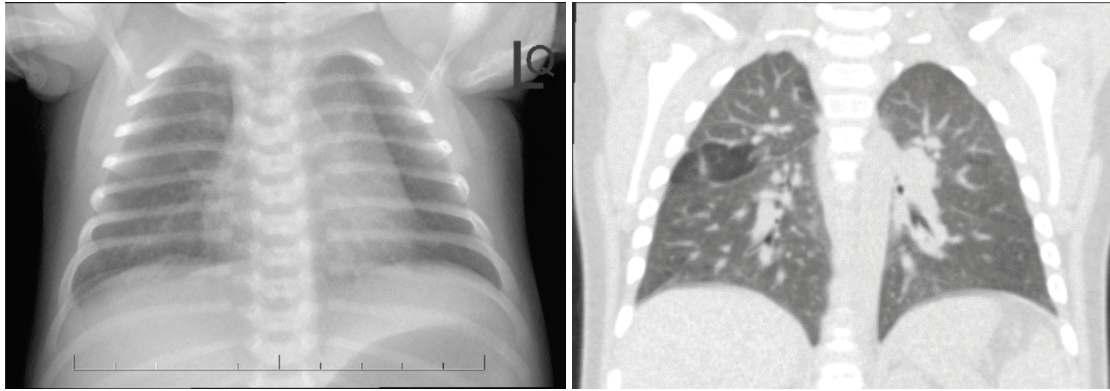


Fig. 7. a) Patient 11. Native X-ray of the thorax (anterior-posterior view). Without unambiguous cystic clarifications, only discreetly indicated small clarifications of the diameter up to 5-6 mm, at the interface of the upper and middle lung field is visible. Mediastinum is extended to the left (thymus), without displacement. **b)** Patient 11. Computed tomography/angiography. Two areas of slightly increased airiness and at the interface of segments S3/6 (27x26x15mm) and S4/8 (25x22x15 mm) with small cysts 2-6 mm in diameter are visible.

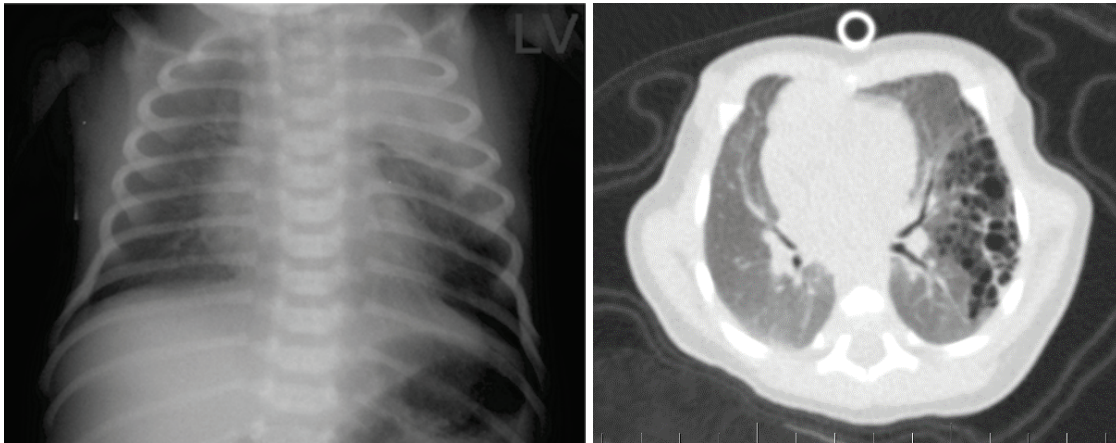


Fig. 8 a) Patient 12. Native X-ray of the thorax (anterior-posterior view). Homogeneous shading of the character of the consolidation of the upper lobe of the left hemithorax, the area of the lower lobe with increased airiness in the area of the external angle. **b)** Patient 12. Computed tomography/angiography. The aeration of atelectasis in the upper left lobe. The extent of involvement of the lung parenchyma in terms of emphysematous bullae was slightly highlighted in lobes S1, 2, 3 and 6.

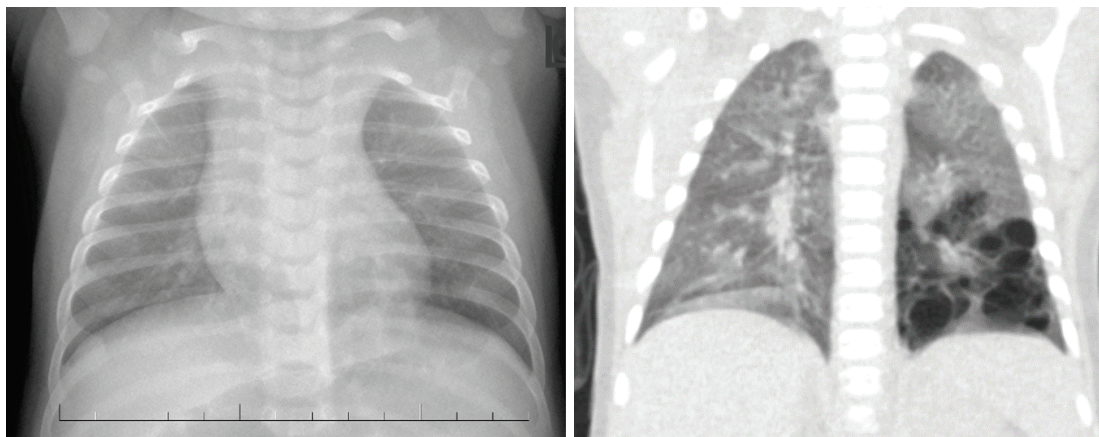


Fig. 9. a) Patient 13. Native X-ray of the thorax (anterior-posterior view). Pulmonary parenchyma without focal changes. On both sides in the lower lung fields bilateral basal increase in airiness. Left basal in the lower lobe discrete, not completely sharply demarcated clearing summing with a normal lung parenchyma (30x30 mm). **b)** Patient 13. Computed tomography (native). In the left lung wing, in the lower lobe the architecture of the lung parenchyma is disturbed. In the segment S6, 8, 9, 10 multiple superimposed oval formations, cysts, with air content with diameter individually from 2mm to a maximum of 11-12mm, replace the normal lung parenchyma (total size: 45x24x45 mm). Other lung parenchyma with appropriate density and structure.

Table 2a. Overview of surgical findings in a group of patients.

n.	surgical approach	Overview of surgical findings in a group of patients					
		surgery	right lungs			left lungs	
			upper lobe	middle lobe	lower lobe	upper lobe	lower lobe
2	left posterolateral thoracotomy in the 4 th intercostal space	non-anatomical resection of the left upper lobe of the lung				-apical cystic changes -largest cyst about 2 cm in diameter	macrosc. intact
3	left posterolateral thoracotomy in the 4 th intercostal space	lobectomy of the left lower lobe of the lung				macrosc. intact	cystically altered by numerous cysts
4	right posterolateral thoracotomy in the 4 th intercostal space	lobectomy of the right lower lobe of the lung	macro sc. intact	macro sc. intact	-numerous cystic changes -adhesions to the upper and middle lung lobe		
5	–	two thoracocentetic drains introduced under X-ray control: 1. drain - air with serosang. effusion 2. drain - sang. effusion. - continuous resuscitation - surgical intervention contraindicated					

n. – number, macrosc. – macroscopically, pathol. – pathological, serosang. – sanguine, cm – centimeter

examination superseded the regression of the pathological finding in the lungs) was spontaneously ventilating, without the need for oxygen therapy, with good respiratory mechanics, hemodynamically stable. The initial chest X-ray found a micro-multicystic formation in the middle and lower lung field on the left, without pneumothorax or fluidothorax. Neither the surgeon nor the pulmonologist indicated any intervention. CT was planned at 5 months of age. Patient 9 was hemodynamically stable, on spontaneous ventilation with a slight tendency to tachypnea, but did not require oxygen treatment at admission. Due to the

retention of carbon dioxide, respiratory support with Vapotherm for one day was started. On the second day of life she was eupnoic, with adequate ventilation-oxygenation parameters. The thorax X-ray showed cystic adenomatoid lung malformation. Due to optimal clinical condition conservative treatment and CT examination of the lungs at the age of 3 months was recommended. Patient 11 was a 3-hour newborn with prenatally diagnosed congenital cystic lung malformation. Local clarification of the pulmonary parenchyma apically to the right of a size 20x19 mm was seen on thorax X-ray. At the 4-day control, there were only discreet clarifications,

Table 2b. Overview of surgical findings in a group of patients.

Overview of surgical findings in a group of patients								
n.	surgical approach	surgery	right lungs			left lungs		
			upper lobe	middle lobe	lower lobe	upper lobe	lower lobe	
8	left thoracotomy in the 4 th intercostal space	conservative non-anatomical resection of the left upper lung lobe					- a cystically malformed upper lobe filled with fluid and air is expelled from the surgical wound under pressure - it occupies most of the chest cavity, the other parenchyma is suppressed - from the cranial part of the upper lobe about 35 – 40 % is healthy in appearance	macrosc. intact
10	right thoracotomy in the 4 th intercostal space	lobectomy of the right upper lung lobe	- a large cyst pushing into the surgical field, filling and causing hemodynamic instability ... opening and decompression were done	without macrosc. pathol. signs	without macrosc. pathol. signs			

n. – number, macrosc. – macroscopically, pathol. – pathological

without unambiguous cystic formations. Due to the stabilized clinical condition a surgical intervention was not recommended. CT examination was planned at 6 months of age. Patient 12 was hemodynamically and respiratory stable at admission. On thorax X-ray cystic formation with atelectatic component was shown in the upper lobe of the left pulmonary lobe. For mild dyspnea and minor desaturations, he required respiratory support for a total of one day, without the need for oxygen therapy. On the second day of life a CT angiography of the lungs confirmed the presence of congenital lung malformation. The patient was stable, and the surgeon recommended a conservative procedure with the implementation of a control CT examination of the lungs for a month. Patient 13 upon admission was

cardiopulmonary stabilized, on spontaneous ventilation. The initial X-ray showed a picture of wet lungs, without signs of parenchymal pathology, without pneumothorax and fluidothorax. For desaturation to 80 %, presence of opening respiratory phenomena and mild dyspnea, supportive treatment with Vapotherm was indicated for a total of 9 hours. In the further course of hospitalization, the patient was already eupneic, with good oxygenation-ventilation parameters. The surgeon recommended only observation and care as in a physiological newborn, rehospitalization at our clinic at the age of 2 months for the purpose of CT examination was recommended.

Gradual improvement of prenatal care, as well as new therapeutic options have significantly affected the

perinatal survival of patients with pulmonary lesions. Currently, the results describing the management in the neonatal period encounter the problem of small numbers. Care for a patient with a pulmonary lesion is multidisciplinary, has to be in a highly specialized medical facility and needs structure of standardized care (Morini *et al.* 2018, Witlox 2019).

In all patients from our group the clinical status of the patient was very important and had an influence on decision of the therapeutic plan. Even achievement of optimal level of maturity and mastering postnatal adaptation does not preclude surgery. The surgeon must always consider all possible risks arising from a finding in the pulmonary parenchyma. We believe that the presented results, as well as the findings on thorax x-rays and CT angiography from our workplace, will supplement the information on the clinical condition of newborns with prenatally diagnosed congenital

pulmonary malformations and contribute to expanding knowledge and refining algorithms for caring for this risk group of newborns.

Conflict of Interest

There is no conflict of interest.

Acknowledgements

The study was partly supported by the Slovak Grant Agency VEGA (grant No. 2/0166/20 and No. 2/0154/20).

Abbreviations

CAPM – congenital airway pulmonary malformation, CCAPM – congenital cystic adenomatoid malformation, CPM – congenital pulmonary malformations, CT – computed tomography, MRI – magnetic resonance imaging, RI – respiratory insufficiency.

References

- ADZICK NS, HARRISON MR, GLICK PL, GOLBUS MS, ANDERSON RL, MAHONY BS, CALLEN PW, HIRSCH JH, LUTHY DA, FILLY RA, DELORIMIER AA: Fetal cystic adenomatoid malformation: prenatal diagnosis and natural history. *J Pediatr Surg* 20: 483-488, 1985. [https://doi.org/10.1016/S0022-3468\(85\)80470-X](https://doi.org/10.1016/S0022-3468(85)80470-X)
- ANDRADE CF, FERREIRA HP, FISCHER GB: Congenital lung malformations. *J Bras Pneumol* 37: 259-271, 2011. <https://doi.org/10.1590/S1806-37132011000200017>
- ANNUNZIATA F, BUSH A, BORGIA F, RAIMONDI F, MONTELLA S, POETA M, BORRELLI M, SANTAMARIA F: Congenital lung malformations: unresolved issues and unanswered questions. *Front Pediatr* 7: 239, 2019. <https://doi.org/10.3389/fped.2019.00239>
- BERROCAL T, MADRID C, NOVO S, GUTIÉRREZ J, ARJONILLA A, GÓMEZ-LEÓNE N: Congenital anomalies of the tracheobronchial tree, lung, and mediastinum: embryology, radiology, and pathology. *Radiographics* 24: e17, 2004. <https://doi.org/10.1148/rg.e17>
- BOUCHARD S: To cut or not to cut? what is the role of surgery in the management of pediatric lung lesions [online]. 2018, <https://cts-sct.ca/wp-content/uploads/2018/04/Bouchard-S.pdf>
- BULAS DI, EGLOFF A: Prenatal diagnosis and management of bronchopulmonary sequestration. UpToDate. 2019. <https://www.uptodate.com/contents/prenatal-diagnosis-and-management-of-bronchopulmonary-sequestration>.
- CAVORETTO P, MOLINA F, POGGI S, DAVENPORT M, NICOLAIDES KH: Prenatal diagnosis and outcome of echogenic fetal lung lesions. *Ultrasound Obstet Gynecol* 32: 769, 2008. <https://doi.org/10.1002/uog.6218>
- CH'IN KY, TANG MY: Congenital adenomatoid malformation of one lobe of a lung with general anasarca. *Arch Pathol* 48: 221-229, 1949.
- CHON AH, STEIN JE, GERSTENFELD T, WANG L, VAZQUEZ WD, CHMAIT RH: The use of fetal bronchoscopy in the diagnosis and management of a suspected obstructive lung mass. *AJP Rep* 8: e195-e200, 2018. <https://doi.org/10.1055/s-0038-1673378>
- COSTA AS JR, PERFEITO JA, FORTE V: Surgical treatment of 60 patients with pulmonary malformations: what have we learned? *J Bras Pneumol* 34: 661-666, 2008. <https://doi.org/10.1590/S1806-37132008000900005>
- D'EUFEMIA MD, CIANCI S, DI MEGLIO F, DI MEGLIO L, DI MEGLIO L, VITALE SG, LAGANÀ AS, CHIOFATO B, RAPISARDA AMCH, PADULA F, LA ROSA V, COCO C, VASCONE C: Congenital high airway obstruction syndrome (CHAOS): discussing the role and limits of prenatal diagnosis starting from a single-center case series. *J Prenat Med* 10: 4-7, 2016. <https://doi.org/10.11138/jpm/2016.10.1.004>

- EGLOFF A, BULAS DI: Congenital pulmonary airway malformation: Prenatal diagnosis and management. UpToDate. March 4 2020. <https://www.uptodate.com/contents/congenital-pulmonary-airway-malformation-prenatal-diagnosis-and-management>
- HARMATH Á, CSABA E, HAUZMAN J, HAJDÚ B, PAPP Z: Congenital lung malformations in the second trimester: prenatal ultrasound diagnosis and pathologic findings. *J Clinical Ultrasound* 35: 250-255, 2007. <https://doi.org/10.1002/jcu.20341>
- KAPPELLER K, POSPÍŠILOVÁ V: Embryology of the human body. Osveta, K. Kappeler, V. Pospíšilová (Eds.) 1991, p 341.
- MORINI F, ZANI A, CONFORTI A, VAN HEURN E, EATON S, PURI P, RINTALA R, LUKAC M, KUEBLER JF, FRIEDMACHER F, WIJNEN R, TOVAR JA, PIERRO A, BAGOLAN P: Current Management of Congenital Pulmonary Airway Malformations: A "European Pediatric Surgeons' Association" Survey. *Eur J Pediatr Surg* 28: e1-e1, 2018. <https://doi.org/10.1055/s-0038-1660778>
- MRÁZ P, BINOVSÝ A, HOLOMÁŇOVÁ A, OSVALDOVÁ M, RUTTKAY-NEDECKÁ E: Anatomy of the human body I. SAP, P. Mráz (Ed.), Bratislava, 2015, p527.
- OERMANN CHM, GARCIA-PRATS JA, REDDING G, HOPPIN AG: Congenital pulmonary airway (cystic adenomatoid) malformation. UpToDate. 2019. <https://www.uptodate.com/contents/congenital-pulmonary-airway-cystic-adenomatoid-malformation?search=cystic%20adeno>
- PIEŠOVÁ M, MACH M: Impact of perinatal hypoxia on the developing brain. *Physiol Res* 69: 199-213, 2020. <https://doi.org/10.33549/physiolres.934198>
- SADLER TW: Langman's medical embryology. GRADA, 10th edition. 2011. p414.
- STOCKER JT, MADEWELL JE, DRAKE RM: Congenital cystic adenomatoid malformation of the lung. Classification and morphologic spectrum. *Hum Pathol* 8: 155-171, 1977. [https://doi.org/10.1016/S0046-8177\(77\)80078-6](https://doi.org/10.1016/S0046-8177(77)80078-6)
- SWARR DT, PERANTEAU WH, POGORILER J, FRANK JB, ADZICK SN, HEDRICK HL, MORLEY M, ZHOU S, MORRISEY EE: Novel molecular and phenotypic insights into congenital lung malformations. *Am J Respir Crit Care Med* 197: 1328-1339, 2018. <https://doi.org/10.1164/rccm.201706-1243OC>
- WITLOX RS, LOPRIORE E, OEPKES D: Prenatal interventions for fetal lung lesions. *Prenat Diagn* 31: 628-636, 2011. <https://doi.org/10.1002/pd.2778>
- WITLOX RSGM: Short- and long-term outcome after fetal therapy for thoracic abnormalities. Leiden University, the Netherlands 2019. p168.
-